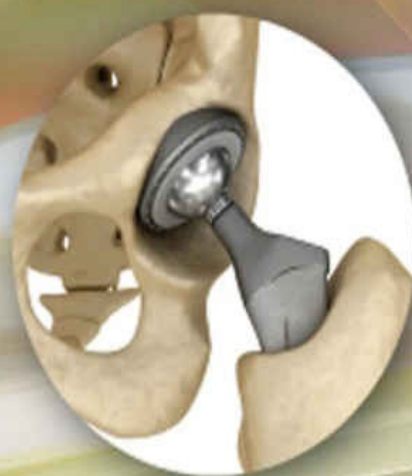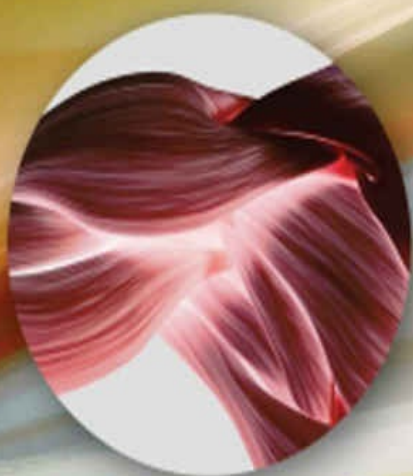
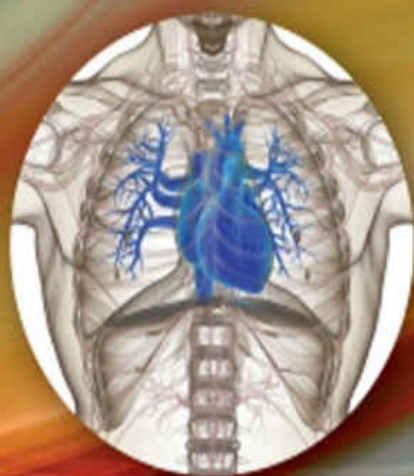


DAVI-ELLEN CHABNER

Medical Terminology

A SHORT COURSE

8TH EDITION



ELSEVIER



EVOLVE STUDY RESOURCES
FREE WITH TEXTBOOK PURCHASE
EVOLVE.ELSEVIER.COM

Medical Terminology

A SHORT COURSE

8TH EDITION

DAVI-ELLEN CHABNER

ELSEVIER

Table of Contents

Cover image

Title Page

Copyright

Dedication

Preface to the 8th Edition

Also Available

Acknowledgments

Reviewers

Chapter 1 Basic Word Structure

Word Analysis

Combining Forms, Suffixes, and Prefixes

In Person: Living With Type 1 Diabetes

Exercises and Answers

Pronunciation of Terms

Practical Applications

Picture Show

Review

Terminology Checkup

Chapter 2 Organization of the Body

Introduction

Body Systems

Body Cavities

Divisions of the Back

Planes of the Body

Terminology

Combining Forms

In Person: CT and MRI

Exercises and Answers

Pronunciation of Terms
Practical Applications
Picture Show
Review
Terminology Checkup

Chapter 3 Suffixes

Introduction
Combining Forms
Suffixes and Terminology
In Person: Gallbladder Stones
Exercises and Answers
Pronunciation of Terms
Practical Applications
Picture Show
Review
Terminology Checkup

Chapter 4 Prefixes

Introduction
Combining Forms and Suffixes
Prefixes and Terminology
In Person: Total Knee Replacement (TKR)
Exercises and Answers
Pronunciation of Terms
Practical Applications
Picture Show
Review
Terminology Checkup

Chapter 5 Medical Specialists and Case Reports

Introduction
Medical Specialists
Combining Forms and Vocabulary
Case Reports
In Person: Living With Crohn's
Exercises and Answers
Pronunciation of Terms
Practical Applications
Review
Terminology Checkup

Appendix 1 Body Systems

- Cardiovascular System
- Digestive System
- Endocrine System
- Female Reproductive System
- Lymphatic System
- Male Reproductive System
- Musculoskeletal System
- Nervous System
- Respiratory System
- Skin and Sense Organs
- Urinary System

Appendix 2 Diagnostic Tests and Procedures

Appendix 3 Abbreviations, Acronyms, Symbols, and Eponyms

- Abbreviations
- Acronyms*
- Symbols*
- Eponyms

Appendix 4 Quick Drug Reference

Appendix 5 Allied Health Careers

Glossary 1 Mini-Dictionary

Glossary 2 Word Parts

- Section I: Medical Terminology → English
- Section II: English → Medical Terminology

Glossary 3 English → Spanish Terms*

Index

Copyright

ELSEVIER

3251 Riverport Lane
St. Louis, Missouri 63043

MEDICAL TERMINOLOGY: A SHORT COURSE, EIGHTH EDITION
ISBN: 978-0-323-44492-7

Copyright © 2018 by Elsevier, Inc. All rights reserved.
Previous editions copyrighted © 2015, 2012, 2009, 2005, 2003, 1999, 1991.

No part of this publication may be reproduced or transmitted in any form or by any means, electronic or mechanical, including photocopying, recording, or any information storage and retrieval system, without permission in writing from the publisher. Details on how to seek permission, further information about the Publisher's permissions policies and our arrangements with organizations such as the Copyright Clearance Center and the Copyright Licensing Agency, can be found at our website: www.elsevier.com/permissions.

This book and the individual contributions contained in it are protected under copyright by the Publisher (other than as may be noted herein).

Notices

Knowledge and best practice in this field are constantly changing. Practitioners and researchers must always rely on their own experience and knowledge in evaluating and using any information, methods, compounds or experiments described herein. Because of rapid advances in the medical sciences, in particular, independent verification of diagnoses and drug dosages should be made. To the fullest extent of the law, no responsibility is assumed by Elsevier, authors, editors or contributors for any injury and/or damage to persons or property as a matter of products liability, negligence or otherwise, or from any use or operation of any methods, products, instructions, or ideas contained in the material herein.

ISBN: 978-0-323-44492-7

Senior Content Strategist: Linda Woodard
Senior Content Development Specialist: Diane Chatman
Senior Content Development Manager: Luke Held
Publishing Services Manager: Julie Eddy
Project Manager: Mike Sheets
Design Direction: Brian Salisbury

Printed in Canada

Last digit is the print number: 9 8 7 6 5 4 3 2 1



Dedication

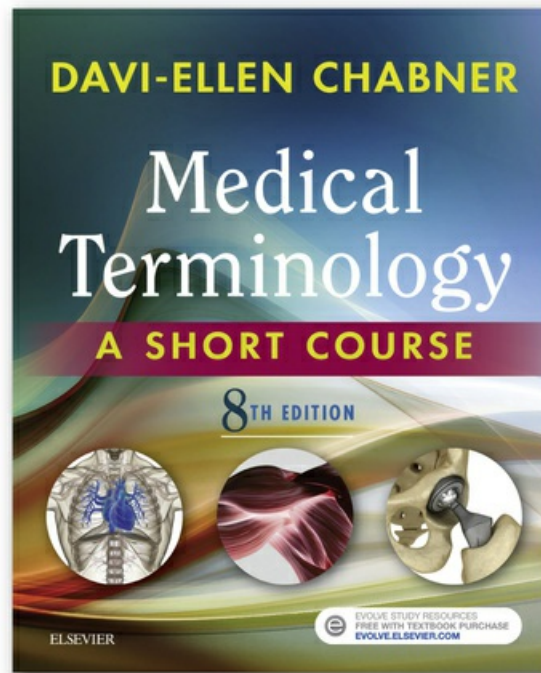


For my wonderful grandchildren whose laughter and love surround me, especially on Nantucket.

Thank you, Ben, Louisa, Bebe, Gus, Solomon, and Amari!

Preface to the 8th Edition

I wrote the first edition of *Medical Terminology: A Short Course* almost 30 years ago with the hope that it would fill a specific niche in the education of allied health professionals. My goal was to present a comprehensive introduction and overview of medical terminology in a straightforward and easy manner for students who had no previous background in biology or medicine.



It is gratifying to know that this book is now widely used in colleges, career schools, universities, hospitals, and other medical settings in the United States and abroad, where allied health workers use medical language and interpret it for patients and their families. There is no doubt that the method used in *Medical Terminology: A Short Course* takes potentially complicated subject matter and makes it manageable and understandable. In this eighth edition, the text has been updated and carefully reviewed for clarity, simplicity, and practicality, but its essential elements remain. Here are its important features:

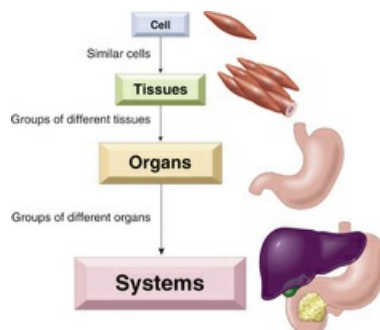
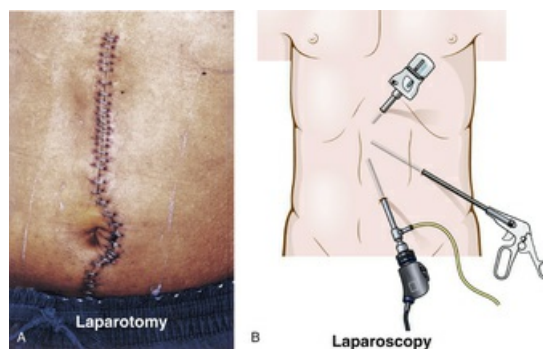
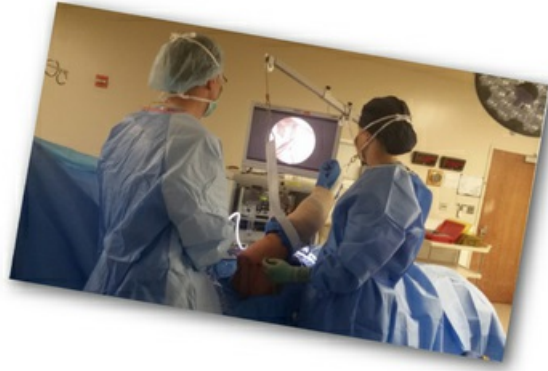Workbook-Text Format.

In this book, you learn by doing. On nearly every page you are writing and interacting with medical terminology. You complete exercises (and check your answers), label diagrams, test your understanding with review sheets, and practice pronunciation. The best path to success is to write terms and their meanings as you test yourself. I really believe this method of learning will work for you!

Easy to Read and Understand.

Explanations of terms are worded simply and clearly, and repetition reinforces learning throughout the text. Answers to questions are located easily so that you can check and correct your responses while gaining additional explanation of terminology.

Dynamic Illustrations and Photographs.



Medical terms come alive with images on nearly every page! Learning is reinforced by seeing parts of the body, diseases, conditions and real medical procedures. At the end of each chapter, “Picture Shows” highlight key images and allow you to apply your knowledge of terminology.

Introduction to Body Systems.

The Body Systems Resource, beginning on [page 215](#), begins with the following five sections:

- **Anatomy**—shows full-color images of each body system, labeled for easy reference with combining forms for each body part.
- **Terminology**—repeats each combining form and gives a medical term illustrating the use of the combining form. Definitions are in the *Mini-Dictionary* at the end of the book.
- **Pathology**—presents explanations of disease conditions related to each body system.
- **Diagnostic and Treatment Procedures**—explains and defines common examples for each body system.
- **Matching Exercises**—tests your understanding of the material, with answers included.

Practical Applications.

Throughout the text, and on the **Student Evolve website**, you will find exciting images, medical case reports, and vignettes and exercises called Picture Shows that illustrate terminology in the context of stories about patients and procedures.

CASE 7 *Endocrinology*

A 36-year-old woman known to have **type 1 diabetes mellitus** was brought to the emergency department after being found collapsed at home. She had experienced 3 days of extreme weakness, **polyuria**, and **polydipsia**. It was discovered that a few days before her admission, she had discontinued use of her external **insulin pump** (see Figure 5-12).




FIGURE 5-12 External insulin pump. (Provided by Medtronic.)

insulin pump _____

polydipsia _____

polyuria _____

type 1 diabetes mellitus _____

In Person.

These compelling first-person narratives describe procedures and conditions from a uniquely personal perspective. After reading each story, medical terms take on new meaning as you experience intimately how it feels to be in a patient's "shoes," living through a diagnosis, disease, and treatment.

PICTURE SHOW

Answer the questions that follow each image. Correct answers are given on page 168.

A



(Image from iStock.com / Johnny Greig.)

1. The images show examples of devices attached to a residual lower limb ("stump") after amputation. These devices are called:

- polyneuropathies
- subtotal anomalies
- prostheses
- metastases

IN PERSON: LIVING WITH TYPE 1 DIABETES

The following first-person narrative describes the reality of living with a particular medical condition—type 1 diabetes in a teenager. In each of the subsequent chapters, you'll find other first-person accounts of diseases and procedures that will make your study of medical terminology more relevant to real-life situations.

Jake Sheldon has type 1 diabetes, which was diagnosed when he was 8 years old. The following narrative was written by his mother, Rathellen Sheldon, based on his teenage years.




On school days, I wake Jake up at 6:30 AM. He tests his blood sugar by pricking his finger until it bleeds, and then sticks a test strip into the drop of blood. Then he inserts the strip into a small hand-held glucometer and waits 3 to 5 seconds for a reading of his blood sugar. If this is 120 mg/dL or higher, he gives himself insulin 10 to 15 minutes before breakfast. He has an insulin pump, so he types in the amount of carbohydrates he will eat, plus his current blood sugar reading. The pump calculates how much insulin he needs to cover the carbs and any extra insulin he may need to bring down a high blood sugar. If Jake's blood sugar is less than 120 mg/dL when he wakes up, he will wait until he takes his first bite of food to give himself his insulin to avoid hypoglycemia.

Throughout the school day, if his blood sugar is high or low, he visits the nurse. If it's high, he gives himself an insulin bolus, or correction, by pump. If his blood sugar is positive for ketones, he is sent home from school. If his blood sugar is low

Terminology Checkup.

This interactive and enhanced feature recaps and reinforces key concepts and easily confused terms in each chapter.

 **TERMINOLOGY CHECKUP**

Before you leave this chapter, here are important concepts that you should thoroughly understand. In your own words, write the answers on the lines provided. Confirm your answers on the next page. Check the box next to each item when you know you've "got" it!

1. What is the difference between **endocrine glands** and **exocrine glands**. Give an example of each.

2. What is the difference between a **diagnosis** and a **prognosis**?

3. What is the difference between a **carcinoma** and a **sarcoma**? Give an example of each.

Reference Guide for Medical and Hospital Work.

This book is also a useful resource. Diagnostic Tests and Procedures (radiological, nuclear medicine, and clinical and laboratory tests) are found in [Appendix 2](#). Abbreviations, symbols, acronyms, and eponyms are located in [Appendix 3](#). NEW to this edition is a Quick Drug Reference located in [Appendix 4](#). The *Mini-Dictionary* helps you study each chapter and also will be a reference for you in the workplace. Each definition has been crafted carefully to explain terms using plain, nontechnical language.

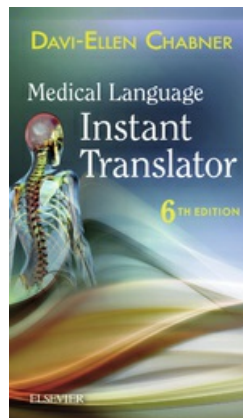
Also Available

Student Evolve Website (access included with text purchase)

evolve

The Evolve website included with this new edition contains additional information, images, and video clips to test and expand your understanding. Chapter by chapter, you will find case studies, games, and activities, as well as a wealth of images to illustrate medical terminology. In the Audio Program section you can hear the proper pronunciation with each medical term in the book. Visit <http://evolve.elsevier.com/Chabner/medtermshort> to access your resources.

Medical Language Instant Translator (for sale separately)



My Medical Language Instant Translator is a uniquely useful resource for all allied health professionals and students of medical terminology. It is a pocket-sized medical terminology reference with convenient information at your fingertips!

Medical Terminology: A Short Course is exactly what you need to begin your medical career—whether in an office, hospital, or other medical setting. Use this handy book in a classroom with an instructor, or study it on your own. The combination of visually reinforced hands-on learning plus easily accessible reference material will mean success for you in your allied health career.

My more comprehensive workbook-text, *The Language of Medicine, 11th edition*, may be of interest to you as you continue your study of medical terminology. It can also serve as a valuable reference in the workplace.

I still experience the thrill and joy of teaching new students. I love being in the classroom and feel privileged to continue to write this text. I am available for help at any time. Please communicate your comments, questions, and suggestions to me at daviellenchabner@gmail.com. For technical assistance, please contact technical.support@elsevier.com.

Most of all, I hope this book brings to you excitement and enthusiasm for the medical language. It can ignite your imagination for new challenges and make your job more interesting. Work hard and have fun learning medical terminology!



Davi-Ellen Chabner

Acknowledgments

It is impossible to publish another edition of this book without the assistance and hard work of my extraordinary and exceptional editor, Maureen Pfeifer. On virtually every aspect of this edition, she has listened, advised, and delivered the best possible solutions ... with great intelligence, thoughtfulness, and careful attention to detail. We are a TEAM! Thank you, Maureen, for not only being a superb cross-country working partner, but my loyal friend, as well.

I appreciate the support and advocacy of Linda Woodard, Senior Content Strategist, Elsevier, Inc. She is always responsive to my concerns and willing to find solutions! Luke Held, Content Development Manager, continues to be a reliable resource and support for my books. Thanks, Luke, for being "in my corner." I am also grateful to Diane Chatman, Senior Content Development Specialist, for her coordination and oversight of this edition.

Mike Sheets, Project Manager, facilitated the complex production of this edition. I appreciate his hard work and flexibility in all aspects of the project. Thank you, Brian Salisbury, Designer, for creating the layout and design for this edition. I appreciate your patience and cooperation.

Suzanne BeDell, Managing Director, Education, Reference and Continuity, took the time to become personally connected to me and my teaching. I appreciate her continuing involvement, insight, and vision for my work. Thanks also to other members of the Elsevier team: Michelle Harness, Director, Book Production; Julie Eddy, Publishing Services Manager, Book Production; and Kevin Herrin, Team Manager, Multimedia. A special thank you to the sales team for your continued support and promotion of my projects.

Jim Perkins, assistant professor of medical illustration, Rochester Institute of Technology, was responsible for the excellent, first-rate individual drawings that illustrate this edition. As always, he has done an outstanding job.

I am particularly grateful to the In Person contributors who shared their personal medical stories. Thanks so much to Ruthellen Sheldon, Cathy Ward, Elizabeth Chabner Thompson, Sidra DeKoven Ezrahi, and Nancy J. Brandwein.

I appreciate the valuable suggestions of the instructors who reviewed *Medical Terminology: A Short Course* for this new edition. They are listed with their credentials on page xv. Their helpful comments are incorporated in this text.

My class at Partners in Career and Workforce Development (PCWD), Partners Healthcare System has been an important resource for this edition. My students' enthusiasm and questions to inspire me. I appreciate them, and their commitment to beginning a career in healthcare.

Teachers and students worldwide continue to contact me with insights and questions. Thank you to: Mary Beth Dylewski, Tamara Bohnett, Gloria Lay, Isabel Isalguez, Mary Streight, N. Lee Price, Hani Elgendi, Robin Maddalena, Mohammed Allibaih, Kaylar Griffin, Joyce Y. Nakano, Judith Lytle, Julie Cox, Wendy Peters, Teresa Mills, Dianna Kerr, Jared Rodriguez, Ernest Nino-Murcia, Rori Alexander and Susan Grady.

My husband, Bruce A. Chabner, MD, and my daughter, Elizabeth Chabner Thompson, MD, MPH, are always available for expert medical advice and consultation. I am grateful for their availability no matter what else is going on in their busy lives and work. Special thanks for Dan L. Longo, MD, whom I continue to rely on for his infallible medical knowledge as well as his unwavering friendship.

Bruce and I think continuously of our friends and family who are in the throes of medical issues ... real time. Their positive attitudes and courage give deeper meaning to our daily lives.

Davi-Ellen Chabner

Reviewers

Darci Brown PAC, MSPAS

Director of Clinical Education, Assistant Professor
Misericordia University Physician Assistant Program
Misericordia University
Dallas, Pennsylvania

Bruce A. Chabner MD

Director of Clinical Research
Massachusetts General Hospital Cancer Center
Professor of Medicine
Harvard Medical School
Boston, Massachusetts

Elizabeth Chabner Thompson MD, MPH

CEO/Founder BFFL Co
Scarsdale, New York

Rosalie Griffith MSN, RN, MAEd

Nursing Success Coordinator
Chesapeake College
Wye Mills, Maryland

Dan L. Longo MD

Deputy Editor
New England Journal of Medicine
Professor of Medicine
Harvard Medical School
Boston, Massachusetts

Emily L. McClung RN, MSN

Instructor
Hiram College
Hiram, Ohio

Deborah Harris O'Brien PhD, Licensed Psychologist

Associate Professor
Trinity Washington University
Washington, DC

Sean F. Peck MEd, EMT-P

Associate Faculty-Allied Health
Arizona Western College
Yuma, Arizona

Constance Phillips MA, MPH

Director, Biomedical Laboratory and Clinical Sciences
Boston University School of Medicine/Metropolitan College
Boston, Massachusetts

Dona Powell BS in Education

Instructor

Technical Education Center, Osceola
Kissimmee, Florida

Mary M. Prorok RN, MSN

Instructor
South Hills School of Business & Technology
Altoona, Pennsylvania

Julie M. Weldon RN, MSN

Education Coordinator and Adjunct Faculty
Mercy Medical Center—Des Moines
Mercy College of Health Sciences
Des Moines, Iowa



CHAPTER 1

Basic Word Structure

CHAPTER SECTIONS

Word Analysis	2
Combining Forms, Suffixes, and Prefixes	5
In Person: Living With Type 1 Diabetes	21
Exercises and Answers	23
Pronunciation of Terms	33
Practical Applications	37
Picture Show	39
Review	42
Terminology CheckUp	45

CHAPTER OBJECTIVES

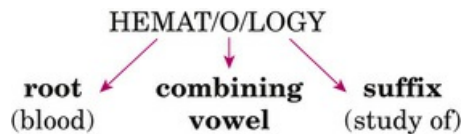- To divide medical terms into component parts
- To analyze, pronounce, and spell medical terms using common combining forms, suffixes, and prefixes

Word Analysis

If you work in a medical setting, you use medical words every day. In addition, you hear medical terms spoken in your doctor's office, read about health issues, and make daily decisions about your own health care and the health care of your family. Terms such as arthritis, electrocardiogram, hepatitis, and anemia describe conditions and tests that are familiar. Other medical words are more complicated, but as you work in this book, you will begin to understand them even if you have never studied biology or science.

Medical words are like individual jigsaw puzzles. Once you divide the terms into their component parts and learn the meaning of the individual parts, you can use that knowledge to understand many other new terms.

For example, the term HEMATOLOGY is divided into three parts:

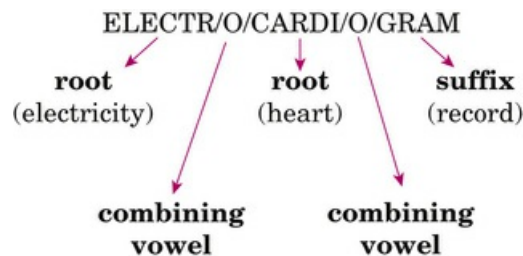


When you analyze a medical term, begin at the *end* of the word. The ending is called a **suffix**. All medical terms contain suffixes. The suffix in HEMATOLOGY is -LOGY, which means study of. Next, look at the beginning of the term. HEMAT is the word **root**. The root gives the essential meaning of the term. The root HEMAT means blood.

The third part of this term, which is the letter O, has no meaning of its own but is an important connector between the root (HEMAT) and the suffix (-LOGY). It is called a **combining vowel**. The letter O is the combining vowel usually found in medical terms.

Now put together the meanings of the suffix and the root: HEMATOLOGY means study of blood.

Another familiar medical term is ELECTROCARDIOGRAM. You probably know this term, often abbreviated as ECG (or sometimes EKG). This is how you divide it into its parts:



Start with the **suffix** at the end of the term. The suffix -GRAM means a record.

Now look at the beginning of the term. ELECTR is a word **root**, and it means electricity.

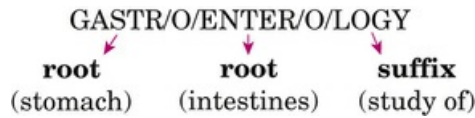
This medical term has two roots. The second root is CARDI, meaning heart. Whenever you see CARDI in other medical terms, you will know that it means heart.

Read the meaning of medical terms from the suffix, back to the beginning of the term, and then across. Broken down this way, ELECTROCARDIOGRAM means record of the electricity in the heart. It is the electrical current flowing within the heart that causes the heart muscle to contract, pumping blood throughout the body. The sound made by contraction and relaxation of the heart muscle is called the heartbeat.

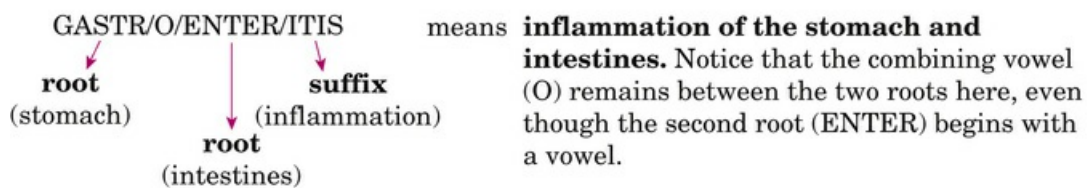
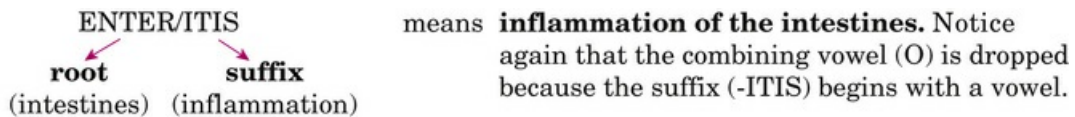
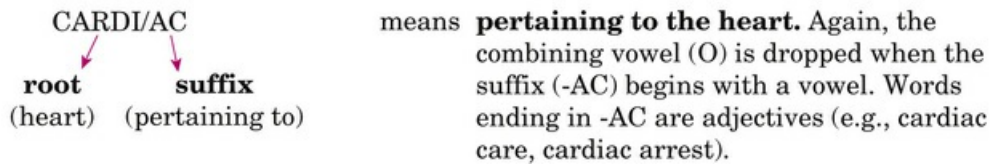
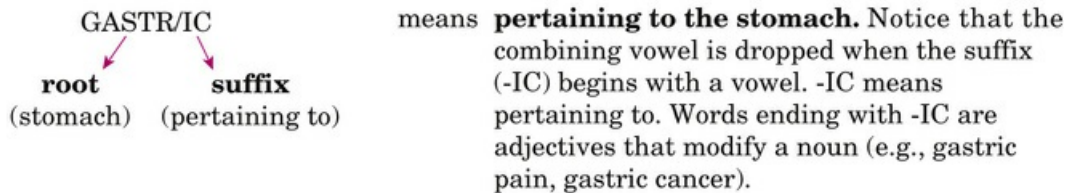
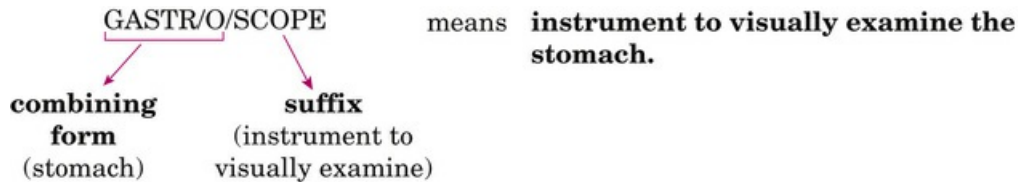
Notice the two combining vowels in ELECTROCARDIOGRAM. Looking for the O in medical terms will help you divide the term into its parts. One combining vowel (O) lies between two roots (ELECTR and CARDI) and another between the root (CARDI) and the suffix (-GRAM).

The combining vowel *plus* the root is called a **combining form**. For example, there are two combining forms in the word ELECTROCARDIOGRAM. These combining forms are ELECTR/O, meaning electricity, and CARDI/O, meaning heart.

Notice how the following medical term is analyzed. Can you locate the two combining forms in this term?



The two combining forms are GASTR/O and ENTER/O. The entire word (reading from the suffix, back to the beginning of the term, and across) means study of the stomach and the intestines. Here are other words that are divided into component parts:



In addition to roots, suffixes, combining forms, and combining vowels, many medical terms have a word part attached to the *beginning* of the term. This is called a **prefix**, and it can change the meaning of a term in important ways. For example, watch what happens to the meaning of the following medical terms when the prefix changes:

SUB/gastr/ic ↓ prefix (below)	means pertaining to <i>below</i> the stomach.
TRANS/gastr/ic ↓ prefix (across)	means pertaining to <i>across</i> the stomach.
RETRO/gastr/ic ↓ prefix (behind)	means pertaining to <i>behind</i> the stomach.

Let's **REVIEW** the important word parts:

1. **Root**—gives the essential *meaning* of the term.
2. **Suffix**—is the word *ending*.
3. **Prefix**—is a small part added to the *beginning* of a term.
4. **Combining vowel**—*connects* roots to suffixes and roots to other roots.
5. **Combining form**—is the combination of the *root* and the *combining vowel*.

Some important rules to **REMEMBER** are:

1. **Read** the meaning of medical words from the suffix to the beginning of the word and then across.
2. **Drop** the combining vowel before a suffix that starts with a vowel.
3. **Keep** the combining vowel between word roots, even if the second root begins with a vowel.

■ Combining Forms, Suffixes, and Prefixes

Presented in this section are lists of combining forms, suffixes, and prefixes that are commonly found in medical terms. Write the meaning of the medical term on the line that is provided. Some terms will be more difficult to understand even after you know the meanings of individual word parts. For these, more extensive explanations are given in *italics*. To check your work, see the **Mini-Dictionary** beginning on page 349, which contains meanings of all terms used in this book.

In your study of medical terminology, you will find it helpful to practice writing terms and their meanings many times. You'll succeed when you follow these simple steps:

1. Complete **Exercises** beginning on page 23 for this chapter, and faithfully check your answers on pages 31 to 32.
2. Fill in the meanings in the **Pronunciation of Terms** list on pages 33 to 36.
3. Apply your knowledge in the **Practical Applications** and **Picture Show** features beginning on page 37.
4. Complete the **Review** of word parts beginning on page 42 and check your answers.
5. Make sure you understand the key medical terminology concepts in the **Terminology CheckUp** on page 45.

Combining Forms

Notice that the **combining form** is in **bold type**, while the root in the medical term is underlined.

Combining Form	Meaning	Medical Term	Meaning
aden/o	gland	<u>adenoma</u> _____	
		-OMA means tumor or mass.	
		<u>adenitis</u> _____	
		-ITIS means inflammation.	
arthr/o	joint	<u>arthritis</u> _____	
bi/o	life	<u>biology</u> _____	
		-LOGY means study of.	
		<u>biopsy</u> _____	
		-OPSY means (process of) viewing. Living tissue is removed and viewed under a microscope.	
carcin/o	cancer, cancerous	<u>carcinoma</u> _____	
cardi/o	heart	<u>cardiology</u> _____	
cephal/o	head	<u>cephalic</u> _____	
		-IC means pertaining to. If an infant is born with the head delivered first, it is a cephalic presentation.	
cerebr/o	cerebrum, largest part of the brain	<u>cerebral</u> _____	
		-AL means pertaining to. Figure 1-1 shows the cerebrum and its functions.	

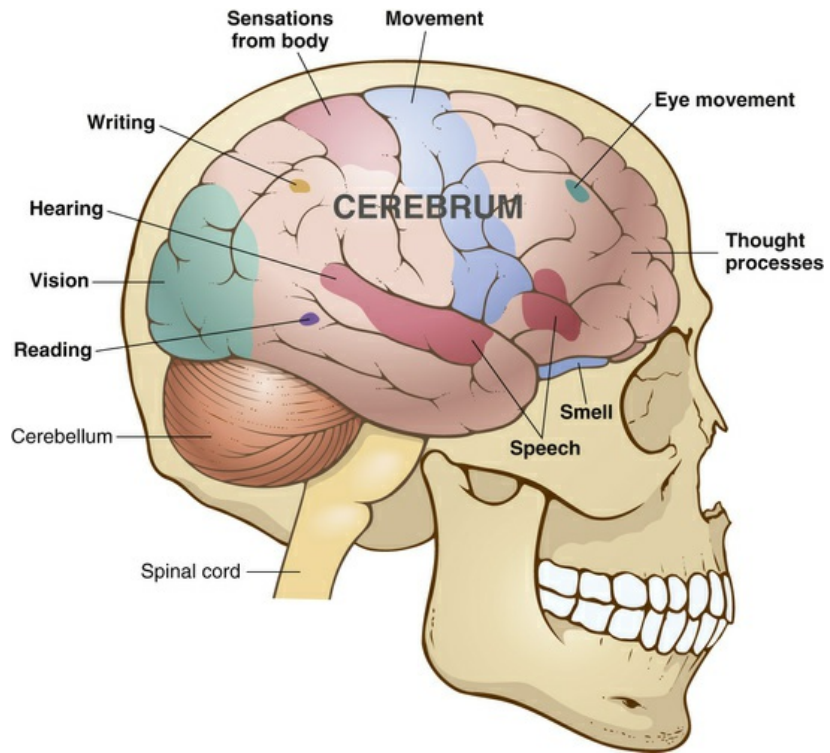


FIGURE 1-1 Functions of the cerebrum.

cerebrovascular accident (CVA)

-VASCULAR means pertaining to blood vessels; a CVA is commonly known as a **stroke**. 🚩

🚩 **What happens in a stroke?**

Blood is prevented from reaching areas of the cerebrum, and brain cells die. Depending on the location and extent of reduced blood flow, signs and symptoms may include loss of movement (paralysis), loss of speech (aphasia), weakness, and changes in sensation.

cyst/o urinary bladder

cystoscope

-SCOPE means instrument to visually examine. *Figure 1-2* shows the urinary bladder and urinary tract in a male. *Figure 1-3* shows a cystoscope placed through the urethra into the urinary bladder of a female during cystoscopy.

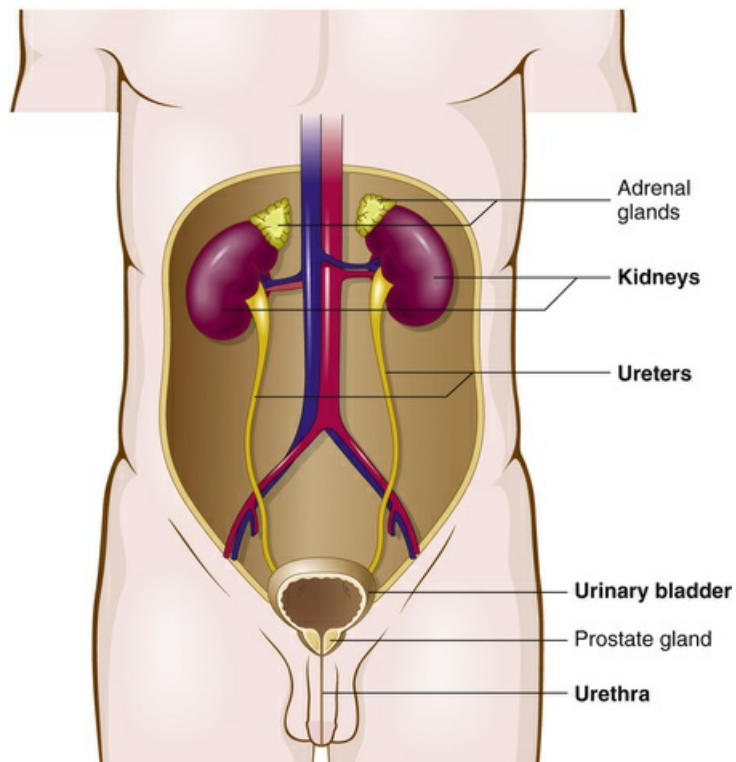


FIGURE 1-2 Male urinary tract. Note that the prostate gland lies below the urinary bladder. It secretes fluid that combines with sperm to

form semen. Semen leaves the body through the urethra during ejaculation. (Modified from Chabner D-E: *The Language of Medicine*, ed 11, St. Louis, 2017, Elsevier.)

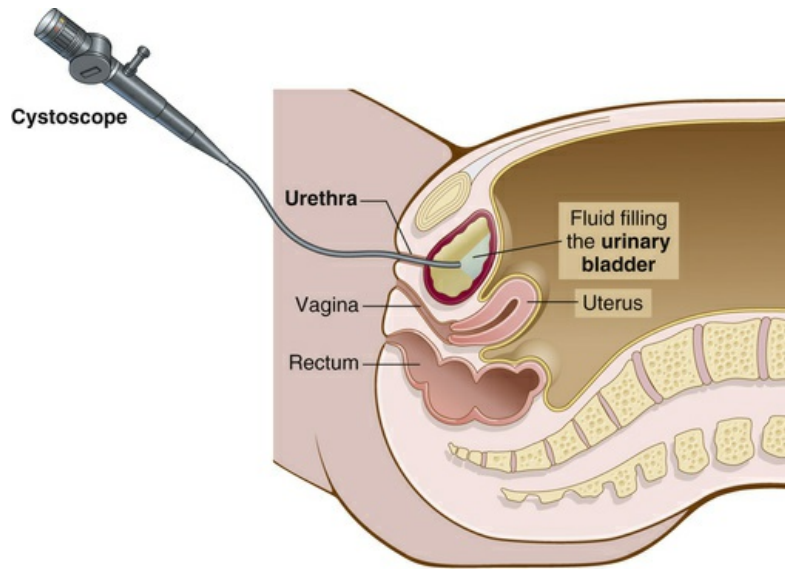


FIGURE 1-3 Female urinary tract. A cystoscope is placed into the urinary bladder through the urethra. (Modified from Chabner D-E: *The Language of Medicine*, ed 11, St. Louis, 2017, Elsevier.)

cyt/o	cell	cytology
derm/o	skin	dermal
dermat/o	skin	dermatitis
electr/o	electricity	electrocardiogram (ECG)
		-GRAM means record. EKG is an older abbreviation for this test.
encephal/o	brain	electroencephalogram (EEG)
		This record is helpful in determining whether a patient has a seizure disorder, such as epilepsy.
enter/o	intestines (often the small intestine)	enteritis
		Figure 1-4 shows the small and large intestines. ENTER/O describes the small intestine and sometimes intestines in general. COL/O and COLON/O are combining forms for the large intestine (colon).

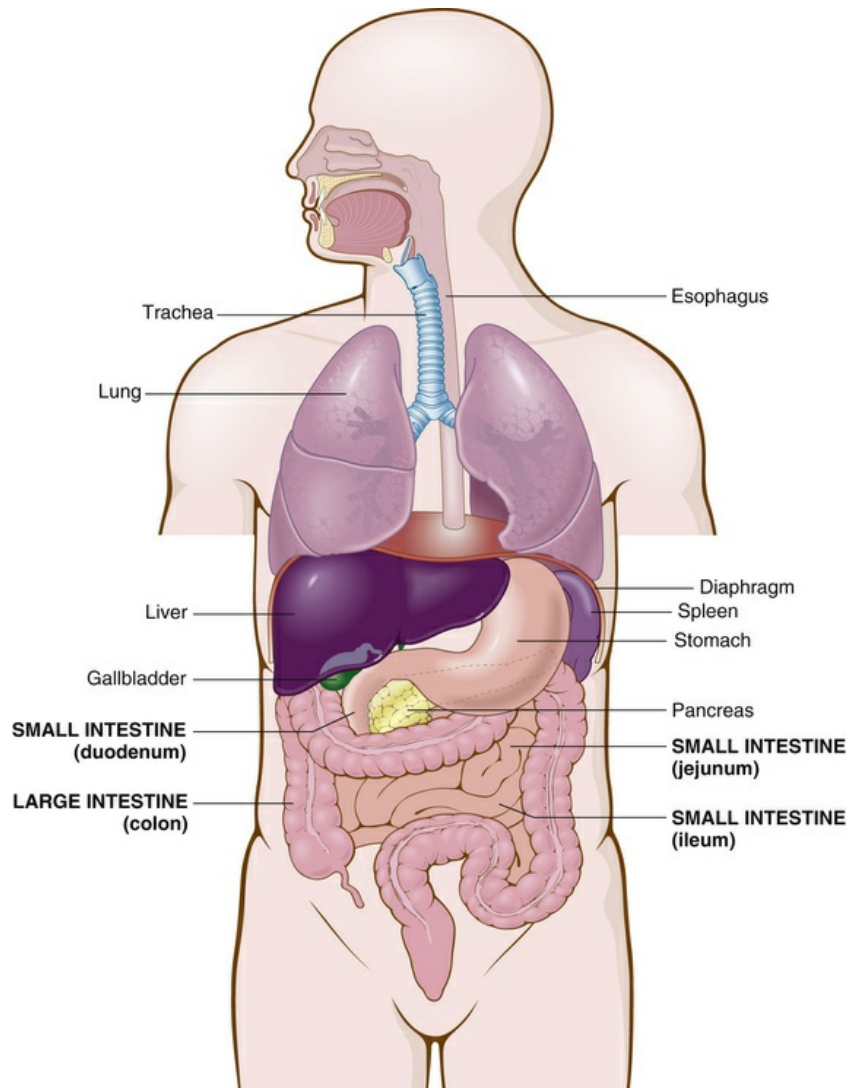


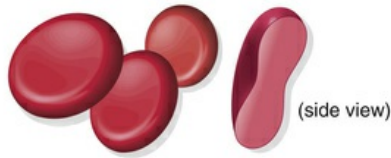FIGURE 1-4 Location of the small and large intestines in the abdominal cavity. Note that the lungs, bronchial tubes, trachea, and esophagus are in the chest cavity, which is above the diaphragm. (Modified from Chabner D-E: *The Language of Medicine*, ed 11, St. Louis, 2017, Elsevier.)

erythr/o red

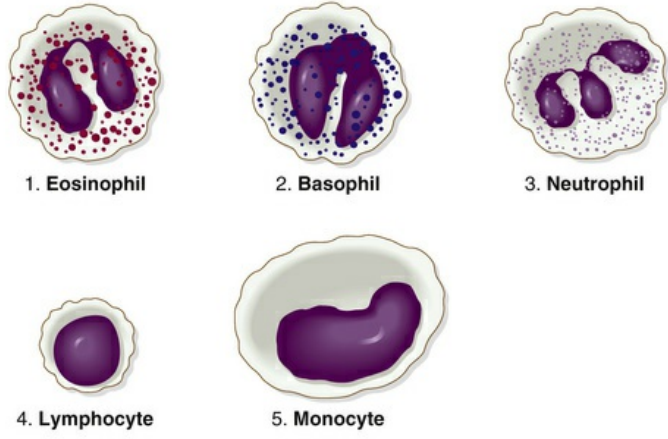
erythrocyte

-CYTE means cell. [Figure 1-5](#) shows the three major types of blood cells.

ERYTHROCYTES



LEUKOCYTES



THROMBOCYTES (platelets)

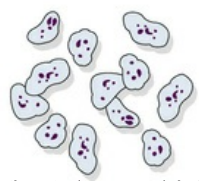

FIGURE 1-5 Blood cells: **erythrocytes** (carry oxygen), **leukocytes** (five different types help fight disease), and **thrombocytes** or **platelets** (help blood to clot). (Modified from Chabner D-E: *The Language of Medicine*, ed 11, St. Louis, 2017, Elsevier.)

gastr/o	stomach	gastroscopy -SCOPY means process of visual examination using an instrument, or "scope."
gnos/o	knowledge	diagnosis -SIS means state of; DIA- means complete. A diagnosis is the complete knowledge gained after testing and examining the patient. The plural diagnosis is diagnoses. Table 1-1 shows other plural formations. prognosis PRO- means before. A prognosis is a prediction (before knowledge) that is made after the diagnosis. It forecasts the outcome of treatment.

TABLE 1-1
FORMATION OF PLURALS

Consult the Mini-Dictionary beginning on page 349 for pronunciations of all terms.		
1. Words ending in a retain the a and add e :		
<i>Singular</i>	<i>Plural</i>	<i>Meaning (of singular term)</i>
vertebra	vertebrae	Backbone
bursa	bursae	Sac of fluid near a joint
2. Words ending in is drop the is and add es :		
<i>Singular</i>	<i>Plural</i>	<i>Meaning (of singular term)</i>
diagnosis	diagnoses	Determination of the nature and cause of a disease
psychosis	psychoses	Abnormal condition of the mind
3. Words ending in ex or ix drop the ex or ix and add ices :		
<i>Singular</i>	<i>Plural</i>	<i>Meaning (of singular term)</i>
apex	apices	Pointed end of an organ
cortex	cortices	Outer part of an organ
varix	varices	Enlarged, swollen vein
4. Words ending in on drop the on and add a :		
<i>Singular</i>	<i>Plural</i>	<i>Meaning (of singular term)</i>
ganglion	ganglia	Group of nerve cells; benign cyst near a joint (such as the wrist)
5. Words ending in um drop the um and add a :		
<i>Singular</i>	<i>Plural</i>	<i>Meaning (of singular term)</i>
bacterium	bacteria	Type of one-celled organism
ovum	ova	Egg cell

6. Words ending in us drop the us and add i *:		
<i>Singular</i>	<i>Plural</i>	<i>Meaning (of singular term)</i>
bronchus	bronchi	Tube leading from the windpipe to the lungs
calculus	calculi	Stone

*Exceptions to this rule are viruses and sinuses.

gynec/o	woman, female	gynecology
hem/o, hemat/o	blood	hemoglobin -GLOBIN means protein. Hemoglobin is the protein in red blood cells (erythrocytes) that helps carry oxygen in the blood. hematoma -OMA means mass or tumor. In this term, -oma indicates a mass or swelling containing blood.
hepat/o	liver	hepatitis

Be careful about spelling this term!

The combining form is **gynec/o**. A **gynecologist** specializes in diseases of the female reproductive organs. Gynecology involves both surgical and internal medicine expertise, and is often practiced with **obstetrics** (care of pregnant women and delivery of a fetus).

Hematoma

A **hematoma** is a mass of blood trapped in tissues of the skin or in an organ. It often results from trauma and is commonly called a bruise or “black-and-b mark. **Figure 1-6** A and B shows hematomas.

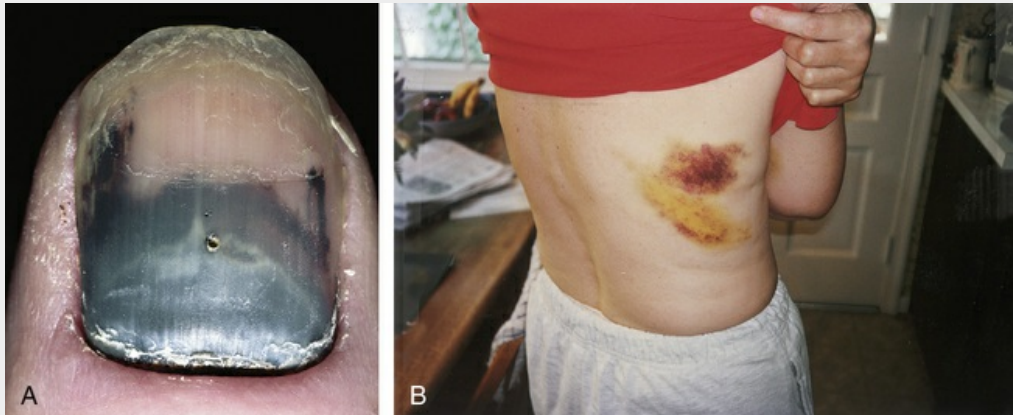


FIGURE 1-6 A, Subungual hematoma. This collection of blood under (SUB-) a nail (UNGU/O = nail) resulted from trauma to the toe. B, Hematoma from broken ribs. (A, From Habif TP. *Clinical Dermatology*, ed 4, St. Louis, 2004, Mosby.)

lapar/o	abdomen (area between the chest and hip)	laparotomy -TOMY means cutting into. In an exploratory laparotomy the surgeon makes a large incision in the abdominal wall to inspect organs for of disease. See Figure 1-7A . Laparoscopy is visual examination of the abdomen using several small incisions for a laparoscope and other instruments. See Figure 1-7B . Another combining form for abdomen is ABDOMIN/O, as in abdominal.
---------	--	--

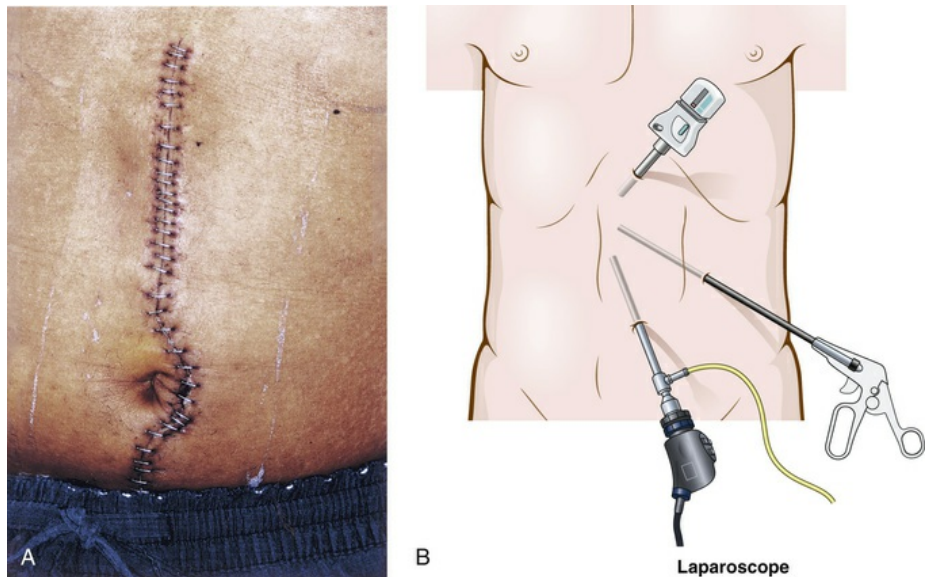
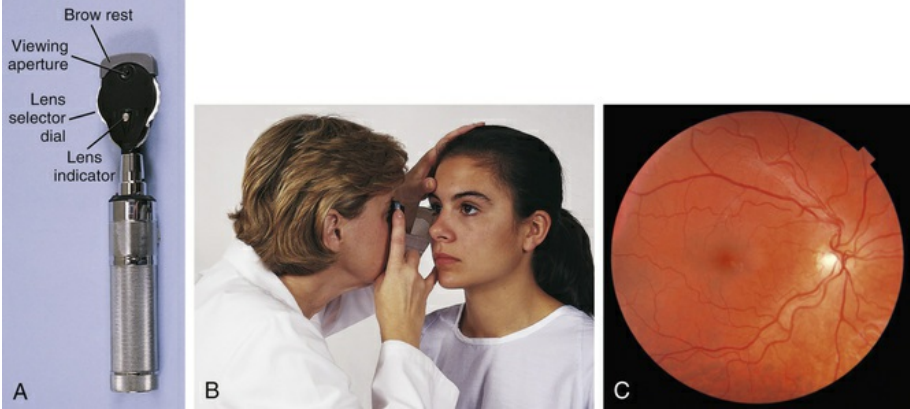
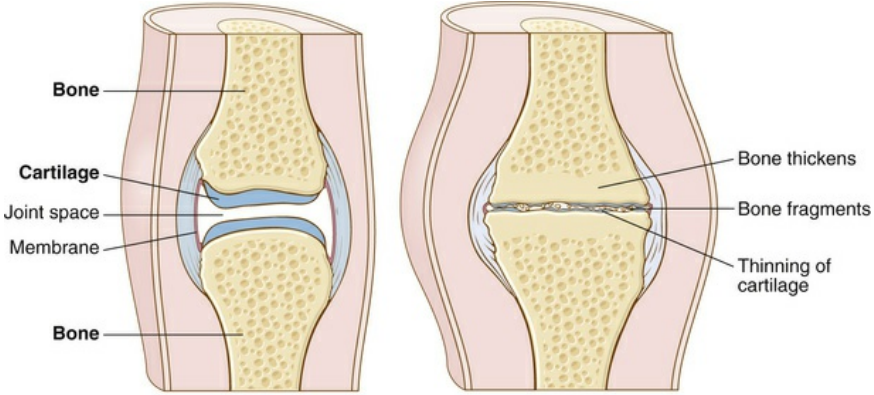


FIGURE 1-7 A, Laparotomy. This large incision was closed with surgical staples. B, Laparoscopy. The abdomen is examined making small incisions and using a laparoscope.

leuk/o	white	<u>leukocyte</u> <i>Figure 1-5 on page 9 shows five different types of leukocytes.</i>
neph/r/o	kidney	<u>nephrectomy</u> -ECTOMY means cutting out—an excision or resection of an organ or other part of the body.
neur/o	nerve	<u>neurology</u>
onc/o	tumor (cancerous)	<u>oncologist</u> -IST means a specialist.
ophthalm/o	eye	<u>ophthalmoscope</u> <i>Figure 1-8A is an image of ophthalmoscope. Figure 1-8B shows an ophthalmologist, a medical doctor, examining a patient's eye. Figure 1-8C the retina, lining the back of the eye (fundus) as seen through an ophthalmoscope.</i>
 <p>FIGURE 1-8 A, Ophthalmoscope. This instrument allows the ophthalmologist to view both the outer and inner areas of the eye. B, Ophthalmoscopic examination. C, The inner or back area (retina) of a normal eye as seen through an ophthalmoscope. (A, Modified from Jarvis, <i>Physical Examination and Health Assessment</i>, St. Louis, 2016, Saunders. B, From Jarvis C: <i>Physical Examination and Health Assessment</i>, ed 3, Philadelphia, 2000, Saunders. C, Courtesy of Dr. Jay Rosen, The Eye Gallery, Scarsdale NY, and Louisa Thompson.)</p>		
oste/o	bone	<u>osteoarthritis</u> <i>Figure 1-9 shows a normal knee joint and a knee joint with osteoarthritis. Degenerative changes with thinning and loss of cartilage occur. Inflammation of the joint membrane occurs late in the disease.</i>
 <p>NORMAL JOINT OSTEOARTHRITIS FIGURE 1-9 Normal knee joint and knee joint with osteoarthritis.</p>		
path/o	disease	<u>pathologist</u> <i>A pathologist is a medical doctor who views biopsy samples to make a diagnosis and examines dead bodies (in an autopsy) to determine the cause of death. AUT- means self, and -OPSY means (process of) viewing. Thus, an autopsy is an opportunity to see for oneself what caused a patient's death.</i>
psych/o	mind	<u>psychosis</u> -OSIS means abnormal condition. In this serious mental condition, the patient loses touch with reality. Psychotic symptoms include hallucinations (unreal sensory perceptions, such as hearing voices when none are present) and delusions (fixed, false beliefs that can't be changed by logical reasoning).
ren/o	kidney	<u>renal</u> <i>Sometimes there are two combining forms for the same part of the body. Often, one comes from Latin and the other from Greek. REN- is the Latin meaning "kidney," and NEPHR- is the Greek root meaning "kidney." The Greek root describes abnormal conditions and procedures, whereas the Latin root is used with -AL, meaning "pertaining to."</i>
rhin/o	nose	<u>rhinitis</u>
sarc/o	flesh	<u>sarcoma</u> <i>Sarcomas and carcinomas are both cancerous tumors. Sarcomas grow from the fleshy (connective) tissues of the body, such as muscle, fat, bone, cartilage, whereas carcinomas arise from skin tissue and the linings of internal organs.</i>
thromb/o	clotting	<u>thrombocyte</u> <i>A thrombocyte (platelet) is a small cell that helps blood to clot. Platelets are shown in Figure 1-5 (see page 9).</i> <u>thrombosis</u> <i>Formation of a thrombus (blood clot) occurs when thrombocytes and other clotting factors combine. Thrombosis describes the condition of</i>

clot (thrombus).

Pathologist/medical examiner/coroner

A **medical examiner (M.E.)** is a **pathologist** who specializes in forensic (legal) medicine related to criminal issues. A **coroner**, however, is an elected official (administrator) who investigates any suspicious death. This official may or may not be a medical examiner.

Suffixes

Each suffix is in **bold** in the Suffix column and underlined in the Medical Term column.


Suffix	Meaning	Medical Term	Meaning
-al	pertaining to	neural	
<i>Other suffixes meaning pertaining to are listed on page 385 in Glossary of Word Parts.</i>			
-algia	condition of pain	arthralgia	
-cyte	cell	leukocyte	
-ectomy	cutting out; removal, excision	gastrectomy	<i>In a partial or subtotal gastrectomy, only a portion of the stomach is removed.</i>
-emia	blood condition	leukemia	<i>Large numbers of immature, cancerous cells are found in the bloodstream and bone marrow (inner part of bone that makes blood cells).</i>
-globin	protein	hemoglobin	
-gram	record	arthrogram	<i>This is an x-ray record of a joint.</i>
-ia	condition	neuralgia	<i>-IA means condition and is part of the larger suffix -ALGIA meaning condition of pain.</i>
-ic	pertaining to	gastric	
-ism	condition, process	hyperthyroidism	<i>HYPER- means excessive. The thyroid gland is in the neck. It secretes the hormone thyroxine, which helps cells burn food to release energy. See 1-10.</i>
			
<p>FIGURE 1-10 Hyperthyroidism (Graves disease). The thyroid gland produces too much hormone, which causes signs and symptoms such as rapid pulse, nervousness, excessive sweating, and swelling of tissue behind the eyeball (resulting in exophthalmos, or “bulging” of the eyes). Notice the enlarged thyroid gland in the neck. (Modified from Seidel H, et al: <i>Mosby’s Guide to Physical Examination</i>, ed 4, St. Louis, 1998, Mosby.)</p>			
-itis	inflammation	gastroenteritis	
-logist	specialist in the study of	neurologist	
-logy	study of	nephrology	<i>See Table 1-2 on page 16 for a list of other terms using -LOGY.</i>
-oma	tumor, mass	hepatoma	<i>This is a cancerous (malignant) tumor, also called hepatocellular carcinoma.</i>
-opsy	to view	biopsy	
-osis	abnormal condition	nephrosis	
		leukocytosis	<i>This is an increase in numbers of normal white blood cells as a response to infection.</i>

TABLE 1-2

TERMS USING -LOGY (STUDY OF)

Cardiology	Study of the heart
Dermatology	Study of the skin
Endocrinology	Study of the endocrine glands
Gastroenterology	Study of the stomach and intestines
Gynecology	Study of women and women's diseases
Hematology	Study of the blood
Neurology	Study of the nerves and the brain and spinal cord
Oncology	Study of tumors (cancerous or malignant diseases)
Ophthalmology	Study of the eye
Pathology	Study of disease
Psychology	Study of the mind and mental disorders
Rheumatology	Study of joint diseases (RHEUMAT/O = flow or watery discharge, which was once thought cause aches and pains, especially in joints)
Urology	Study of the urinary tract (surgical specialty)

-scope instrument to visually examine

gastroscope

laparoscope

-scopy process of visual examination

laparoscopy

Small incisions are made near the navel, and instruments are inserted into the abdomen for viewing organs and performing procedures such as the fallopian (uterine) tubes. See [Figure 1-11](#).

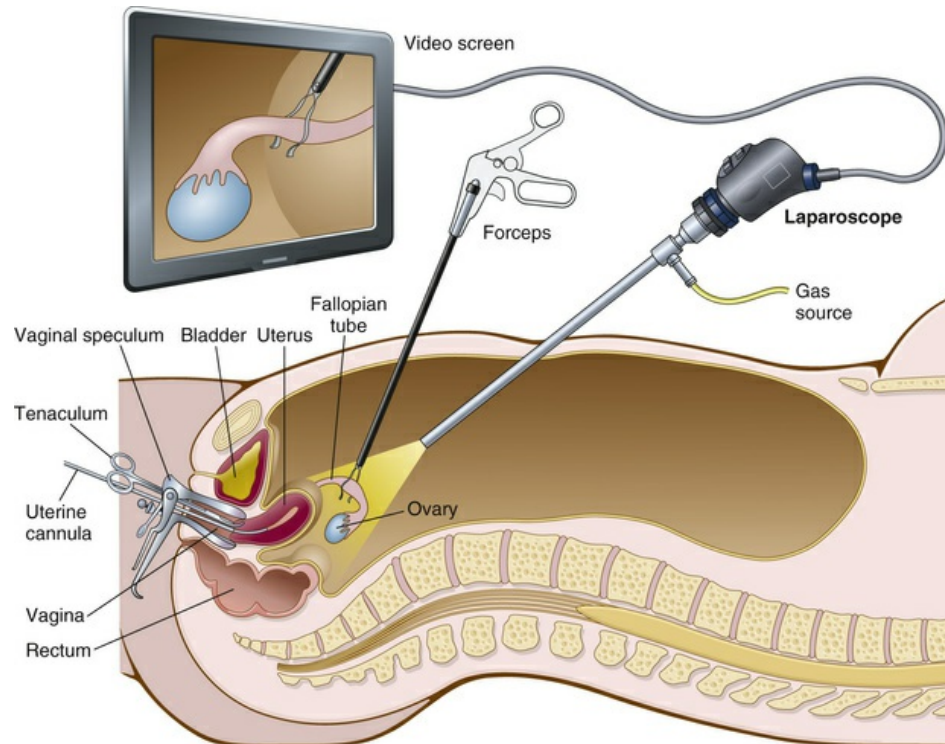


FIGURE 1-11 Laparoscopy for tubal ligation (interruption of the continuity of the fallopian tubes) as a means of preventing future pregnancy. The vaginal speculum keeps the vaginal cavity open. The uterine cannula is a tube placed into the uterus to manipulate the uterus during the procedure. Forceps and tenaculum are used for grasping or manipulating tissue. (Modified from Chabner D-E: *The Language of Medicine*, ed 11, St. Louis, 2017, Elsevier.)

arthroscopy

See [Figure 1-12](#) (page 18).

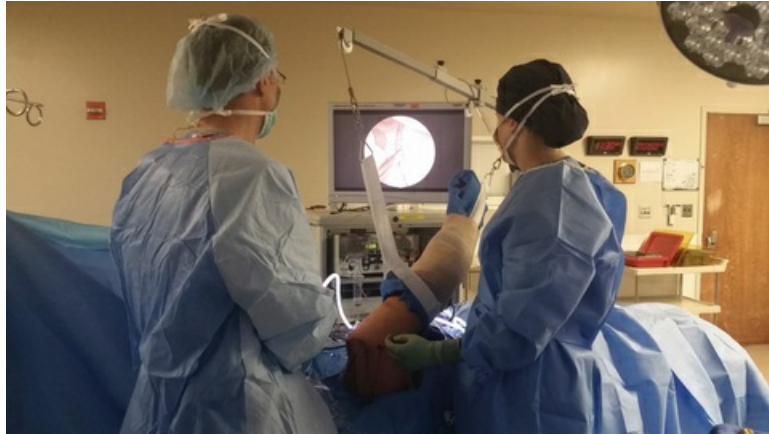

FIGURE 1-12 Arthroscopy of the shoulder. A surgeon (orthopedist) performs an arthroscopic examination to make a diagnosis or treat disease of the joints (courtesy of Michael J. Curtin, MD, St. Luke's Clinic, Boise, Idaho).

-sis	state of	prognosis
-tomy	process of cutting into; incision	neurotomy

Prefixes

Each prefix is in **bold** type in the Prefix column and underlined in the Medical Term column.

Prefix	Meaning	Medical Term	Meaning
a-, an-	no, not	<u>anemia</u> <i>Literally, anemia means a condition of "no blood." Actually, it is a decrease in the number of red blood cells or in hemoglobin, the protein that helps in their ability to carry oxygen.</i>	
aut-	self	<u>autopsy</u> <i>Viewing and examining a dead body with one's own (self) eyes. Here the root OPS- (viewing) is embedded in the suffix -OPSY (process of viewing).</i>	
Where is the root? Some suffixes can contain roots. In the term anemia, notice that the root EM- (from HEM, meaning blood) is embedded in the suffix -EMIA.			
dia-	complete, through	<u>diagnosis</u> <i>In this term, DIA- means complete.</i> <u>diameter</u> <i>The suffix -METER means measurement. DIA- means through in this term.</i>	
dys-	bad, painful, difficult, abnormal	<u>dysentery</u> <i>The suffix -Y means condition or process.</i>	
endo-	within	<u>endocrine glands</u> <i>CRIN/O means to secrete (to form and give off). Examples of endocrine glands are the thyroid gland, pituitary gland, adrenal glands, ovaries, and testes. All of these glands secrete hormones within the body and into the bloodstream.</i> <u>endocardium</u> <i>The valves and chambers within the heart are lined with endocardium. The suffix -UM indicates a structure.</i>	
exo-	outside	<u>exocrine glands</u> <i>Examples of exocrine glands are sweat, tear, and mammary (breast) glands, which secrete substances to the outside of the body.</i>	
hyper-	excessive, more than normal, too much	<u>hyperglycemia</u> <i>GLYC/O means sugar. Hyperglycemia may be a sign of diabetes mellitus. Mellitus means "sweet."</i>	
hypo-	below, less than normal, under	<u>hypoglycemia</u> <i>This condition results from too much insulin in the bloodstream. Symptoms are weakness, headache, and hunger.</i>	
peri-	surrounding	<u>pericardium</u>	
Hyperglycemia and diabetes People with hyperglycemia lack insulin (type 1 diabetes) or have ineffective insulin (type 2 diabetes). Insulin is a hormone normally released by the pancreas, an endocrine gland near the stomach. Insulin allows sugar to leave the bloodstream and enter cells. When insulin is either absent or not working, sugar remains in the blood, resulting in hyperglycemia and diabetes. See <i>In Person: Living with Type 1 Diabetes</i> on page 21.			
pro-	before, forward	<u>prostate gland</u> <i>This exocrine gland "stands" (-STATE) before or in front of the urinary bladder in males (see Figure 1-13).</i>	

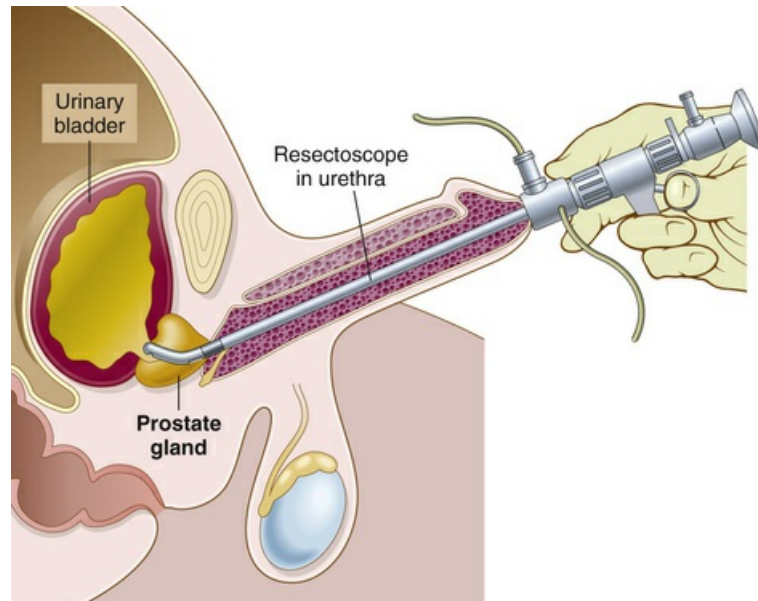


FIGURE 1-13 Transurethral resection of the prostate (TURP). The resectoscope contains a light, valves for controlling irrigating fluid, and an electrical loop that cuts tissue and seals blood vessels. (From Chabner D-E: *The Language of Medicine*, ed 11, St. Louis, 2017, Elsevier.)

re-	back	<u>resection</u> -SECTION means cutting into an organ, but RESECTION means removing some or all of an organ in the sense of cutting back or away. The Latin resectio means "a trimming or pruning."
retro-	behind	<u>retrogastric</u>
sub-	below, under	<u>subhepatic</u>
trans-	across, through	<u>transdermal</u> <u>transurethral</u> 📌 The urethra is a tube that leads from the urinary bladder to the outside of the body.

📌 Transurethral resection of the prostate gland (TURP)

This is a surgical procedure to remove noncancerous (benign) growth of the prostate gland. Pieces of the enlarged gland are removed through the urethra. See [Figure 1-13](#).

In Person: Living With Type 1 Diabetes

The following first-person narrative describes the reality of living with a particular medical condition—type 1 diabetes in a teenager. In each of the subsequent chapters, you'll find other first-person accounts of diseases and procedures that will make your study of medical terminology more relevant to real-life situations.



Jake Sheldon has type 1 diabetes, which was diagnosed when he was 8 years old. The following narrative was written by his mother, Ruthellen Sheldon, based on his teenage years.

On school days, I wake Jake up at 6:30 AM. He tests his blood sugar by pricking his finger until it bleeds, and then sticks a test strip into the drop of blood. Then he inserts the strip into a small hand-held glucometer and waits 3 to 5 seconds for a reading of his blood sugar. If this is 120 mg/dL or higher, he gives himself insulin 10 to 15 minutes before breakfast. He has an insulin pump, so he types in the amount of carbohydrates he will eat, plus his current blood sugar reading. The pump calculates how much insulin he needs to cover the carbs and any extra insulin he may need to bring down a high blood sugar. If Jake's blood sugar is less than 120 mg/dL when he wakes up, he will wait until he takes his first bite of food to give himself his insulin to avoid hypoglycemia.

Throughout the school day, if his blood sugar is high or low, he visits the nurse. If it's high, he gives himself an insulin bolus, or correction, by pump. If his blood sugar is positive for ketones, he is sent home from school. If his blood sugar is low or less than 70, he eats or drinks some fast-acting sugar (Skittles, Smarties, or Sprite) and waits in the healthroom for his blood sugar to rise so he can return to class.

During the night, his dad and I set an alarm to wake up around 3 hours after bedtime. If his blood sugar is high while he sleeps, we use his pump to give him extra insulin, "a correction." If it is low, we wake him and have him drink Sprite or eat Smarties.

The insulin pump is connected to his body with a small cannula [tube]. It is inserted manually through a needle into his hip region. The needle is then removed and the tiny Teflon cannula remains in his body, delivering fast-acting insulin under the skin. His pump is always connected to him with plastic tubing, and he carries it with him in his pants pocket. When he bathes, he can disconnect the pump, and when he sleeps, he places it on the mattress next to his body.

When Jake is playing sports, he times his meals with the start of the activity so his blood sugar is around 150 mg/dL. He disconnects his pump during sports, and at halftime he tests his blood sugar. If it is low, he needs to eat. If it is high, he needs to reconnect his pump and administer more insulin.

In general, Jake's diabetes doesn't disrupt his life other than for his nighttime checks, wearing an insulin pump, and paying attention to how many carbs he eats. We encourage him to make good nutritional choices and to limit certain foods (doughnuts, Slurpees, candy) to special occasions. He also must carry a glucometer with him at all times and a sugar to take when his blood glucose is low.

Having a child with diabetes forces me to carefully plan the preparation and timing of meals. I always have certain foods and medical supplies in the house, and I also carry snacks and sugar sources wherever I go. My husband and I hope that keeping Jake's blood sugar in tight control will

help avoid many of the complications frequently encountered later in life by people with type 1 diabetes.

Throughout high school, Jake took over all diabetes management tasks and managed his diabetes 100 percent independently before his graduation. Moving out of state to college, Jake has had to learn how cafeteria foods, late nights, and new social situations affect his blood sugars. Jake is also learning how to manage ordering and maintaining a vast number of diabetes supplies and prescriptions in his dorm room. Jake will also be transitioning from his pediatric endocrinologist to an adult endocrinologist this year.



Ruthellen Sheldon and her son, Jake, now 18 years old.

Exercises and Answers

These exercises give you practice writing and understanding the terms presented in the chapter. An important part of your work is to **check your answers** with the Answers to Exercises beginning on page 31. If you cannot answer a question, then please look at the answer key and **copy** the correct answer. You may want to photocopy some of the exercises before you complete them so that you can practice doing them many times. **Remember the 3 “Rs”—wRite, Review, Repeat—and you will succeed!**

Visit the Evolve website (<http://evolve.elsevier.com/Chabner/medtermshort>) for additional information, images, games, videos, and interactive activities.

A Using slashes (/), divide the following terms into their component parts and give the meaning for the whole term. The first term is completed as an example.

1. aden/oma tumor of a gland

2. arthritis

3. biopsy

4. cardiology

5. dermal

6. cytology

7. cystoscope

8. cerebral

9. cephalic

10. adenitis

B Complete the following sentences using the medical terms given below.

diagnosis

electrocardiogram

electroencephalogram

enteritis

erythrocyte

gynecology

hematoma
hemoglobin
hepatitis
prognosis

1. A mass of blood, or "black-and-blue" mark, is a/an _____.
2. A red blood cell is a/an _____.
3. Inflammation of the small intestine is _____.
4. The prediction about the outcome of an illness is a/an _____.
5. The record of electricity in the brain is a/an _____.
6. The study of women and women's diseases is _____.
7. The record of electricity in the heart is a/an _____.
8. Complete knowledge of a patient's illness on the basis of tests and other information is a/an _____.
9. A protein found in red blood cells is _____.
10. Inflammation of the liver is _____.

C Name the tissue or part of the body contained in the following terms and give the meaning of the entire term.

Tissue/Body Part	Meaning of Term
1. laparotomy	
2. nephrectomy	
3. neuritis	
4. ophthalmoscope	
5. osteotomy	
6. renal	
7. rhinitis	
8. sarcoma	

D Give the meanings of the following terms.

1. oncologist

2. pathologist

3. psychosis

4. leukocyte

5. thrombocyte

6. gastritis

7. adenoma

8. thrombosis

E Give the meanings of the following suffixes.

1. -cyte

2. -ism

3. -ectomy

4. -al

5. -emia

6. -gram

7. -algia

8. -itis

9. -globin

10. -ic

F Complete the following medical terms to end each sentence.

1. Nerve pain is **neur**_____.

2. Presence of large numbers of immature, cancerous white blood cells is a blood condition known as **leuk**_____.

3. An x-ray record of a joint is **arthro**_____.

4. Study of the kidney is **nephro**_____.

5. Tumor of the liver is **hepat**_____.
6. Visual examination of the abdomen is **laparo**_____.
7. An incision of a joint is called **arthro**_____.
8. Abnormal condition of the skin is **dermat**_____.
9. Inflammation of the skin is **dermat**_____.
10. A specialist in the study of blood is a **hemato**_____.

G Give the meanings of the following prefixes.

1. hyper-

2. sub-

3. dys-

4. trans-

5. retro-

6. dia-

7. exo-

8. aut-

9. hypo-

10. endo-

11. peri-

H Give the meanings of the following medical terms.

1. autopsy

2. hyperthyroidism

3. anemia

4. dysentery

5. endocrine glands

6. hypoglycemia

7. exocrine glands

8. resection

9. transdermal

10. hyperglycemia

I Complete the following medical terms related to the stomach.

1. _____ gastric	Pertaining to under the stomach
2. gastr _____	Pain in the stomach
3. gastr _____	Inflammation of the stomach
4. _____ gastric	Pertaining to across or through the stomach
5. gastr _____	Process of visually examining the stomach
6. _____ gastric	Pertaining to behind the stomach
7. gastr _____	Study of the stomach and intestines
8. gastr _____	Incision of the stomach
9. gastr _____	Excision of the stomach
10. gastr _____	Instrument to visually examine the stomach

J On the line provided, give the meaning of the term in bold.

1. An **oncologist** treats abnormal conditions such as sarcomas and carcinomas.

2. After explaining the diagnosis, Dr. Jones outlined the treatment and assured the patient that the **prognosis** was hopeful.

3. Elderly Mrs. Scott has constant arthralgia in her knees and hips. Her physician prescribes anti-inflammatory drugs and aspirin to treat her **osteoarthritis** but advises that joint replacement may be necessary.

4. A **pathologist** is a medical doctor who performs autopsies and examines biopsy samples.

5. **Thrombosis** is a serious condition that may result in blockage of blood vessels.

6. **Hyperglycemia** results from lack of insulin (hormone) secretion from the pancreas

(endocrine gland near the stomach). Without insulin, sugar cannot enter cells and remains in the blood. _____

7. Schizophrenia is an example of a **psychosis**, in which the patient loses touch with reality and displays abnormal behavior (delusions and hallucinations may occur).

8. Minimally invasive surgery of the abdomen may be performed using **laparoscopy**. For example, a gallbladder or appendix can be removed with instruments inserted through small incisions.

9. Clinical signs of **hyperthyroidism** include an enlarged thyroid gland and protruding eyeballs (exophthalmos).

10. Sally's diagnosis of **dysentery** was made after she returned from a trip to Mexico with abdominal pain, fever, and severe diarrhea (loose, watery stools).

11. Mr. Smith died of a **cerebrovascular accident**. Confirmation at autopsy revealed a thrombus blocking one of his cerebral arteries.

12. **Erythrocytes** contain hemoglobin, which enables them to carry oxygen throughout the body. _____

13. **Leukemia** was confirmed after a bone marrow biopsy and high white blood cell counts.

14. Certain types of bleeding or clotting disorders may be caused by reduced numbers of thrombocytes, also known as **platelets**. _____

15. An example of **anemia** is iron deficiency anemia.

16. **Transdermal** delivery by patch is used for administering drugs such as nicotine, nitroglycerin, and scopolamine (for motion sickness).

17. When Bill had difficulty urinating (urinary retention), his doctor discovered that his **prostate gland** was enlarged.

18. To relieve his symptoms related to urinary retention, Bill's urologist performed a **transurethral resection** of his enlarged prostate gland.

19. Although the small intestine is longer (20 feet) than the large intestine (5 feet), the **diameter** of the large intestine (colon) is greater.

K Refer to [Table 1-1, page 10](#), to form the plurals of the following terms.

1. psychosis

2. ovum

3. vertebra

4. bronchus

5. spermatozoon

6. apex

L In the following medical vignettes, circle the bold term that best completes the meaning of the sentences.

1. Selma ate a spicy meal at an Indian restaurant. Later that night she experienced **(osteoarthritis, dermatitis, gastroenteritis)**. Fortunately the cramping and diarrhea subsided by morning.
2. Christina was feeling very sluggish, both physically and mentally. Her hair seemed coarse, she had noticed weight gain in the past weeks, and she had hot and cold intolerance. Her internist ordered a blood test that revealed low levels of a hormone normally secreted from a gland in the neck. She was referred to a specialist, a/an **(gynecologist, endocrinologist, pathologist)**. The physician ordered a blood test that confirmed low levels of the hormone. The diagnosis of **(hypothyroidism, hyperthyroidism, psychosis)** was thus made, and proper treatment prescribed.
3. Dr. Fischer examined the lump in Bruno's thigh. An imaging technique using magnetic waves and radio signals (MRI scan) revealed a suspicious mass in the soft connective tissue of the thigh. Suspecting a cancerous mass of flesh tissue, or **(hematoma, carcinoma, sarcoma)**, Dr. Fischer ordered a/an **(prognosis, biopsy, autopsy)** of the mass.
4. On her seventh birthday, Susie fell down during her birthday party. Her mother noticed bruises on Susie's knees and elbows that seemed to "come up overnight." Her pediatrician ordered a blood test, which demonstrated a decreased platelet count and an elevated **(leukocyte, erythrocyte, thrombocyte)** count at 40,000 cells. Susie was referred to a/an **(dermatologist, nephrologist, oncologist)**, who made a diagnosis of **(hepatitis, anemia, leukemia)**.
5. When Mr. Saluto collapsed and died while eating dinner, the family requested a/an **(laparotomy, gastroscopy, autopsy)** to determine the cause of death. The **(hematologist, pathologist, gastroenterologist)** discovered that Mr. Saluto had died of a **(cardiovascular accident, dysentery, cerebrovascular accident)**, otherwise known as a stroke.

Answers to Exercises

A

1. Tumor of a gland
2. Inflammation of a joint
3. Process of viewing living tissue under a microscope
4. Study of (process of study of) the heart
5. Pertaining to the skin
6. Study of (process of study of) cells
7. Instrument to visually examine the urinary bladder
8. Pertaining to the cerebrum (largest part of the brain)
9. Pertaining to the head
10. Inflammation of a gland

B

1. hematoma
2. erythrocyte
3. enteritis
4. prognosis
5. electroencephalogram
6. gynecology
7. electrocardiogram
8. diagnosis
9. hemoglobin
10. hepatitis

C

1. abdomen: incision of the abdomen (this is also called exploratory surgery)
2. kidney: excision (removal, resection) of the kidney
3. nerve: inflammation of a nerve
4. eye: instrument to visually examine the eye
5. bone: incision (to cut into, section) of a bone
6. kidney: pertaining to the kidney
7. nose: inflammation of the nose
8. flesh tissue: tumor (cancerous or malignant) of flesh tissue

D

1. Specialist in the study of tumors (cancerous or malignant tumors)
2. Specialist in the study of disease (examines biopsy samples and performs autopsies)
3. Abnormal condition of the mind
4. White blood cell
5. Clotting cell or platelet
6. Inflammation of the stomach
7. Tumor of a gland (this is a benign or harmless tumor). An adenocarcinoma is a malignant tumor (CARCIN/O means cancerous).
8. Abnormal condition of clotting (occurring in a blood vessel)

E

1. cell
2. condition, process
3. process of cutting out, excision, resection, removal
4. pertaining to
5. condition of blood (blood condition)
6. record
7. pain; condition of pain
8. inflammation
9. protein
10. pertaining to

F

1. neuralgia
2. leukemia
3. arthrogram
4. nephrology
5. hepatoma or hepatocellular carcinoma
6. laparoscopy
7. arthrotomy
8. dermatosis
9. dermatitis
10. hematologist

G

1. excessive, above, more than normal
2. under, below
3. abnormal, bad, difficult, painful
4. across, through
5. behind, back
6. complete, through
7. out, outside
8. self
9. below, deficient, less than normal
10. within, in, inner
11. surrounding

H

1. Examination of a dead body to determine the cause of death
2. Excessive activity of the thyroid gland
3. Deficiency of hemoglobin or numbers of red blood cells; literally, "no" (AN-) "blood" (-EMIA)
4. Condition of painful intestines; marked by inflammation, abdominal pain, and frequent and bloody stools and often caused by bacteria
5. Organs that produce (secrete) hormones directly into the bloodstream
6. Blood condition of decreased sugar (lower-than-normal levels)
7. Organs that produce (secrete) chemicals to the outside of the body (through tubes or ducts)
8. Removal (excision) of an organ or structure
9. Pertaining to through the skin
10. Blood condition of increased sugar (higher than normal levels)

I

1. subgastric or hypogastric
2. gastralgia
3. gastritis
4. transgastric
5. gastroscopy
6. retrogastric
7. gastroenterology

8. gastrotomy
9. gastrectomy
10. gastroscope

J

1. Specialist in the study (and treatment) of tumors
2. Prediction of the outcome of an illness or treatment
3. Inflammation of bones and joints (including degeneration of joints)
4. Specialist in the study of disease
5. Abnormal condition of clotting (clot formation)
6. Blood condition of increased sugar (high blood sugar)
7. Abnormal condition of the mind
8. Visual examination of the abdomen
9. Condition of increased secretion of hormone from the thyroid gland
10. Condition of painful intestines
11. Stroke; trauma to blood vessels of the brain (cerebrum)
12. Red blood cells
13. Increase in cancerous (malignant) white blood cells in blood and bone marrow
14. Clotting cells
15. Deficiency of hemoglobin and/or decrease in number of red blood cells; results in reduced oxygen to cells
16. Pertaining to through the skin
17. Gland in males located in front of the urinary bladder (the prostate is an exocrine gland)
18. Removal of portions of the prostate gland through the urethra (procedure is called TURP)
19. Measurement of the width across a circle

K

1. psychoses (drop **-is** and add **-es**)
2. ova (drop **-um** and add **-a**)
3. vertebrae (add **-e**)
4. bronchi (drop **-us** and add **-i**)
5. spermatozoa (drop **-on** and add **-a**)
6. apices (drop **-ex** and add **-ices**)

L

1. gastroenteritis
2. endocrinologist, hypothyroidism
3. sarcoma, biopsy
4. leukocyte, oncologist, leukemia
5. autopsy, pathologist, cerebrovascular accident

■ Pronunciation of Terms

The terms that you have learned in this chapter are presented here with their pronunciations. The capitalized letters in **BOLDFACE** indicate the accented syllable. Pronounce each word out loud; then write the meaning in the space provided. All meanings of terms are found in the **Mini-Dictionary** beginning on page 349, and on the audio section of the Evolve site (<http://evolve.elsevier.com/Chabner/medtermshort>). After you write all of the meanings, it is a good idea to cover the Term column and write each term from its meaning.

Term	Pronunciation	Meaning
adenitis	ad-eh- NI -tis	
adenoma	ah-deh- NO -mah	
anemia	ah- NE -me-ah	
arthralgia	ar- THRAL -jah	
arthritis	ar- THRI -tis	
arthrogram	AR -thro-gram	
arthroscope	AR -thro-skope	
arthroscopy	ar- THROS -ko-pe	
autopsy	AW -top-se	
biology	bi- OL -o-je	
biopsy	BI -op-se	
carcinoma	kar-sih- NO -mah	
cardiac	KAR -de-ak	
cardiology	kar-de- OL -o-je	
cephalic	seh- FAL -ik	
cerebral	seh- RE -bral	
cerebrovascular accident	seh-re-bro- VAS -ku-lar AK -sih-dent	
cystoscope	SIS -to-skope	
cystoscopy	sis- TOS -ko-pe	
cytology	si- TOL -o-je	
dermal	DER -mal	
dermatitis	der-mah- TI -tis	
dermatosis	der-mah- TO -sis	
diagnosis	di-ag- NO -sis	
diameter	di- AM -eh-ter	
dysentery	DIS -en-teh-re	
electrocardiogram	e-lek-tro- KAR -de-o-gram	
electroencephalogram	e-lek-tro-en- SEF -ah-lo-gram	
endocardium	en-do- KAR -de-um	
endocrine glands	EN -do-krin glanz	
endocrinology	en-do-krin- NOL -o-je	
enteritis	en-teh- RI -tis	
erythrocyte	eh- RITH -ro-site	
exocrine glands	EK -so-krin glanz	
gastrectomy	gas- TREK -to-me	
gastric	GAS -trik	
gastritis	gas- TRI -tis	
gastroenteritis	gas-tro-en-teh- RI -tis	
gastroenterology	gas-tro-en-ter- OL -o-je	
gastroscope	GAS -tro-skope	
gastroscope	gas- TROS -ko-pe	
gastrotomy	gas- TROT -o-me	
gynecologist	gi-neh- KOL -o-jist	
gynecology	gi-neh- KOL -o-je	
hematoma	he-mah- TO -mah	
hemoglobin	HE -mo-glo-bin	
hepatitis	hep-ah- TI -tis	
hepatoma	hep-ah- TO -mah	
hyperglycemia	hi-per-gli- SE -me-ah	
hyperthyroidism	hi-per- THI -royd-izm	
hypoglycemia	hi-po-gli- SE -me-ah	
hypothyroidism	hi-po- THI -royd-izm	
laparoscope	LAP -ah-ro-skope	
laparoscopy	lap-ah- ROS -ko-pe	
laparotomy	lap-ah- ROT -o-me	
leukemia	loo- KE -me-ah	
leukocyte	LOO -ko-site	
leukocytosis	loo-ko-si- TO -sis	
nephrectomy	neh- FREK -to-me	
nephrology	neh- FROL -o-je	

nephrosis	neh-FRO-sis
neural	NU-ral
neuralgia	nu-RAL-jah
neuritis	nu-RI-tis
neurology	nu-ROL-o-je
neurotomy	nu-ROT-o-me
oncologist	ong-KOL-o-jist
ophthalmoscope	of-THAL-mo-skope
osteitis	os-te-I-tis
osteoarthritis	os-te-o-ar-THRI-tis
pathologist	pah-THOL-o-jist
pericardium	peh-rih-KAR-de-um
platelet	PLAYT-let
prognosis	prog-NO-sis
prostate gland	PROS-tayt gland
psychosis	si-KO-sis
renal	RE-nal
resection	re-SEK-shun
retrogastric	reh-tro-GAS-trik
rhinitis	ri-NI-tis
rhinotomy	ri-NOT-o-me
sarcoma	sar-KO-mah
subgastric	sub-GAS-trik
subhepatic	sub-heh-PAT-ik
thrombocyte	THROM-bo-site
thrombosis	throm-BO-sis
transdermal	tranz-DER-mal
transgastric	tranz-GAS-trik
transurethral	tranz-u-RE-thral

■ Practical Applications

Medical Conditions and Specialists

Match the following physician specialists with the condition each would treat.

cardiologist

dermatologist

endocrinologist

gastroenterologist

gynecologist

hematologist

neurologist

oncologist

ophthalmologist

urologist

1. Cerebrovascular accident _____

2. Skin cancer _____

3. Dysentery _____

4. Anemia _____

5. Lung cancer _____

6. Prostate gland enlargement _____

7. Hyperglycemia _____

8. Cataract (clouding of the lens of the eye) _____

9. Heart attack _____

10. Abnormal bleeding of the uterus from the vagina _____

What's Your Diagnosis?

Case Study

This seven-year-old boy presents with fever, sore throat, runny nose, and persistent fatigue [feeling of being tired all the time]. Physical examination reveals multiple bruises [contusions] of his lower extremities and arms, an erythematous [red] pharynx [throat] with white plaques on the tonsils, and pale gums, lips, and nailbeds. CBC [complete blood count] was performed. Increasing fever prompted immediate admission to the children's ward of the hospital.

During the course of admission, the patient's pharyngitis was monitored and subsided. Tonsillitis was ruled out. Fatigue and contusions on his arms and legs were noted and addressed with the parents while taking his social history. A lab hematologist reviewed the high WBC [white blood cell] count, and a WBC differential [percentages of the various types of these cells] shows immature cells. A bone marrow biopsy confirms the diagnosis of WBC malignancy.

Using the information presented in this case study, what's your diagnosis?

- A. Hyperthyroidism
- B. Leukemia
- C. Fever
- D. Contusions—arms/legs
- E. Leukocytosis

Answers to Practical Applications

Medical Conditions and Specialists

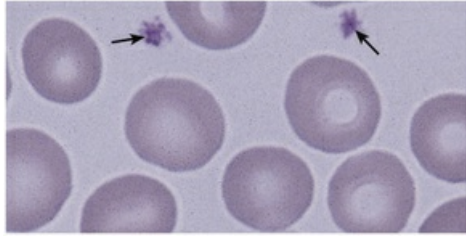
1. neurologist
2. dermatologist
3. gastroenterologist
4. hematologist
5. oncologist
6. urologist
7. endocrinologist
8. ophthalmologist
9. cardiologist
10. gynecologist

What's Your Diagnosis?

Answer: B. Leukemia

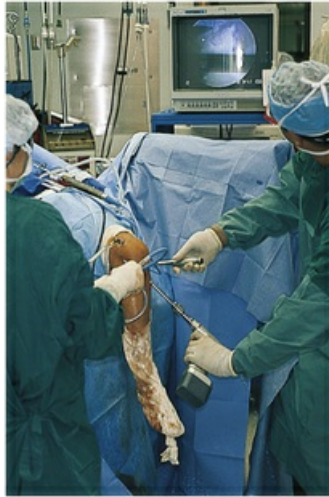Picture Show

Answer the questions that follow each image. Answers are found on [page 41](#).



A Blood smear. (Modified from Carr JH, Rodak BF: *Clinical Hematology Atlas*, Philadelphia, 1999, Saunders.)

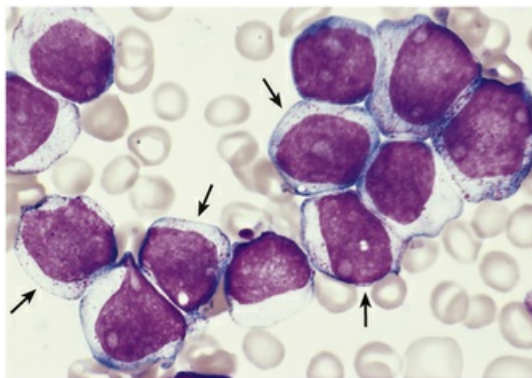
1. The arrows in this photo of a blood smear are pointing to cells that are necessary in blood clotting. These cells are:
 - a. leukocytes
 - b. thrombosis
 - c. platelets
 - d. erythrocytes
2. The other blood cells in the photo contain a protein that helps the cell carry oxygen. These cells are:
 - a. leukocytes
 - b. thrombosis
 - c. platelets
 - d. erythrocytes
3. The protein contained in the cells is:
 - a. hemoglobin
 - b. anemia
 - c. sarcoma
 - d. carcinoma



B (From Miller MD, Howard RF, Plancher KD: *Surgical Atlas of Sports Medicine*, Philadelphia, 2003, Saunders.)

1. The image shows a minimally invasive procedure used to visually examine the knee. This procedure is:

- a. laparotomy
- b. arthroscopy
- c. laparoscopy
- d. arthrectomy



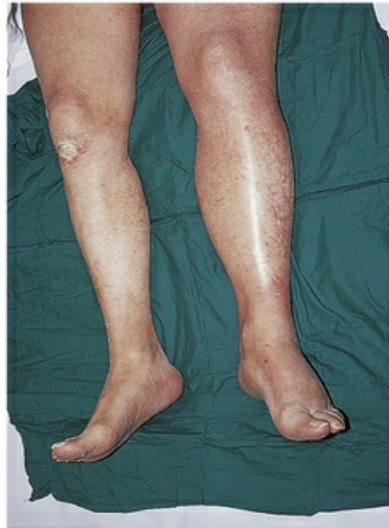C Blood smear. (Courtesy Dr. Robert W. McKenna, Department of Pathology, University of Texas Southwestern Medical School, Dallas, Texas; from Kumar V, Cotran RS, Robbins SL, editors: *Basic Pathology*, ed 8, Philadelphia, 2007, Saunders.)

1. In this blood smear, the arrows point to an increased number of large, immature cells (that would normally fight infection). These cells are:

- a. hepatocytes
- b. erythrocytes
- c. thrombocytes
- d. leukocytes

2. The name of the abnormal condition in which these cells predominate is:

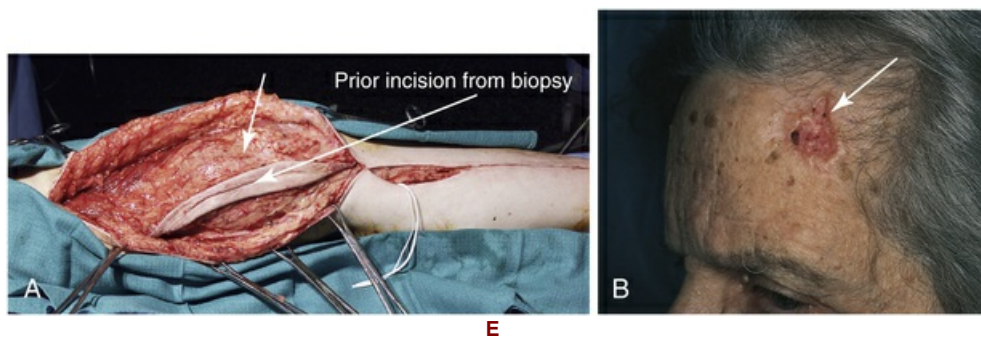
- a. iron deficiency anemia
- b. sickle cell anemia
- c. leukemia
- d. hyperglycemia



D (From Forbes CD, Jackson WF: *Color Atlas and Text of Clinical Medicine*, ed 3, London, 2003, Mosby.)

1. Notice that the left leg of the patient is swollen (edema), resulting from blood flow that is slow and sluggish. Fluid seeps out of tiny vessels into tissue spaces. The abnormal condition often associated with this problem is caused by a blood clot in a blood vessel. The condition is called:

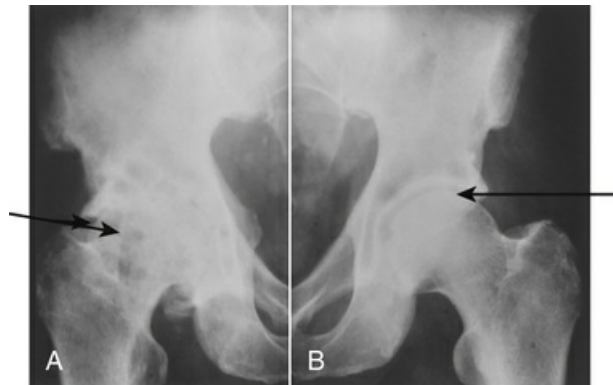
- a. hyperglycemia
- b. deep vein thrombosis
- c. cerebrovascular accident
- d. hematoma



1. The lesion pictured in A is a/an:

- a. hepatoma

- b. sarcoma of muscle
 - c. adenoma
 - d. basal cell carcinoma
2. The lesion pictured in *B* is a/an:
- a. hepatoma
 - b. sarcoma of muscle
 - c. adenoma
 - d. basal cell carcinoma



F (Courtesy American Rheumatism Association; from Noble J: *Textbook of Primary Care Medicine*, ed 3, St. Louis, 2001, Mosby.)

1. The image in *A* shows degeneration of the hip (pelvic) joint with narrowed joint spaces (see arrow). The image in *B* shows a normal hip for comparison (see arrow). The patient with the hip changes has arthralgia, stiffness, and joint tenderness. Your diagnosis?
- a. osteoarthritis
 - b. gastroenteritis
 - c. hyperthyroidism
 - d. osteogenic sarcoma

Answers to Picture Show

A

- 1. c
- 2. d
- 3. a

B

- 1. b

C

1. d

2. c

D

1. b

E

1. b

2. d

F

1. a

Review

Here is your chance to test your understanding of all the **combining forms, suffixes, and prefixes** that you have studied in this chapter. Write the meaning of each term in the space provided and **check** your answers with the Answers to Review section on [page 44](#). All of the meanings for word parts are found in **Glossary of Word Parts** beginning on [page 385](#). Remember the 3 “Rs” — *wRite, Repeat, Review*.

Combining Forms

Combining Form	Meaning
1. aden/o _____	
2. arthr/o _____	
3. bi/o _____	
4. carcin/o _____	
5. cardi/o _____	
6. cephal/o _____	
7. cerebr/o _____	
8. crin/o _____	
9. cyst/o _____	
10. cyt/o _____	
11. derm/o, dermat/o _____	
12. electr/o _____	
13. encephal/o _____	
14. enter/o _____	
15. erythr/o _____	
16. gastr/o _____	
17. glyco/o _____	
18.gnos/o _____	
19. gynec/o _____	
20. hem/o, hemat/o _____	
21. hepat/o _____	
22. lapar/o _____	
23. leuk/o _____	
24. nephro/o _____	
25. neur/o _____	
26. onc/o _____	
27. ophthalm/o _____	
28. oste/o _____	
29. path/o _____	
30. psych/o _____	
31. ren/o _____	
32. rhin/o _____	
33. sarc/o _____	
34. thrombo/o _____	

Suffixes

Suffix	Meaning
1. -al _____	
2. -algia _____	
3. -cyte _____	
4. -ectomy _____	
5. -emia _____	
6. -globin _____	
7. -ia _____	
8. -ic _____	
9. -ism _____	
10. -itis _____	
11. -logist _____	
12. -logy _____	
13. -oma _____	
14. -opsy _____	
15. -osis _____	
16. -scope _____	
17. -scopy _____	
18. -sis _____	
19. -tomy _____	

Prefixes

Prefix	Meaning
1. a-, an-	_____
2. aut-	_____
3. dia-	_____
4. dys-	_____
5. endo-	_____
6. exo-	_____
7. hyper-	_____
8. hypo-	_____
9. peri-	_____
10. pro-	_____
11. re-	_____
12. retro-	_____
13. sub-	_____
14. trans-	_____

Answers to Review

Combining Forms

1. gland
2. joint
3. life
4. cancer (cancerous)
5. heart
6. head
7. cerebrum
8. secrete
9. urinary bladder
10. cell
11. skin
12. electricity
13. brain
14. intestines (often small intestine)
15. red
16. stomach
17. sugar
18. knowledge
19. woman, female
20. blood
21. liver

22. abdomen
23. white
24. kidney
25. nerve
26. tumor
27. eye
28. bone
29. disease
30. mind
31. kidney
32. nose
33. flesh
34. clotting

Suffixes

1. pertaining to
2. pain (condition of)
3. cell
4. cutting out; removal; excision
5. blood condition
6. protein
7. condition
8. pertaining to
9. condition; process
10. inflammation
11. specialist in the study of
12. study of
13. tumor, mass
14. to view (process of viewing)
15. abnormal condition
16. instrument to visually examine
17. process of visual examination

18. state of

19. cutting into; incision

Prefixes

1. no, not

2. self

3. complete, through

4. bad, painful, difficult, abnormal

5. within

6. out, outside

7. excessive, more than normal, too much

8. below, less than normal, under

9. surrounding

10. before

11. back

12. behind

13. below, under

14. across, through

Terminology Checkup

Before you leave this chapter, here are important concepts that you should thoroughly understand. In your own words, write the answers on the lines provided. Confirm your answers on the next page. Check the box next to each item when you know you've "got" it!

1. What is the difference between **endocrine glands** and **exocrine glands**. Give an example of each.

2. What is the difference between a **diagnosis** and a **prognosis**?

3. What is the difference between a **carcinoma** and a **sarcoma**? Give an example of each.

4. What is the difference between **anemia**, **leukemia**, and **leukocytosis**?

5. What is the difference between **laparotomy** and **laparoscopy**?

Answers to Terminology Checkup

1. **Endocrine glands** secrete chemicals called *hormones* *within* the body. Examples are **thyroid, pituitary, and adrenal glands**.

Exocrine glands secrete chemicals to the *outside* of the body through ducts. Examples are **sweat, tear, and salivary glands**.

2. A **diagnosis** is complete knowledge gained after examining and performing tests on a patient. A **prognosis** is a prediction made after the diagnosis. It forecasts and describes the likely *outcome* of an illness.

3. A **carcinoma** is a cancerous tumor arising from lining cells of internal organs. An example is an **adenocarcinoma**.

A **sarcoma** is also a cancerous tumor, but arising from bone, cartilage, muscle, and fat (connective tissues). An example is an **osteosarcoma**.

4. **Anemia** is deficiency of red blood cells (erythrocytes) or deficiency in hemoglobin within red blood cells.

Leukemia is a cancerous condition of high numbers of abnormal white blood cells (leukocytes).

Leukocytosis is only a slight increase in normal white blood cells as a response to infection.

5. A **laparotomy** is a large *incision* of the abdomen to explore or remove organs and tissues.

A **laparoscopy** is *visual examination of the abdomen* using small incisions for insertion of instruments (laparoscope) to view and remove organs and tissues.



CHAPTER 2

Organization of the Body

CHAPTER SECTIONS

Introduction	48
Body Systems	48
Body Cavities	51
Divisions of the Back	54
Planes of the Body	56
Terminology	59
In Person: CT and MRI	65
Exercises and Answers	66
Pronunciation of Terms	73
Practical Applications	76
Picture Show	78
Review	81
Terminology CheckUp	83

CHAPTER OBJECTIVES

- To name the body systems and their functions
- To identify body cavities and specific organs within them
- To list the divisions of the back
- To identify the three planes of the body
- To analyze, pronounce, and spell new terms
- To apply medical terms in real-life situations

Introduction

All the parts of your body are composed of individual units called **cells**. Examples are muscle, nerve, epithelial (skin, and lining of internal organs and cavities), and bone cells.

Similar cells grouped together are **tissues**. Groups of muscle cells are muscle tissue, and groups of epithelial cells are epithelial tissue.

Collections of different tissues working together are **organs**. An organ, such as the stomach, has specialized tissues, such as muscle, epithelial, and nerve, that help the organ function.

Groups of organs working together are the **systems** of the body. The digestive system, for example, includes the mouth, throat (pharynx), esophagus, stomach, and intestines, which bring food into the body, break it down, and deliver it to the bloodstream.

Figure 2-1 reviews the differences between cells, tissues, organs, and systems.

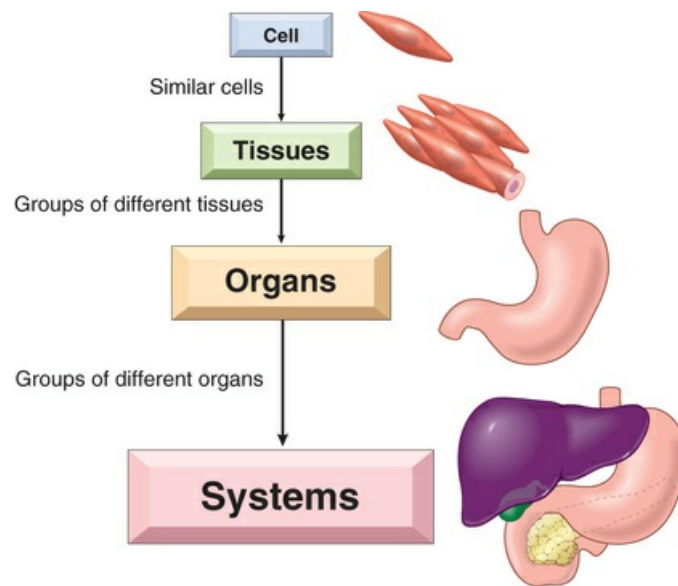


FIGURE 2-1 Cells, tissues, organs, and systems.

Body Systems

There are 11 systems of the body, and each plays an important role in the way the body works.

The **circulatory system** (heart, blood, and blood vessels such as arteries, veins, and capillaries) transports blood (containing all types of blood cells) throughout the body. The **lymphatic system** includes lymph vessels, and nodes that carry a clear fluid called lymph. Lymph contains white blood cells called lymphocytes that fight against disease and play an important role in immunity.

The **digestive system** brings food into the body and breaks it down so that it can enter the bloodstream. Food that cannot be broken down is then removed from the body at the end of the system as waste. Organs in the digestive system include the mouth, stomach, and intestines.

The **endocrine system**, composed of glands, sends chemical messengers called hormones into the blood to act on other glands and organs. Examples of endocrine glands are the thyroid gland, adrenal glands, and pituitary gland.

The **female and male reproductive systems** produce the cells (eggs and sperm) that join to form the embryo, which develops in the uterus of a female. Male (testes) and female (ovaries) sex organs produce hormones as well.

The **musculoskeletal system**, including muscles, bones, joints, and other connective tissues such as cartilage, supports the body and allows it to move.

The **nervous system** carries electrical messages to and from the brain and spinal cord.

The **respiratory system** controls breathing, a process by which air enters and leaves the body. Organs of the respiratory system include the trachea (windpipe), bronchial tubes and lungs.

The **skin and sense organ system**, including the skin and eyes and ears, receives messages from the environment and sends them to the brain. The retina is a layer of sensitive receptor tissue in the back of the eye.

The **urinary system** produces urine and sends it out of the body through the kidneys, ureters, bladder, and urethra.

You can find a table of specific organs/structures and the systems to which they belong on the Evolve site for Chapter 2 in the resources section.

In a separate section of this book, you will find useful information about each body system, with diagrams, terminology, pathology, laboratory tests, and diagnostic and treatment procedures.

At the end of the book, you will find helpful information. Use these resources as you study:

- **Appendix 1, Body Systems**, [page 215](#)
- **Appendix 2, Diagnostic Tests and Procedures**, [page 295](#)
- **Appendix 3, Abbreviations, Acronyms, Symbols, and Eponyms**, [page 317](#)
- **Appendix 4, Quick Drug Reference**, [page 335](#)
- **Appendix 5, Health Careers Information**, [page 339](#)
- **Mini-Dictionary**, [page 349](#)
- **Glossary of Word Parts**, [page 385](#)
- **Glossary of English–Spanish Terms**, [page 403](#)

Body Cavities

Figure 2-2 shows the five body cavities. A body cavity is a space that contains organs. Label the figure in the spaces provided as you read the following paragraphs.

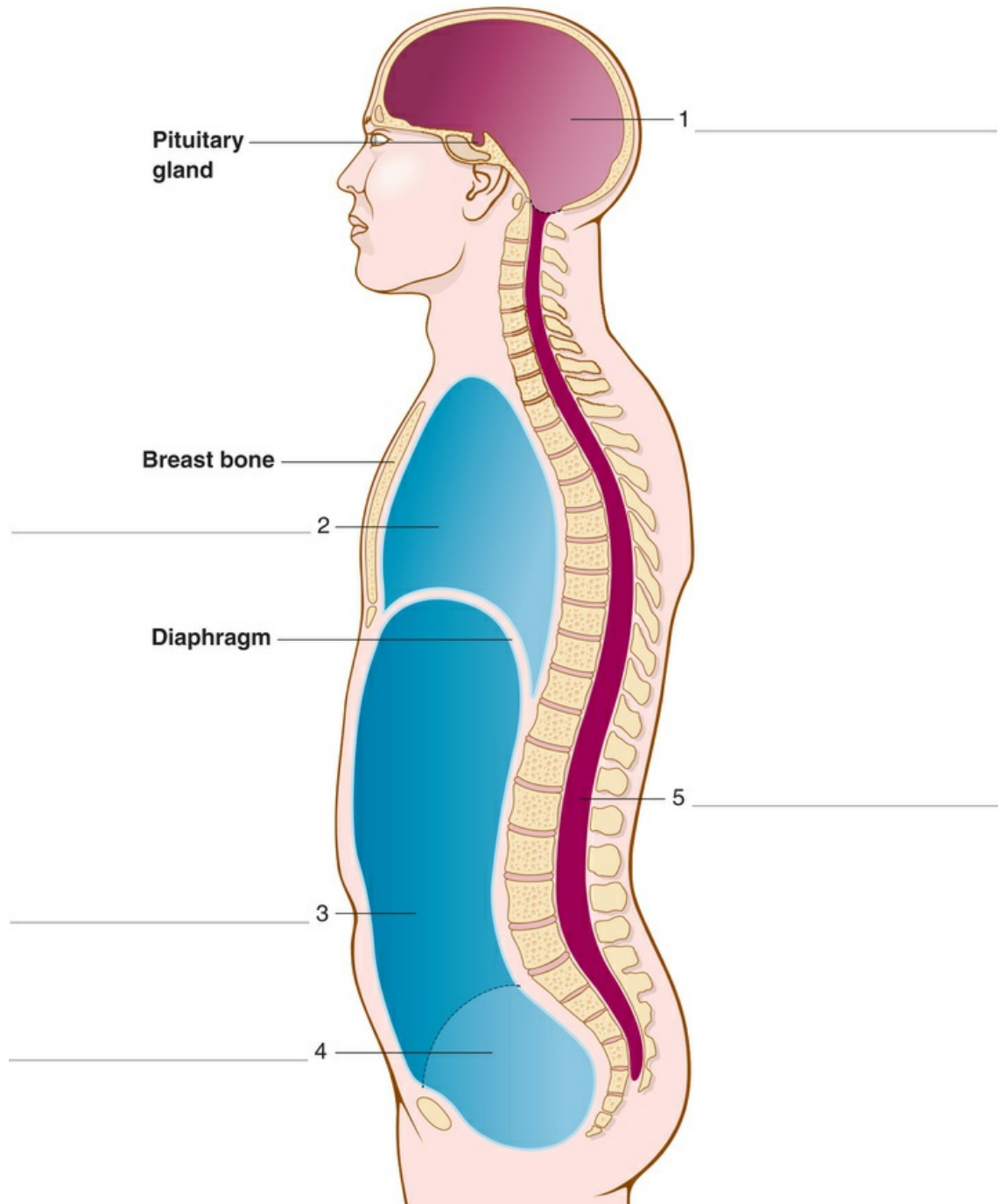


FIGURE 2-2 Body cavities. (Modified from Chabner D-E: *The Language of Medicine*, ed 11, St. Louis, 2017, Elsevier.)

The **cranial cavity** (1) is located in the head and surrounded by the skull (CRANI/O means skull). The cranial cavity contains the brain and other organs, such as the pituitary gland (an endocrine gland located below the brain).

The **thoracic cavity** (2), also known as the chest cavity (THORAC/O means chest), is surrounded by the breastbone and ribs. The lungs, heart, windpipe (trachea), bronchial tubes (leading from the trachea to the lungs), and other organs are in this cavity.

Figure 2-3 shows a front view of the thoracic cavity. The lungs are each surrounded by a double membrane known as the **pleura**. The space between the pleural membranes is the **pleural cavity**. The large area between the lungs (yellow in Figure 2-3) is the **mediastinum**. The heart, esophagus (food tube), trachea, and bronchial tubes are organs within the mediastinum.

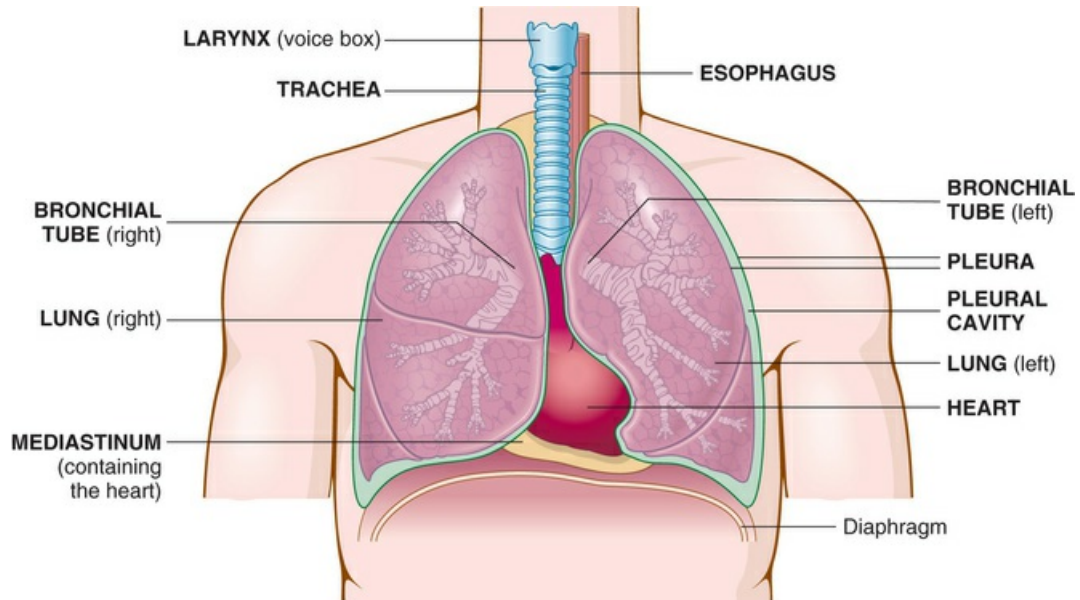


FIGURE 2-3 Thoracic cavity.

In Figure 2-2, the **abdominal cavity** (3) is the space below the thoracic cavity. The **diaphragm** is the muscle that separates the abdominal and thoracic cavities. Organs in the abdomen include the stomach, liver, gallbladder, and small and large intestines.

The organs in the abdomen are covered by a double membrane called the **peritoneum** (Figure 2-4). The peritoneum attaches the abdominal organs to the abdominal muscles and surrounds each organ to hold it in place. 🏠

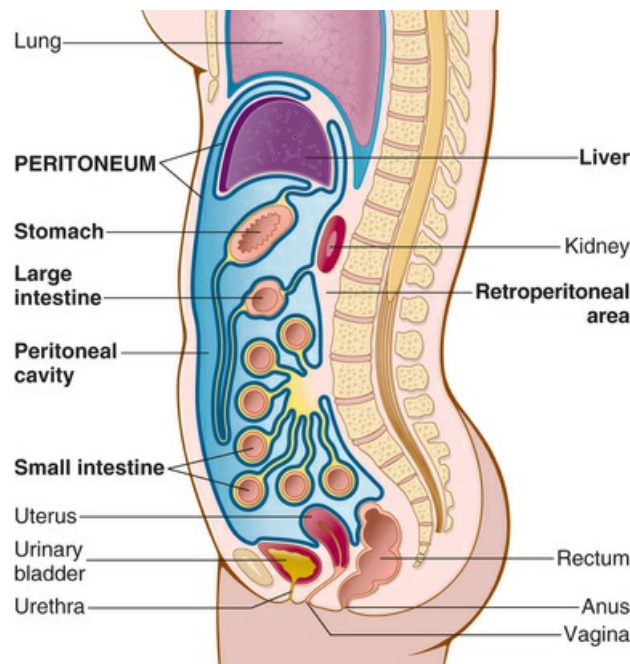


FIGURE 2-4 The **peritoneum** (side view) is a double membrane surrounding the organs (including the liver, stomach, small and large intestines) in the abdomen. The **peritoneal cavity** is the space between the peritoneal membranes. The **retroperitoneal area** is behind the peritoneum. The kidneys are in the retroperitoneal cavity.

Double membranes

You can visualize the way organs are surrounded by a double membrane by imagining your fist pushing deep into a soft balloon. The balloon is then in two layers folded over your fist, just the way the pleura surrounds the lungs and the peritoneum surrounds the abdominal organs. Double wrapping around organs provides protection and cushioning, as well as a site for attachment to muscles. In the event of inflammation or disease of organs or membranes, fluid may collect in the space between the membranes surrounding the organs. This collection of fluid in the pleural cavity is called a **pleural effusion**. A collection of fluid in the peritoneal cavity is called **ascites** (see [page 63](#)).

Turn back to [Figure 2-2](#) and locate the **pelvic cavity** (4), below the abdominal cavity. The pelvic cavity is surrounded by the **pelvis** (bones of the hip). The major organs located within the pelvic cavity are the urinary bladder, ureters (tubes from the kidneys to the bladder), urethra (tube from the bladder to the outside of the body), rectum, and anus, and the uterus (muscular organ that nourishes the developing embryo and fetus) in females.

Label the **spinal cavity** (5) on [Figure 2-2](#). This is the space surrounded by the **spinal column** (backbones). The **spinal cord** is the nervous tissue within the spinal cavity. Nerves enter and leave the spinal cord and carry messages to and from all parts of the body.

As a quick review of the terms presented in this section, match the term with its meaning and write it in the space provided.

Term	Meaning
Abdominal cavity	1. Membrane surrounding the lungs _____
Cranial cavity	2. Space between the lungs, containing the heart _____
Diaphragm	3. Bones of the hip _____
Mediastinum	4. Space containing the liver, gallbladder, and stomach; also called the abdomen _____
Pelvic cavity	5. Space within the backbones, containing the spinal cord _____
Pelvis	6. Membrane surrounding the organs in the abdomen _____
Peritoneum	7. Space within the skull, containing the brain _____
Pleura	8. Space below the abdominal cavity, containing the urinary bladder _____
Spinal cavity	9. Muscle between the thoracic and abdominal cavities _____
Thoracic cavity	10. Entire chest cavity, containing the lungs, heart, trachea, esophagus, and bronchial tubes _____

Divisions of the Back

The **spinal column** is a long row of bones from the neck to the tailbone. Each bone in the spinal column is called a **vertebra (backbone)**. Two or more bones are called **vertebrae**.

A piece of flexible connective tissue, called a **disk (or disc)**, lies between each backbone. The disk, composed of **cartilage**, is a cushion between the bones. If the disk slips or moves out of its place, it can press on the nerves that enter or leave the spinal cord, causing pain. [Figure 2-5](#) shows a side view of vertebrae and disks.

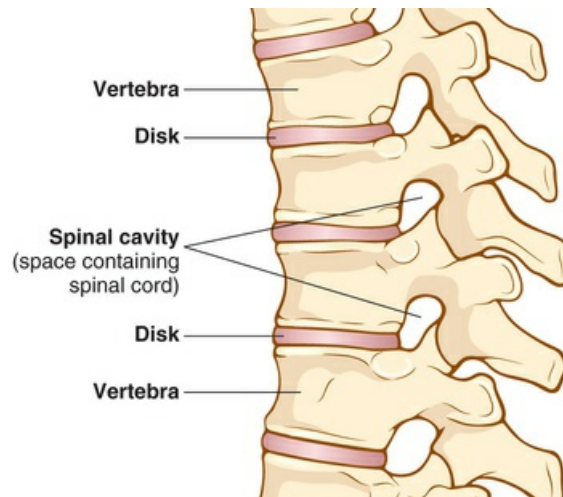


FIGURE 2-5 Vertebrae and disks (discs).

The divisions of the spinal column are pictured in [Figure 2-6](#). Label them according to the following list:

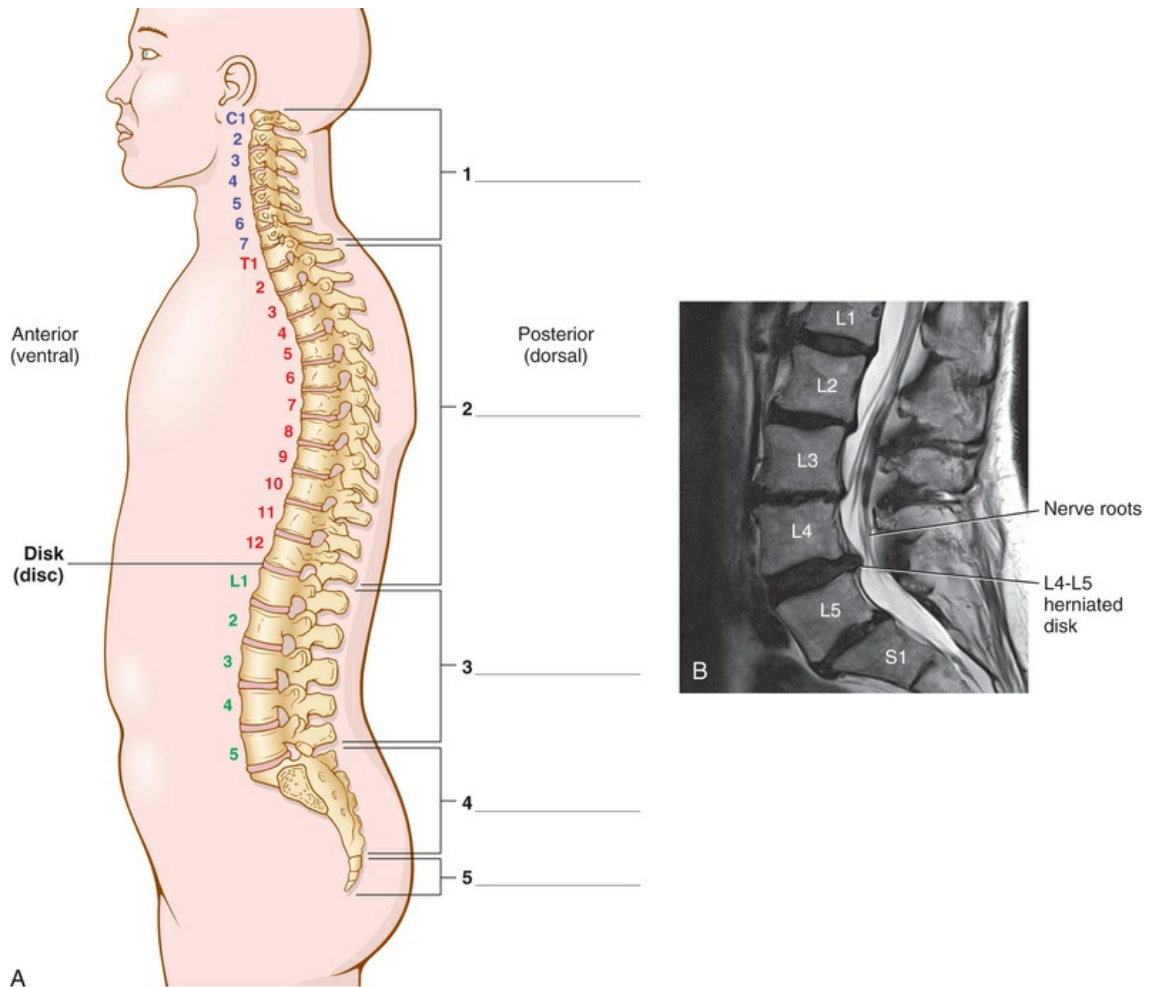


FIGURE 2-6 A, Divisions of the back (spinal column). B, MRI (magnetic resonance imaging) study of a herniated disk at the L4-L5 level of the spinal column. (Modified from Chabner D-E: *The Language of Medicine*, ed 11, St. Louis, 2017, Elsevier.)

Division	Bones	Abbreviation
1. Cervical (neck) region	7 bones	C1-C7
2. Thoracic (chest) region	12 bones	T1-T12
3. Lumbar (loin or waist) region	5 bones	L1-L5
4. Sacral (sacrum or lower back) region	5 fused bones	S1-S5
5. Coccygeal (coccyx or tailbone) region	4 fused bones	

Planes of the Body

A plane is an imaginary flat surface. Organs appear in different relationships to one another according to the plane of the body in which they are viewed.

Figure 2-7 shows three planes of the body. Label them as you read the following descriptions:

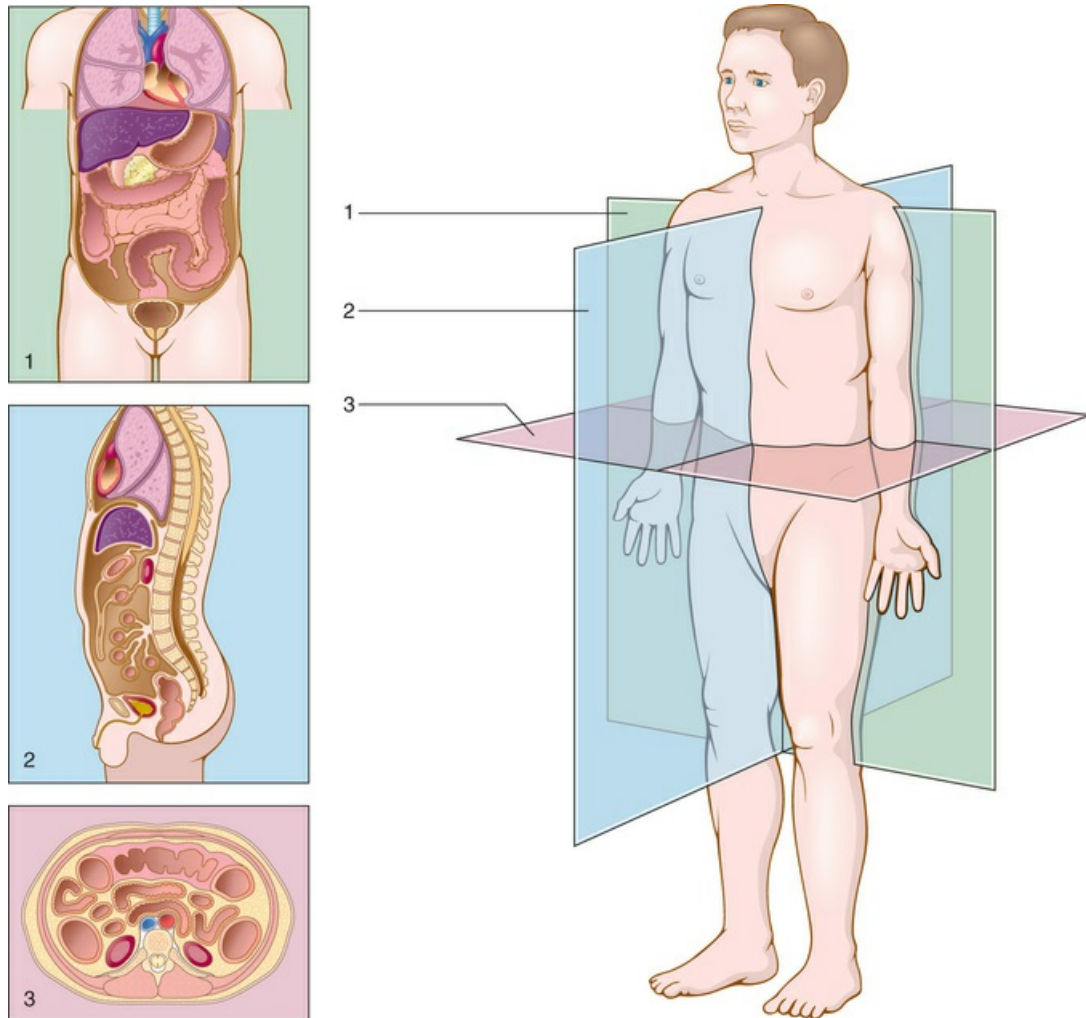


FIGURE 2-7 Planes of the body.

1. Frontal (coronal) plane	A vertical plane that divides the body, or body part such as an organ, into front and back portions. Anatomically, <i>anterior</i> means the front portion and <i>posterior</i> means the back portion.
2. Sagittal (lateral) plane	A vertical plane that divides the body or organ into right and left sides. The midsagittal plane divides the body vertically into right and left halves.
3. Transverse (axial) plane	A horizontal plane that divides the body or organ into upper and lower portions, as in a cross section . (Think of cutting a long loaf of French bread into circular sections.)

Knowing the planes of the body is helpful in looking at imaging studies such as x-ray films (radiographs) and computed tomography (CT) scans. See Figure 2-8.

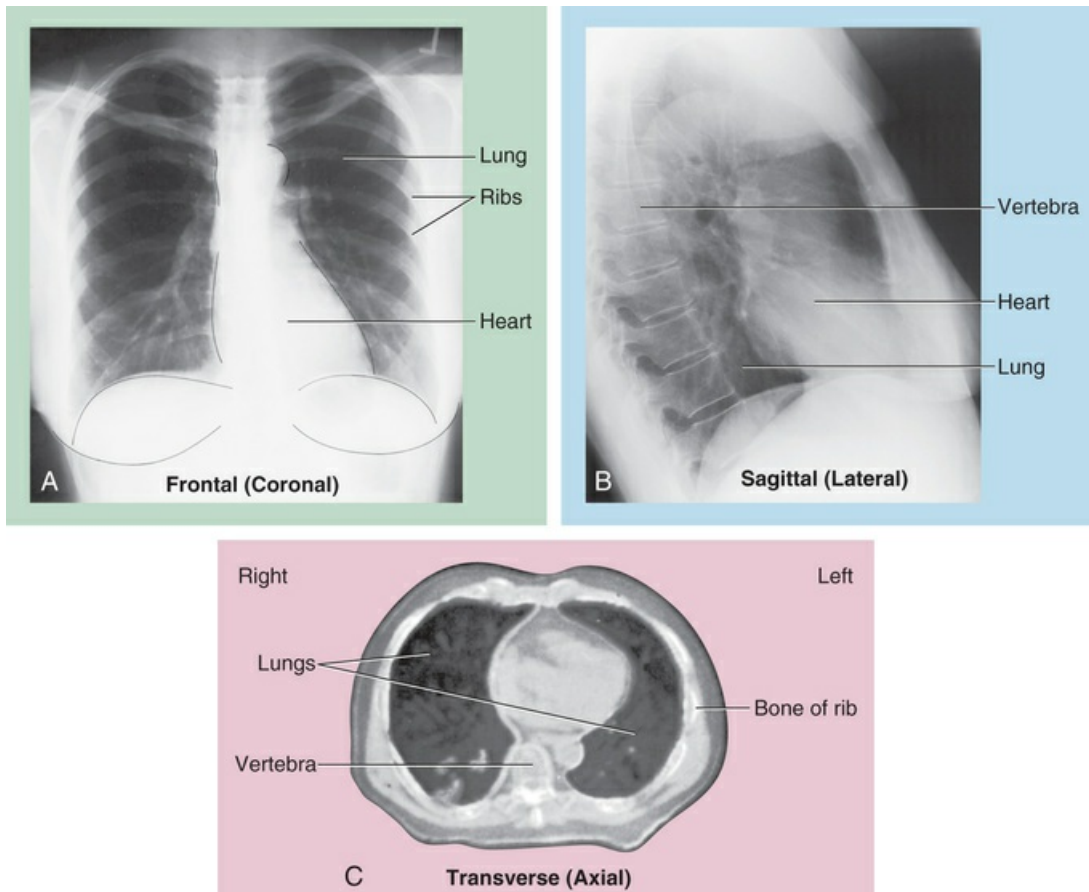


FIGURE 2-8 X-ray views of the chest. A, Frontal (coronal) plane. This radiographic image is an anterior-posterior view of the chest. B, Sagittal (lateral) plane. This is a lateral (side) x-ray view of the chest. C, Transverse (axial) plane. This computed tomography image is a snapshot of structures at a specific level of the body. (A, Modified from Black JM, Matassarini-Jacobs E: *Medical-Surgical Nursing: Clinical Management for Continuity of Care*, ed 5, Philadelphia, 1997, Saunders. B, Modified from Weir J, Abrahams PH: *An Imaging Atlas of Human Anatomy*, ed 2, London, 2000, Mosby. C, From Chabner D-E: *The Language of Medicine*, ed 11, St. Louis, 2017, Elsevier.)

Magnetic resonance imaging (MRI) is another technique for producing images of the body. With MRI, magnetic waves instead of x-rays are used to create the images, which show organs and other structures in specialized detail and in all three planes of the body (Figure 2-9). Figure 2-10 shows a patient undergoing MRI. See *In Person: CT and MRI* on page 65.

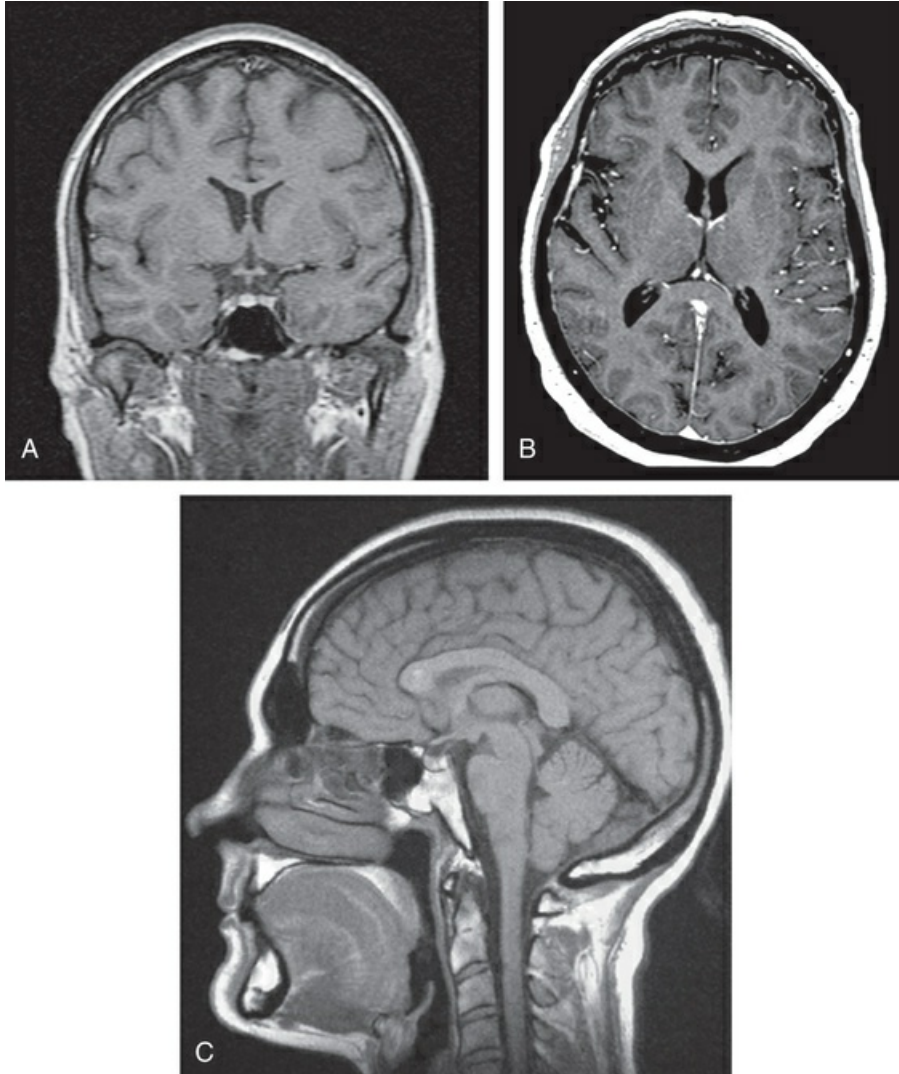


FIGURE 2-9 Magnetic resonance images. Basic views are frontal, transverse, and sagittal. A, Frontal (coronal) plane of the head. B, Transverse (axial) plane of the head. C, Sagittal (lateral) plane showing the head and side of the brain. (A and B, From Frank ED, et al: *Merrill's Atlas of Radiographic Positioning and Procedures*, ed 12, St. Louis, 2012, Elsevier. C, From Reynolds PA, Abraham PH: *McMinn's Interactive Clinical Anatomy: Head and Neck*, ed 2, London, 2001, Mosby Ltd.)

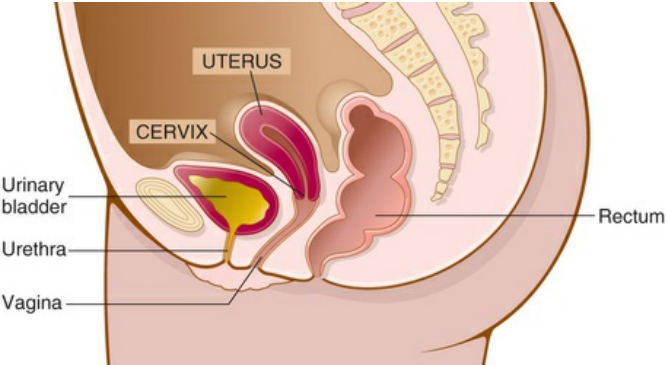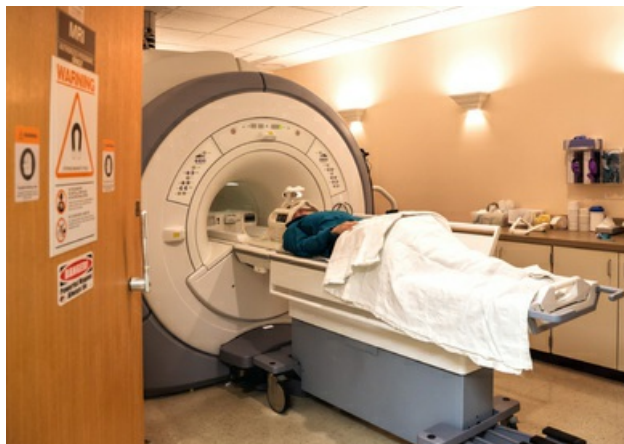
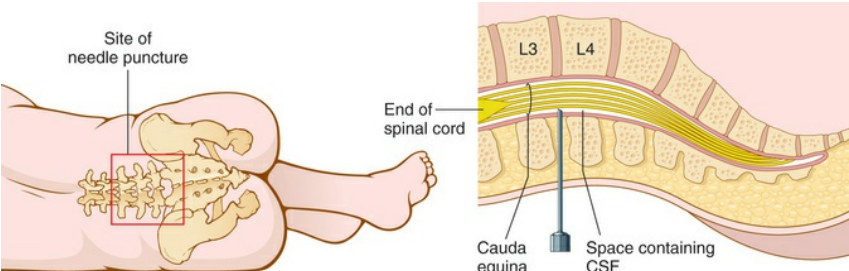



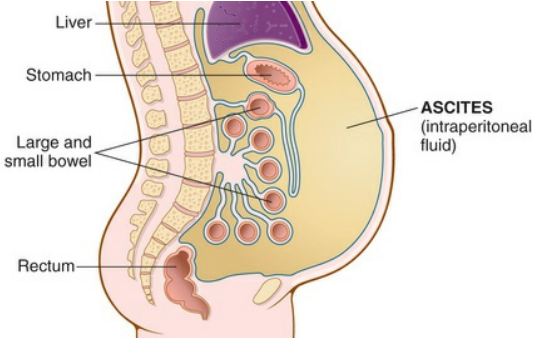
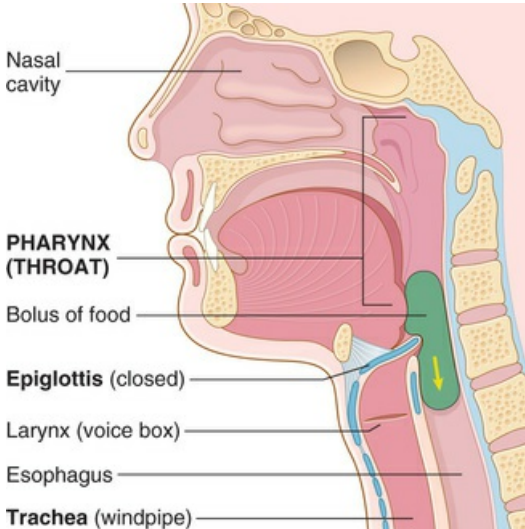
FIGURE 2-10 Patient entering an MRI unit surrounded by a superconducting 1.5-Tesla magnet. Magnetic field changes are picked up by the surrounding machine and processed by a computer to create images. For this examination, the patient must lie very still and have no metal objects on or within the body. (Courtesy GE Medical Systems, Milwaukee, Wisconsin.)

Terminology

Write the meanings of the medical terms on the line provided. Check your answers with the *Mini-Dictionary*, page 349.

Combining Forms

Combining Form	Meaning	Medical Term	Meaning
abdomin/o	abdomen	<u>abdominal</u>	
anter/o	front	<u>anterior</u>	
		<i>The suffix -IOR means pertaining to. See Table 2-1 for additional useful positional and directional terms.</i>	
bronch/o	bronchial tubes (leading from the windpipe to the lungs)	<u>bronchoscopy</u>	
		<i>Pronunciation hint: bron-KOS-ko-pe</i>	
cervic/o	neck of the body or neck (cervix) of the uterus	<u>cervical</u>	
		<i>You must decide from the context of what you are reading whether cervical means pertaining to the neck of the body or pertaining to the uterine cervix (lower portion of the uterus). Figure 2-11 shows the uterus and the cervix.</i>	
		 <p>FIGURE 2-11 The uterus and cervix. The cervix is the lower portion of the uterus opening to the vagina.</p>	
chondr/o	cartilage (connective tissue attached to bones)	<u>chondroma</u>	
		<i>This is a benign tumor.</i>	
		<u>chondrosarcoma</u>	
		<i>This is a malignant tumor. The root SARC, meaning flesh, indicates that the malignant tumor arises from a type of flesh or connective tissue.</i>	
coccyg/o	coccyx, tailbone	<u>coccygeal</u>	
		<i>-EAL means pertaining to.</i>	
crani/o	skull	<u>craniotomy</u>	
epitheli/o	skin, surface tissue	<u>epithelial</u>	
		<i>The term epithelial was first used to describe the surface (EPI- means upon) of the breast nipple (THELI/O actually means nipple correctly, it describes the cells on the outer layer (surface) of the skin as well as the lining of the internal organs that lead to the outside of the body.</i>	
esophag/o	esophagus (tube from the throat to the stomach)	<u>esophageal</u>	
hepat/o	liver	<u>hepatitis</u>	
lapar/o	abdomen	<u>laparoscopy</u>	
laryng/o	larynx (voice box)	<u>laryngeal</u>	
		<i>The larynx (pronounced LAR-inks) is found in the upper part of the trachea. See Figure 2-3, page 51.</i>	
		<u>laryngectomy</u>	
later/o	side	<u>lateral</u>	
lumb/o	loin (waist)	<u>lumbar</u>	
		<i>-AR means pertaining to. A lumbar puncture ("spinal tap") is the placement of a needle within the membranes in the lumbar region, the spinal cord to inject or withdraw fluid. See Figure 2-12.</i>	
		 <p>FIGURE 2-12 Lumbar puncture ("spinal tap"). The patient lies on his side with his knees drawn up to the abdomen and the chin brought down to the chest. This position increases the spaces between the vertebrae. The physician inserts a needle between the third and fourth (or fourth and fifth) lumbar vertebrae, and cerebrospinal fluid (CSF) is withdrawn, or medication can be injected. The end of the spinal cord is where the spinal nerves begin to fan out toward the legs. Performing a lumbar puncture below this level avoids injury to the spinal cord. (Modified from Chabner D-E: <i>The Language of Medicine</i>, ed 11, St. Louis, 2017, Elsevier.)</p>	

lymph/o	lymph (clear fluid in tissue spaces and lymph vessels)	lymphocyte _____ <i>Lymphocytes are white blood cells that fight disease. One type of lymphocyte (B cell) produces disease-fighting proteins called antib</i>
mediastin/o	mediastinum(space between the lungs)	mediastinal _____
pelv/o	pelvis (bones of the hip)	pelvic _____
peritone/o	peritoneum (membrane surrounding the abdominal organs)	peritoneal _____ <i>Peritoneal fluid, produced by the peritoneum, lubricates its surfaces to prevent friction. With inflammation of the peritoneum (peritonitis), fluid may accumulate in the peritoneal cavity. This accumulation of fluid is called ascites (see Figure 2-13).</i>
		
		FIGURE 2-13 Ascites. Abnormal intraperitoneal fluid can result from conditions such as liver disease, peritonitis, and ovarian cancer. (Photo from Lewis SM, Heltkemper MM, Dirksen SR: <i>Medical-Surgical Nursing</i> , ed 9, St. Louis, 2014, Mosby.)
pharyng/o	pharynx (throat)	pharyngeal _____ <i>The pharynx (pronounced FAR-inks) is the common passageway for food from the mouth and air from the nose. See Figure 2-14.</i>
		
		FIGURE 2-14 Pharynx (throat). Notice that the epiglottis (a flap of cartilage) closes over the trachea during swallowing so that the bolus (mass) of food travels down the esophagus and not the trachea. (Modified from Chabner D-E: <i>The Language of Medicine</i> , ed 11, St. Louis, 2017, Elsevier.)
🚩Your Mother Was Right! Don't Talk While You're Eating!		
Talking while eating causes the epiglottis to open, so food can accidentally enter the trachea causing you to choke.		
pleur/o	pleura	pleuritis _____
poster/o	back, behind	posterior _____ <i>See Table 2-1 for useful positional and directional terms, on page 60.</i>
radi/o	x-rays	radiology _____ <i>This medical specialty includes x-ray procedures, ultrasonography (images obtained using sound waves), and nuclear medicine (images obtained using radioactive substances).</i>
sacr/o	sacrum (five fused bones in the lower back)	sacral 🚩 _____

🚩Don't confuse sacr/o and sarc/o

Notice the difference in spelling! Sacr/o always refers to the sacrum, a part of the back, while sarc/o means flesh and is used in **sarcoma**, a malignant tumor of connective or fleshy tissue of the body.

spin/o	spine (backbone)	spinal _____
thorac/o	chest	thoracotomy _____
		thoracic _____
trache/o	trachea (windpipe)	tracheotomy _____ See <i>Figure 2-15</i> .
		<p>The diagram shows a cross-section of the upper respiratory tract. At the top is the thyroid cartilage of the larynx, followed by the cricoid cartilage. Below these are several rings of cartilage that form the trachea. A vertical incision, labeled as a tracheotomy, is shown in the center of the trachea, extending through several rings. The incision is depicted as a purple, elongated shape.</p>
		FIGURE 2-15 Tracheotomy. This procedure may be performed to open the trachea below a blockage from a foreign body or tumor. For an emergency procedure, any available instrument, even the barrel of a ballpoint pen, with the inner part removed, can be used to keep the airway open.
vertebr/o	vertebra (backbone)	vertebral _____

TABLE 2-1

Positional and Directional Terms

Position/Direction	Description	Example
Anterior	Front side	The nose is on the anterior of the head.
Posterior	Back side	The heel is on the posterior of the foot.
Inferior	Below	The liver is inferior to the right lung.
Superior	Above	The stomach is superior to the intestines.
Lateral	Side	The ears are lateral to the mouth.
Medial	Middle	The heart is in the medial area of the chest. (mediastinum)
Distal	Far	The distal end of the thigh bone (femur) is at the knee.
Proximal	Near	The proximal end of thigh bone (femur) is at the hip.
Deep	Away from the surface	The stab wound penetrated deep into the skin.
Superficial	On the surface	Superficial veins can be seen on the surface of the skin.
Supine	Facing up	The patient lies supine during an examination of the abdomen.
Prone	Facing down	The backbones are examined with the patient in a prone position.

In Person: CT and MRI

The following first-person narrative provides a detailed look at two common diagnostic procedures—CT and MRI—from the perspective of the patient. It was written by Catherine Ward, a 77-year-old woman with head and neck cancer.



CT—Computed Tomography

Before an upcoming surgical procedure, I was told that I would need to have a CT scan. The doctors wanted to see if the cancer on my scalp had spread into the bones in my skull. They explained that these images of my head would be in thin “slices,” taken as the CT camera rotated around me.

When I arrived in the room, I saw, to my claustrophobic relief, the CT machine was a large, circular hollow tube about 18 inches wide with a narrow table through the center. The technician explained he would add contrast halfway through the procedure through an intravenous (IV) line.

The table was rolled into the machine to a specific spot where a series of pictures were taken. There were several short periods when I was asked to stay as still as possible and hold my breath. The noise was minimal, just soft whirring and clicking. Halfway through the procedure, the contrast was administered into the IV line. Additional pictures were taken, and the test was completed with a minimum of discomfort, much to my grateful surprise.

MRI—Magnetic Resonance Imaging

Before yet another surgical procedure, my doctors requested an MRI. They explained that the MRI and CT images are similar, but that MRI shows more detail, especially of soft tissue.

The technician asked if I had any metal (such as a pacemaker or surgical screws) inside or on my body. The magnet used in the MRI machine is so strong that it could cause metal objects to shift, disrupting the imaging process or causing damage to tissue in my body.

The MRI machine is a 6-foot-long round tube, open on both ends. Because the body part to be examined was my head, a rubber shield was placed over and very close to my face to hold me in the correct position. I was then rolled inside to the middle of the tube. This was really uncomfortable for me because of my mild claustrophobia. I took deep breaths to relax myself.

I was still taken aback by just how loud it was inside the tube. Even with the earplugs that were provided, the sound of the machine was extremely loud, just like heavy-duty jackhammers. I used a “relax-substitution” method to calm myself, replacing the jarring MRI pounding with more pleasant sounds. I remembered a very loud time as my family and I made our way to Nantucket Island on a ferry for a brief vacation. Now the previously strident and threatening sound of the MRI was replaced in my mind by the welcoming sound of the ferry horn bellowing a happy welcome to the visitors' smiling faces as they came onto the ferry with straw hats, sunscreen, backpacks, and duffel bags. This relaxation method was extremely effective for me.

After taking a series of images, I was then rolled out of the machine for addition of the IV contrast, and the process was repeated.

I am still amazed that the doctors could get such detailed information on what was going on inside my body using these two tests.

Exercises and Answers

Complete these exercises and check your answers. An important part of your success in learning medical terminology is checking your answers carefully with the Answers to Exercises on [page 72](#). Be sure to visit the *Evolve* website, which has additional information, images, games, videos, and interactive activities.

A Match the following systems of the body with their functions.

circulatory

digestive

endocrine

musculoskeletal

nervous

reproductive

respiratory

skin and sense organs

urinary

1. Produces urine and sends it out of the body _____
2. Secretes hormones that are carried by blood to other organs _____
3. Supports the body and helps it move _____
4. Takes food into the body and breaks it down to be absorbed into the bloodstream

5. Transports blood containing nutrients, gases, and other substances through the body

6. Moves air into and out of the body _____
7. Produces the cells that unite to form a new baby _____
8. Receives messages from the environment and sends them to the brain

9. Carries electrical messages to and from the brain and spinal cord

B Select from the following body systems to match the organ or tissue that is found within the system.

cardiovascular

female reproductive

musculoskeletal

skin and sense organs

digestive

lymphatic

nervous

urinary

endocrine

male reproductive

respiratory

1. brain _____

2. cartilage _____

3. kidney _____

4. intestines _____

5. heart _____

6. bronchial tubes _____

7. uterus _____

8. retina _____

9. adrenal glands _____

10. testes _____

C Use the following terms to complete the chart below. Give the name of the cavity and an organ that is contained within the cavity.

abdominal

brain

cranial

heart

lungs

pelvic

spinal

spinal cord

stomach

thoracic

urinary bladder

uterus

	Cavity	Organ
1. Space located within the bones of the hip		
2. Space located within the skull		
3. Space located within the chest		
4. Space located within the abdomen		
5. Space located within the backbones		

D Complete the following sentences using the terms listed below.

abdomen (abdominal cavity)

diaphragm

disk (disc)

mediastinum

pelvis

peritoneum

pleura

spinal column

spinal cord

vertebra

1. The bones of the hip are the _____
2. The muscle separating the chest and the abdomen is the _____
3. The membrane surrounding the organs in the abdomen is the _____
4. The membrane surrounding the lungs is the _____
5. The space between the lungs in the chest is the _____
6. The space that contains organs such as the stomach, liver, gallbladder, and intestines is the _____
7. The backbones are the _____
8. The nerves running down the back form the _____
9. A single backbone is a _____
10. A piece of cartilage in between two backbones is a _____

E Name the five divisions of the spinal column from the neck to the tailbone.

1. c _____
2. t _____
3. l _____
4. s _____
5. c _____

F Match the following terms with their meanings below.

anterior

cartilage

CT scan

frontal (coronal) plane

MRI

posterior

sagittal plane

transverse (axial) plane

1. Pertaining to the back _____
2. Pertaining to the front _____
3. A plane that divides the body into an upper and a lower part _____
4. An imaging study that uses magnetic waves; all three planes of the body are viewed _____
5. A plane that divides the body into right and left parts _____
6. Flexible connective tissue found between bones at joints _____
7. A plane that divides the body into front and back parts _____
8. Series of cross-sectional x-ray images _____

G Give meanings for the following terms.

1. craniotomy _____
2. abdominal _____
3. pelvic _____
4. thoracic _____
5. mediastinal _____

6. epithelial _____
7. tracheotomy _____
8. peritoneal _____
9. hepatitis _____
10. cervical _____
11. lymphocyte _____
12. lateral _____
13. bronchoscopy _____
14. diaphragm _____
15. pleura _____
16. chondrosarcoma _____
17. radiology _____

H Match the following terms with their meanings below.

coccygeal

epithelial

esophageal

laparoscopy

laparotomy

laryngeal

lumbar

pharyngeal

pleuritis

sacral

thoracotomy

vertebral

1. Pertaining to the loin (waist) region below the thoracic vertebrae _____
2. Pertaining to skin (lining or surface) cells _____
3. Incision of the abdomen _____

4. Pertaining to the tube from the throat to stomach _____
5. Pertaining to the voice box _____
6. Inflammation of the membrane surrounding the lungs _____
7. Pertaining to the throat _____
8. Pertaining to the sacrum _____
9. Incision of the chest _____
10. Pertaining to the tailbone _____
11. Visual examination of the abdomen _____
12. Pertaining to backbones _____

I Circle the boldface term that best completes the meaning of the sentences in the following medical vignettes.

1. After her car accident, Cathy had severe neck pain. An MRI study revealed a protruding (**diaphragm, disk, uterus**) between C6 and C7. The doctor asked her to wear a (**sacral, cervical, cranial**) collar for several weeks.
2. Mr. Sellar was a heavy smoker all his adult life. He began coughing and losing weight and became very lethargic (tired). His physician suspected a tumor of the (**musculoskeletal, urinary, respiratory**) system. A chest CT scan showed a (**lung, pharyngeal, spinal**) mass. Dr. Baker performed (**laparoscopy, craniotomy, bronchoscopy**) to biopsy the lesion.
3. Grace had never seen a gynecologist. She had pain in her (**cranial, pelvic, thoracic**) cavity and increasing (**abdominal, vertebral, laryngeal**) girth (size). Dr. Hawk suspected a/an (**esophageal, ovarian, mediastinal**) tumor after palpating (examining by touch) a mass.
4. Mr. Cruise was exposed to asbestos while working in the shipyards during World War II. Now many years later, his doctor encouraged him to stop smoking because of a recently discovered link between asbestos, smoking, and the occurrence of mesothelioma (malignant tumor of cells of the pleura or the membrane surrounding the lungs). A routine chest x-ray film had shown thickening of the (**esophagus, pleura, trachea**) on both sides of Mr. Cruise's (**abdominal, spinal, thoracic**) cavity.
5. Kelly complained of headaches, together with nausea, disturbances of vision, and loss of coordination in her movements. Also, she had generalized weakness and stiffness on one side of her body. Dr. Brown suspected a tumor of the central (**circulatory, digestive, nervous**) system. Treatment involved a (**thoracotomy, craniotomy, laryngectomy**) to remove the lesion (mass) in her brain.
6. Mr. Smith experienced increasing weakness and loss of movement in his right arm and right leg. He saw his family doctor, who immediately referred him to a (**neurologist, cardiologist, rheumatologist**). This specialist examined him and sent him to (**pathology, hematology, radiology**) for x-ray imaging. (Results are shown in [Figure 2-16](#).) This image is a/an (**MRI study, CT scan, AP film**). The imaging clearly

showed a large white region in the brain, indicating an area of dead tissue. Mr. Smith's doctor informed him that he had had a stroke, which is also known as a (pituitary gland tumor, myocardial infarction, CVA or cerebrovascular accident).

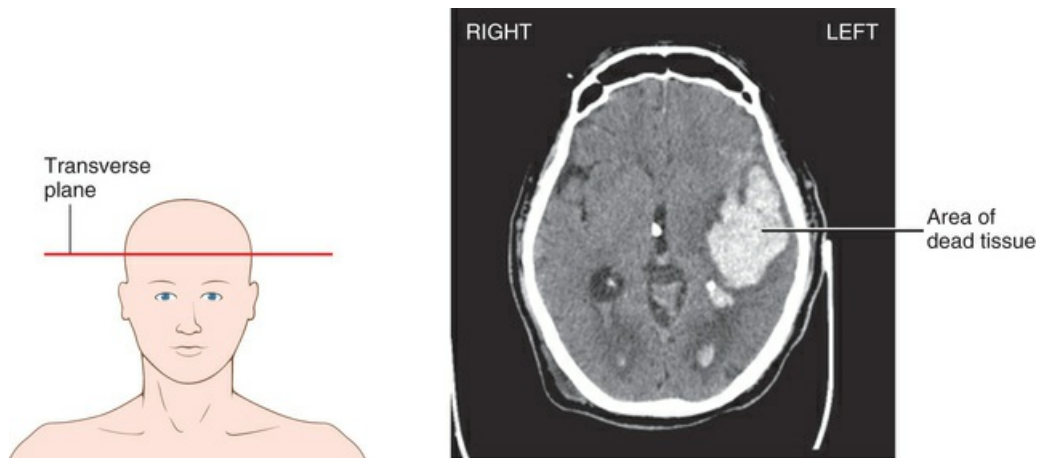


FIGURE 2-16 Cross-sectional x-ray image of Mr. Smith's head.

Answers to Exercises

A

1. urinary
2. endocrine
3. musculoskeletal
4. digestive
5. circulatory
6. respiratory
7. reproductive
8. skin and sense organs
9. nervous

B

1. nervous
2. musculoskeletal
3. urinary
4. digestive
5. cardiovascular
6. respiratory
7. female reproductive

8. skin and sense organs
9. endocrine
10. male reproductive

C

1. pelvic (urinary bladder, uterus)
2. cranial (brain)
3. thoracic (lungs, heart)
4. abdominal (stomach)
5. spinal (spinal cord)

D

1. pelvis
2. diaphragm
3. peritoneum
4. pleura
5. mediastinum
6. abdomen (abdominal cavity)
7. spinal column
8. spinal cord
9. vertebra
10. disk (disc)

E

1. cervical
2. thoracic
3. lumbar
4. sacral
5. coccygeal

F

1. posterior
2. anterior
3. transverse (axial) plane
4. MRI

5. sagittal plane
6. cartilage
7. frontal (coronal) plane
8. CT scan

G

1. incision of the skull
2. pertaining to the abdomen
3. pertaining to the pelvis (bones of the hip)
4. pertaining to the chest
5. pertaining to the mediastinum (the space between the lungs)
6. pertaining to skin (lining or surface) cells
7. incision of the trachea (windpipe)
8. pertaining to the peritoneum (the membrane surrounding the organs in the abdomen)
9. inflammation of the liver
10. pertaining to the neck of the body, or neck (cervix) of the uterus
11. lymph cell (a type of white blood cell)
12. pertaining to the side
13. visual examination of bronchial tubes using an endoscope
14. muscle separating the abdomen from the chest
15. membrane surrounding the lungs
16. malignant tumor (sarcoma) of cartilage
17. study of x-rays

H

1. lumbar
2. epithelial
3. laparotomy
4. esophageal
5. laryngeal
6. pleuritis
7. pharyngeal
8. sacral

9. thoracotomy

10. coccygeal

11. laparoscopy

12. vertebral

I

1. disk, cervical

2. respiratory, lung, bronchoscopy

3. pelvic, abdominal, ovarian

4. pleura, thoracic

5. nervous, craniotomy

6. neurologist, radiology, CT scan, CVA or cerebrovascular accident

■ Pronunciation of Terms

The terms that you have learned in this chapter are presented here with their pronunciations. The capitalized letters in **BOLDFACE** represent the accented syllable. Pronounce each word out loud; then write the meaning in the space provided. Meanings of terms are found in the **Mini-Dictionary**, beginning on page 349, and on the audio section of the Evolve website (<http://evolve.elsevier.com/Chabner/medtermshort>).

Term	Pronunciation	Meaning
abdomen	AB -do-men	
abdominal cavity	ab- DOM -in-al KAV -ih-te	
anterior	an- TE -re-or	
bronchial tubes	BRON -ke-al toobz	
bronchoscopy	bron- KOS -ko-pe	
cartilage	KAR -tih-lij	
cervical	SER -vih-kal	
chondroma	kon- DRO -mah	
chondrosarcoma	kon-dro-sar- KO -mah	
circulatory system	SER -ku-lah-tor-e SIS -tem	
coccygeal	kok-sih- JE -al	
coccyx	KOK -siks	
cranial cavity	KRA -ne-al KAV -ih-te	
craniotomy	kra-ne- OT -o-me	
diaphragm	DI -ah-fram	
digestive system	di- JES -tiv SIS -tem	
disc (disk)	disk	
endocrine system	EN -do-krin SIS -tem	
epithelial	ep-ih- THE -le-al	
esophageal	eh-sof-ah- JE -al	
esophagus	eh- SOF -ah-gus	
female reproductive system	FE -male re-pro- DUK -tiv SIS -tem	
frontal plane	FRUN -tal plane	
hepatitis	hep-ah- TI -tis	
laparoscopy	lap-ah- ROS -ko-pe	
laparotomy	lap-ah- ROT -o-me	
laryngeal	lah- RIN -je-al or lah-rin- JE -al	
laryngectomy	lah-rin- JEK -to-me	
larynx	LAR -inks	
lateral	LAT -er-al	
lumbar	LUM -bar	
lymphocyte	LIMF -o-site	
male reproductive system	male re-pro- DUK -tiv SIS -tem	
mediastinal	me-de-ah- STI -nal	
mediastinum	me-de-ah- STI -num	
musculoskeletal system	mus-ku-lo- SKEL -eh-tal SIS -tem	
nervous system	NER -vus SIS -tem	
ovary	O -vah-re	
pelvic cavity	PEL -vik KAV -ih-te	
pelvis	PEL -vis	
peritoneal	per-ih-to- NE -al	
peritoneum	per-ih-to- NE -um	
pharyngeal	fah- RIN -je-al or fah-rin- JE -al	
pharynx	FAR -inks	
pituitary gland	pih- TOO -ih-teh-re gland	
pleura	PLOO -rah	
pleuritis	ploo- RI -tis	
posterior	pos- TER -e-or	
radiology	ra-de- OL -o-ge	
respiratory system	RES -pir-ah-tor-e SIS -tem	
sacral	SA -kral	
sacrum	SA -krum	
sagittal plane	SAJ -ih-tal plane	
spinal cavity	SPI -nal KAV -ih-te	
spinal column	SPI -nal KOL -um	
spinal cord	SPI -nal kord	
thoracic cavity	tho- RAS -ik KAV -ih-te	
thoracotomy	tho-rah- KOT -o-me	
trachea	TRAY -ke-ah	
tracheotomy	tray-ke- OT -o-me	
transverse plane	trans- VERS plane	
ureter	YOOR -eh-ter or u- RE -ter	

urethra	u-RE-thrah
urinary system	YOOR-in-air-e SIS-tem
uterus	U-ter-us
vertebra	VER-teh-brah
vertebrae	VER-teh-bray
vertebral	VER-teh-bral

■ Practical Applications

Procedures

Select one of the procedures listed below to identify the descriptions in the following paragraphs. Answers are found on [page 77](#).

bronchoscopy

craniotomy

laparoscopy

laparotomy

laryngectomy

thoracotomy

tracheotomy

1. A skin incision is made, and muscle is stripped away from the skull. Four or five burr (or bur) holes are drilled into the skull. The bone between the holes is cut using a craniotome (bone saw). The bone flap is turned down or completely removed. After the bone flap is secured, the membrane surrounding the brain is incised and the brain is exposed. This procedure is a _____.

2. A major surgical incision is made into the chest for diagnostic or therapeutic purposes. One type of incision is a medial sternotomy (the sternum is the breastbone). A straight incision is made from the upper part of the sternum (suprasternal notch) to the lower end of the sternum (xiphoid process). The sternum must be cut with an electric or air-driven saw. The procedure is done to perform a biopsy or to locate sources of bleeding or injury. It often is performed to remove all or a portion of a lung. This procedure is a _____.

3. A needle is inserted below the umbilicus (navel) to inject carbon dioxide (a gas) into the abdomen. The gas distends (expands) the abdomen, permitting better visualization of the organs. A trocar (sharp-pointed instrument used to puncture the wall of a body cavity) within a cannula (tube) is inserted into an incision under the umbilicus. After the cannula is in place in the abdominal cavity, the trocar is removed and an endoscope is inserted through the cannula. The surgeon can then visualize the abdominopelvic cavity and reproductive organs. This procedure is a _____.

4. A flexible, fiberoptic endoscope is inserted through the mouth and down the throat and trachea to assess the tracheobronchial tree for tumors and obstructions, to obtain biopsy specimens, and to remove secretions and foreign bodies. This procedure is a _____.

What's Your Diagnosis?

Case Study

A 67-year-old man with a 2-pack-a-day h/o (history of) smoking and hypertension (high blood pressure) presents to the ED (emergency department) complaining of hemoptysis (coughing up blood), fatigue, back pain on his right side, polyuria (frequent need to urinate), and headaches. The elevated BP (blood pressure), hemoptysis, and headaches require observation in the ED. The patient is admitted, and diabetes is ruled out as a cause of polyuria. A chest x-ray for hemoptysis reveals a RLL (right lower lobe) mass. Needle biopsy confirms malignancy. The patient agrees to have a lobectomy performed. He is counseled on his tobacco use during recovery, and he agrees to begin therapy for tobacco cessation.

Using the information presented in this case study, what's your diagnosis?

- A. Lung cancer—lower lobe
- B. Hemoptysis
- C. Polyuria
- D. Headache
- E. Hypertension

Answers to Practical Applications

Procedures

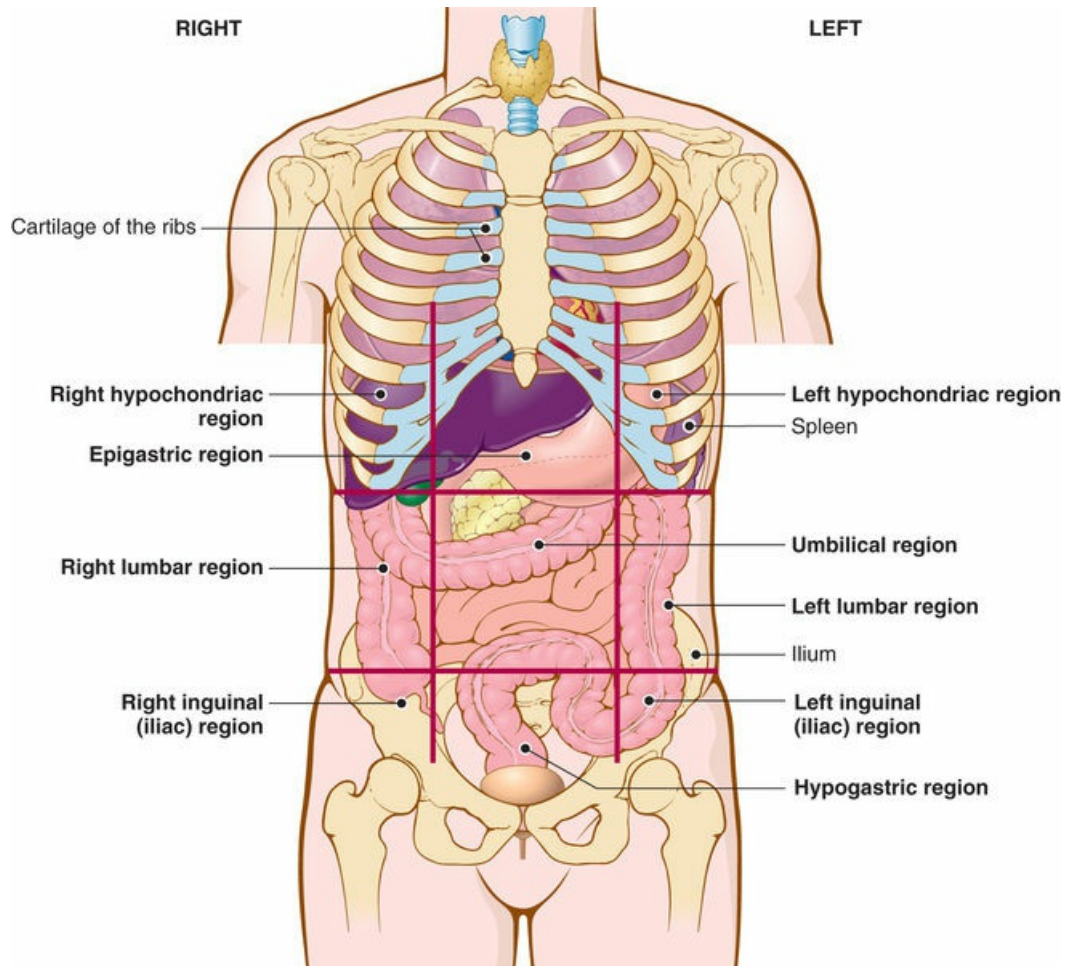
1. craniotomy
2. thoracotomy
3. laparoscopy
4. bronchoscopy

What's Your Diagnosis?

Answer: A. Lung cancer—lower lobe

Picture Show

Answer the questions that follow each image. Answers are found on [page 80](#).



A Abdominopelvic regions. (Modified from Chabner D-E: *The Language of Medicine*, ed 11, St. Louis, 2017, Elsevier.)

1. Which abdominopelvic regions are the middle lateral regions?

- a. epigastric
- b. lumbar (right and left)
- c. hypochondriac (right and left)
- d. inguinal (right and left)

2. Which abdominopelvic region lies above the stomach?

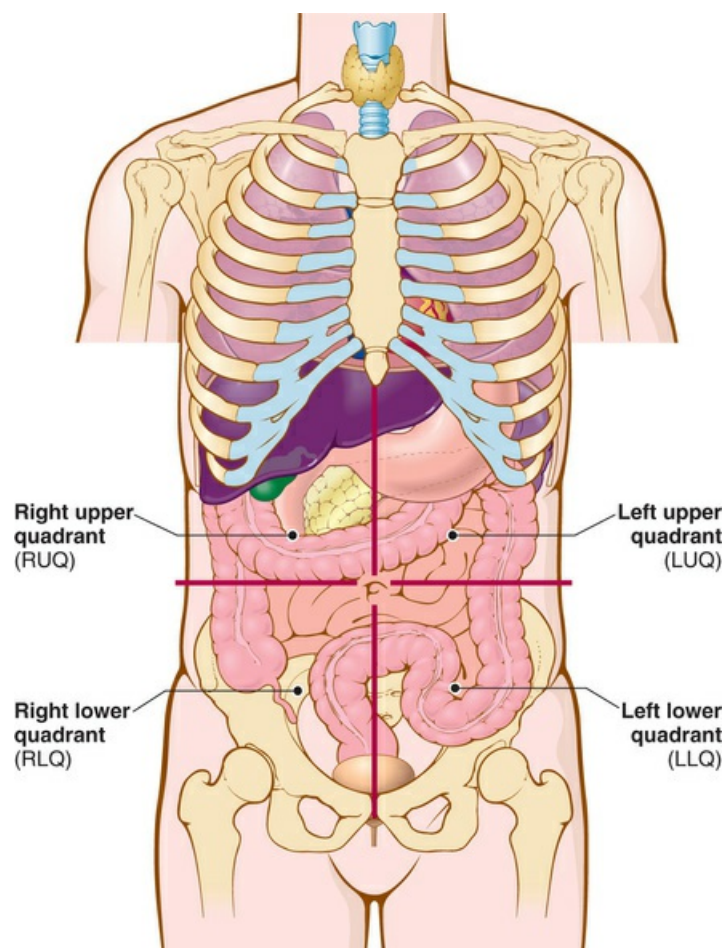
- a. epigastric
- b. inguinal (right and left)
- c. umbilical
- d. hypogastric

3. Which abdominopelvic regions lie under the cartilage of the ribs?

- a. hypogastric
- b. hypochondriac (right and left)
- c. umbilical
- d. inguinal (right and left)

4. Which lateral abdominopelvic regions are in the area of the groin (depression between the thigh and the trunk of the body)?

- a. umbilical
- b. hypochondriac (right and left)
- c. lumbar (right and left)
- d. inguinal (right and left)



B Abdominopelvic quadrants. (Modified from Chabner D-E: *The Language of Medicine*, ed 11, St. Louis, 2017, Elsevier.)

1. A large organ in the RUQ is the:

- a. stomach

b. lung

c. heart

d. liver

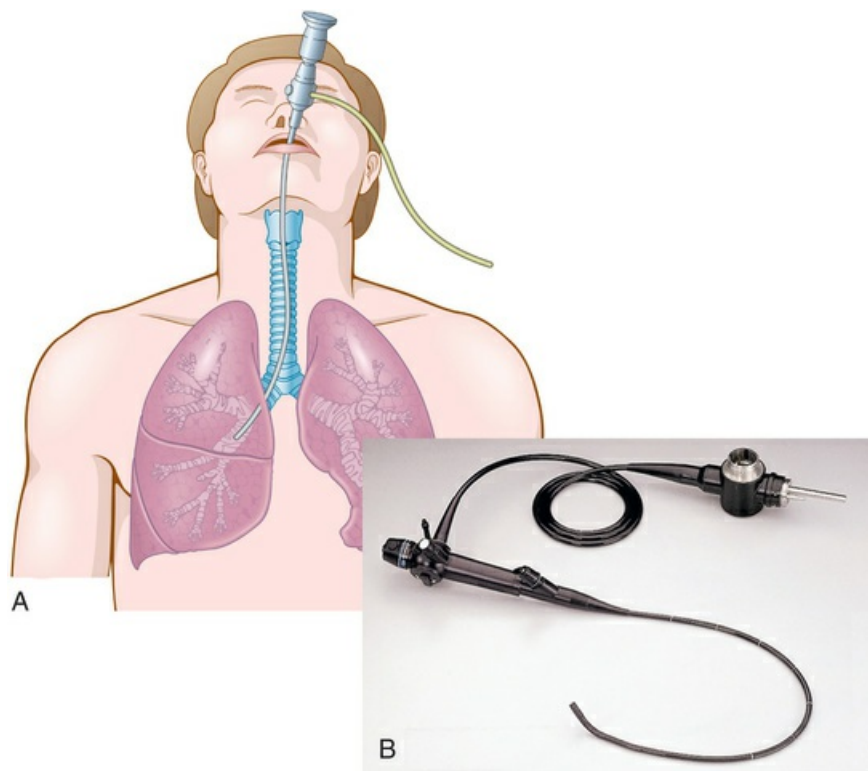
2. The spleen is located in which quadrant?

a. LUQ

b. RUQ

c. RLQ

d. LLQ



C (B, From Mason RJ, et al: *Clinical Respiratory Medicine* ed 4, Philadelphia, 2008, Saunders.)

1. In the procedure shown, an endoscope (pictured in B) is inserted into the mouth to visualize tubes leading to the lungs. This procedure is:

a. laryngoscopy

b. laparoscopy

c. mediastinoscopy

d. esophagoscopy

e. bronchoscopy

2. The instrument is a/an:

- a. mediastinoscope
- b. laparoscope
- c. bronchoscope
- d. esophagoscope
- e. laryngoscope

Answers to Picture Show

A

- 1. b
- 2. a
- 3. b
- 4. d

B

- 1. d
- 2. a

C

- 1. e. This procedure is used for removing material (sputum) from the bronchial tubes, obtaining a biopsy specimen, or removing foreign bodies.
- 2. c. This flexible bronchoscope permits passage of various instruments to obtain specimens from airways and lungs.

Review

Write the meanings of the following combining forms and suffixes in the spaces provided. Check your answers with the Answers to Review on page 82. Meanings for word parts also are listed in the **Glossary of Word Parts** beginning on page 385. **Remember: The key to success is wRite, Repeat, Review!**

Combining Forms

Combining Form	Meaning
1. abdomin/o	_____
2. anter/o	_____
3. bronch/o	_____
4. cervic/o	_____
5. chondr/o	_____
6. coccyg/o	_____
7. crani/o	_____
8. epitheli/o	_____
9. esophag/o	_____
10. hepat/o	_____
11. lapar/o	_____
12. laryng/o	_____
13. later/o	_____
14. lumb/o	_____
15. lymph/o	_____
16. mediastin/o	_____
17. pelv/o	_____
18. peritone/o	_____
19. pharyng/o	_____
20. pleur/o	_____
21. poster/o	_____
22. radi/o	_____
23. sacr/o	_____
24. spin/o	_____
25. thorac/o	_____
26. trache/o	_____
27. vertebr/o	_____

Suffixes

Suffix	Meaning
1. -ac	_____
2. -al	_____
3. -ar	_____
4. -cyte	_____
5. -eal	_____
6. -ectomy	_____
7. -ic	_____
8. -itis	_____
9. -logy	_____
10. -oma	_____
11. -scopy	_____
12. -tomy	_____

Answers to Review

Combining Forms

1. abdomen
2. front
3. bronchial tubes
4. neck

5. cartilage
6. tailbone
7. skull
8. skin
9. esophagus
10. liver
11. abdomen
12. voice box
13. side
14. loin, waist region
15. lymph
16. mediastinum
17. bones of the hip region
18. peritoneum
19. throat
20. pleura
21. back, behind
22. x-rays
23. sacrum
24. backbone
25. chest
26. windpipe
27. backbone

Suffixes

1. pertaining to
2. pertaining to
3. pertaining to
4. cell
5. pertaining to
6. cutting out, removal, excision, resection
7. pertaining to

8. inflammation

9. study of

10. tumor, mass

11. process of visual examination

12. cutting into, incision, to cut into

Terminology Checkup

Before you leave this chapter, here are important concepts that you should thoroughly understand. In your own words, write the answers on the lines provided. Confirm your answers on the next page. Check the box next to each item when you know you've "got" it!

1. Give the locations for the following double membranes: **pleura**, **peritoneum**, and **pericardium**.

2. What is the difference between the following parts of the body: **pharynx**, **larynx**, **trachea**, and **esophagus**?

3. Explain the difference between three planes of the body: **frontal (coronal) plane**, **sagittal (lateral) plane**, and **transverse (axial) plane**.

4. Where is the **mediastinum**? Name organs that are located in this space.

5. What is the difference between the **spinal column** and the **spinal cord**? Name the sections of the spinal column and the spinal cord.

Answers to Terminology Checkup

1. The **pleura** is a double membrane surrounding the lungs.

The **peritoneum** is a double membrane surrounding the abdominal organs.

The **pericardium** is a double membrane surrounding the heart. In a later chapter, you will learn about the *meninges*, three membranes surrounding the brain and spinal cord.

2. The **pharynx** is the **throat** (common passageway for air and food).

The **larynx** is the **voice box** (containing vocal cords and located in the upper portion of the trachea).

The **trachea** is the **windpipe** (tube that carries air into the bronchial tubes and lungs).

The **esophagus** is the **food tube** (behind the trachea and carrying food to the stomach).

3. The **frontal (coronal) plane** divides the body into front and back (anterior/posterior) portions.

The **sagittal (lateral) plane** divides the body into right and left sides.

The **transverse (axial) plane** divides the body into upper and lower portions (cross sections).

Visualizing organs in all three planes is possible with CT and MRI.

4. The **mediastinum** is the central region in the chest. It is the **space between the lungs**. Organs in the mediastinum are the **heart**, **large blood vessels** (aorta and venae cavae), **trachea**, **bronchial tubes**, and **lymph nodes**.

5. The **spinal cord** is a **bundle of nerves** extending from the base of the brain down the back of the body. The **spinal column** is a **series of bones** surrounding the spinal cord. Sections of the spinal cord and the spinal column are **cervical**, **thoracic**, **lumbar**, **sacral**, and **coccygeal**.



CHAPTER 3

Suffixes

CHAPTER SECTIONS

Introduction	86
Combining Forms	86
Suffixes and Terminology	87
In Person: Gallbladder Stones	106
Exercises and Answers	107
Pronunciation of Terms	115
Practical Applications	118
Picture Show	120
Review	124
Terminology CheckUp	127

CHAPTER OBJECTIVES

- To identify and define useful diagnostic and procedural suffixes
- To analyze, spell, and pronounce medical terms that contain diagnostic and procedural suffixes
- To apply medical terms in real-life situations

Introduction

This chapter reviews the suffixes that you have learned in the first two chapters and also introduces new suffixes and medical terms. The combining forms used in the chapter are listed below. Refer to this list as you write the meanings of the terms in the Suffixes and Terminology section that follows (beginning on [page 87](#)). Be faithful about completing all of the Exercises ([page 107](#)), and remember to check your answers on [pages 113 and 114](#)! These exercises will help you spell terms correctly and understand their meanings. Test yourself by completing the Pronunciation of Terms on [pages 115 to 117](#) and Review ([pages 124 and 125](#)).

Remember the 3 “Rs” — wRite, Review, Repeat—and you will succeed!

■ Combining Forms

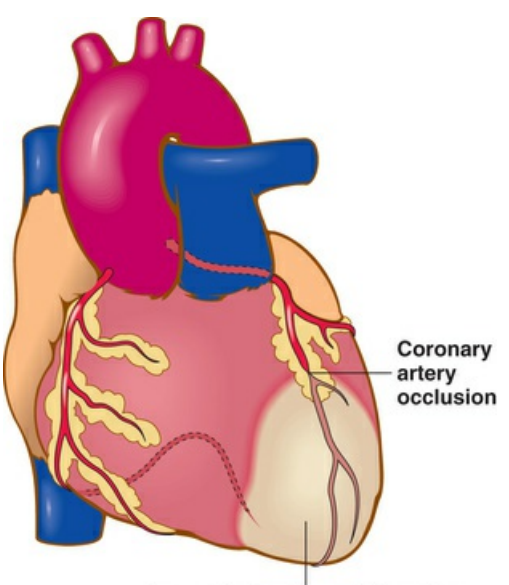
Combining Form	Meaning
aden/o	gland
amni/o	amnion (sac of fluid surrounding the embryo)
angi/o	vessel (usually a blood vessel)
arteri/o	artery
arthr/o	joint
ather/o	plaque (a yellow, fatty material)
axill/o	armpit (underarm)
bronch/o	bronchial tube
bronchi/o	bronchial tube
carcin/o	cancerous
cardi/o	heart
chem/o	drug; also chemical
cholecyst/o	gallbladder
chron/o	time
col/o	colon (large intestine or bowel)
crani/o	skull
cry/o	cold
cyst/o	urinary bladder; also a sac of fluid or a cyst
electr/o	electricity
encephal/o	brain
erythr/o	red
esophag/o	esophagus (tube leading from the throat to the stomach)
hem/o	blood
hemat/o	blood
hepat/o	liver
hyster/o	uterus
inguin/o	groin (area in which the thigh meets the trunk of the body)
isch/o	to hold back
lapar/o	abdomen (abdominal wall)
laryng/o	voice box (larynx)
leuk/o	white
mamm/o	breast (use with -ARY, -GRAPHY, -GRAM, and -PLASTY)
mast/o	breast (use with -ECTOMY and -ITIS)
men/o	menses (menstruation); month
mening/o	meninges (membranes around the brain and spinal cord)
my/o	muscle
myel/o	spinal cord (nervous tissue connected to the brain, located within the spinal column.) MYEL/O can also mean bone marrow (soft, inner part of bones, where blood cells are made)
necr/o	death (of cells)
nephr/o	kidney (use with all suffixes, except -AL and -GRAM; use REN/O with -AL and -GRAM)
neur/o	nerve
oophor/o	ovary
oste/o	bone
ot/o	ear
pelv/o	hip area
peritone/o	peritoneum (membrane surrounding organs in the abdomen)
phleb/o	vein
pneumon/o	lung
pulmon/o	lung
radi/o	x-rays
ren/o	kidney (use with -AL and -GRAM)
rhin/o	nose
salping/o	fallopian (uterine) tube
sarc/o	flesh
septic/o	pertaining to infection
thorac/o	chest
tonsill/o	tonsil
trache/o	windpipe; trachea
ur/o	urine or urea (a waste material); urinary tract
vascul/o	blood vessel

Suffixes and Terminology

Suffixes are divided into two groups: those that describe **diagnoses** and those that describe **procedures**.

Diagnostic Suffixes

Diagnostic suffixes describe disease conditions or their symptoms. Use the list of combining forms in the previous section to write the meaning of each term. You will find it helpful to check the meanings of the terms with the *Mini-Dictionary*, beginning on [page 349](#).

Noun Suffix	Meaning	Terminology	Meaning
-algia	condition of pain, pain	<u>arthralgia</u>	
		<u>otalgia</u>	
		<u>myalgia</u>	
		<u>neuralgia</u>	
-emia	blood condition	<u>leukemia</u>	
		<i>Increase in numbers of leukocytes; cells are malignant (cancerous).</i>	
		<u>septicemia</u>	
		<i>Blood infections result when pathogens enter the blood from a wound.</i>	
Septicemia and bacteremia			
Bacteremia is bacterial invasion of the blood without or without symptoms. Septicemia (sepsis), however, is a more serious bacteremia that moves rapidly and may be life-threatening.			
		<u>ischemia</u>	
		<i>Figure 3-1 illustrates ischemia of heart muscle caused by blockage of a coronary (heart) artery.</i>	
			
		<p>FIGURE 3-1 Ischemia of heart muscle. Blood is held back from an area of the heart muscle by an occlusion (blockage) of a coronary (heart) artery. The muscle then loses its supply of oxygen and nutrition and, if the condition persists, dies. The death of the affected part of the heart muscle is a myocardial infarction (heart attack). (From Chabner D-E: <i>The Language of Medicine</i>, ed 11, St. Louis, 2017, Elsevier.)</p>	
		<u>uremia</u>	
		<i>Uremia occurs when the kidneys fail to function and urea (a waste material) accumulates in the blood.</i>	
-ia	condition	<u>pneumonia</u>	
		<i>The lung is inflamed, causing fluid and material to collect in the air sacs of the lung. See Figure 3-2.</i>	

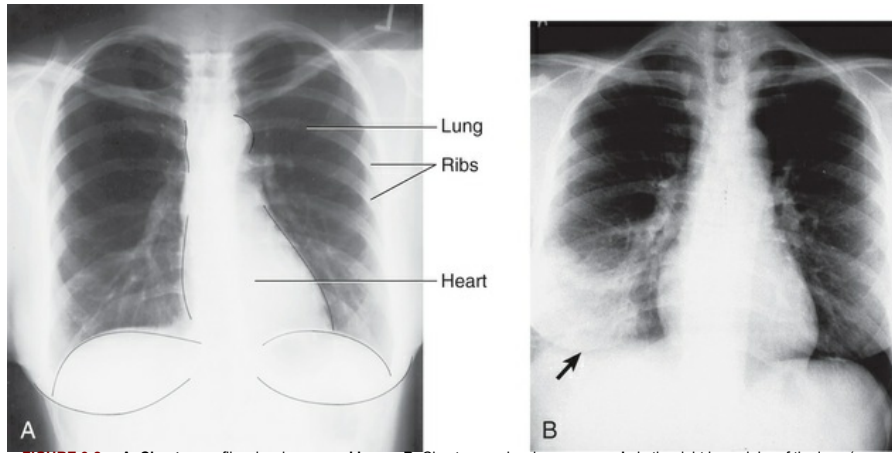


FIGURE 3-2 A, Chest x-ray film showing normal lungs. B, Chest x-ray showing pneumonia in the right lower lobe of the lung (see arrow). (A, From Mason RJ, et al: *Murray and Nadel's Textbook of Respiratory Medicine*, ed 4, Philadelphia, 2005, Saunders. B, From Mettler FA: *Essentials of Radiology*, ed 3, Philadelphia, 2014, Saunders.)

-itis inflammation

bronchitis

Bronchial tubes are inflamed, with hypersecretion of mucus.

esophagitis

laryngitis

meningitis

The meninges are membranes that surround and protect the brain and spinal cord. See Figure 3-3.

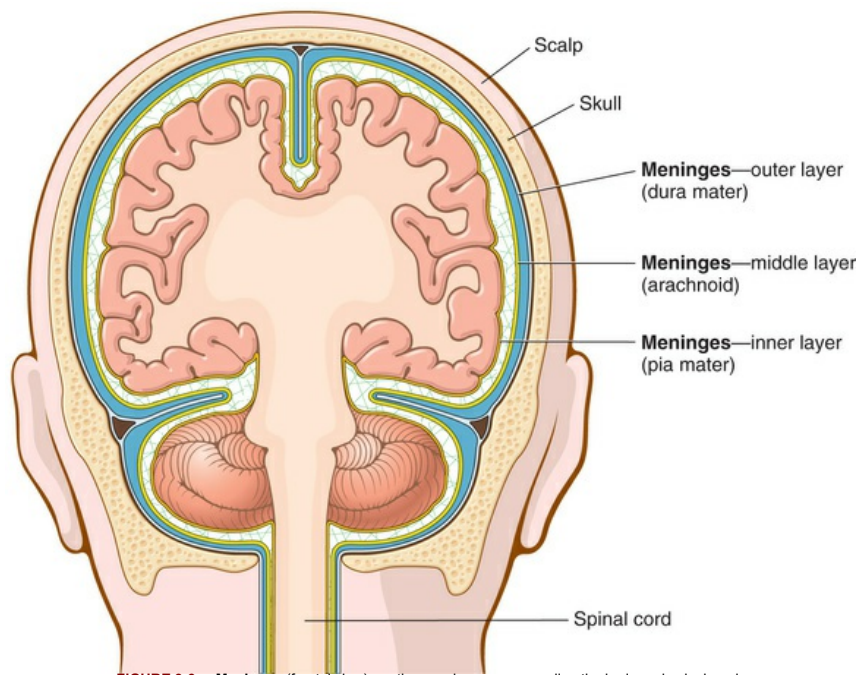


FIGURE 3-3 Meninges (frontal view) are the membranes surrounding the brain and spinal cord.

cystitis

phlebitis

colitis

Table 3-1 lists other common inflammatory conditions with their meanings.

TABLE 3-1
INFLAMMATIONS

appendicitis	Inflammation of the appendix (hangs from the colon in the lower right abdomen)
bursitis	Inflammation of a small sac of fluid (bursa) near a joint
cellulitis	Inflammation of soft tissue under the skin
dermatitis	Inflammation of the skin
endocarditis	Inflammation of the inner lining of the heart (endocardium)
epiglottitis	Inflammation of the epiglottis (cartilage at the upper part of the windpipe)

gastritis	Inflammation of the stomach
hepatitis	Inflammation of the liver
myositis	Inflammation of muscle (MYOS/O means muscle)
nephritis	Inflammation of the kidney
osteomyelitis	Inflammation of bone and bone marrow
otitis	Inflammation of the ear
peritonitis	Inflammation of the peritoneum
pharyngitis	Inflammation of the throat
thrombophlebitis	Inflammation of a vein with formation of clots

-megaly enlargement
cardiomegaly
hepatomegaly

-oma tumor, mass
adenoma
This is a benign (noncancerous) tumor.
adenocarcinoma
Carcinomas are malignant (cancerous) tumors of epithelial (skin or lining) tissue in the body. Glands and the linings of internal organs are composed of epithelial tissue. See Figure 3-4B.

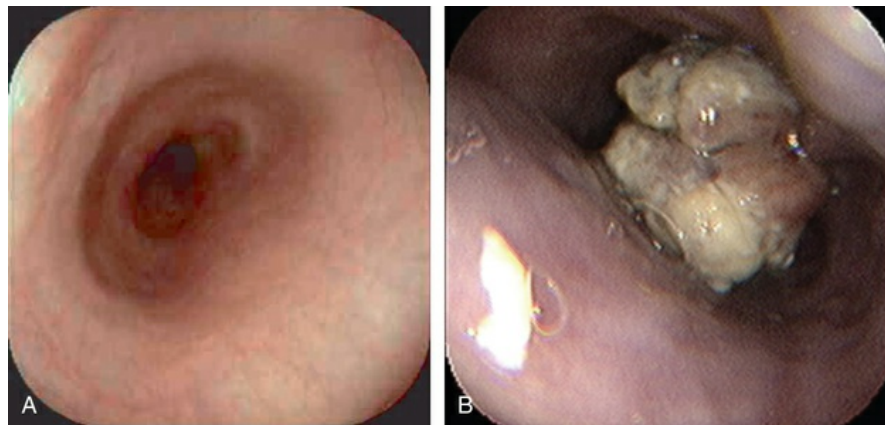


FIGURE 3-4 A, Normal esophagus. B, Esophageal adenocarcinoma. (Courtesy Dr. Erik-Jan Wamsteker: Gastroenterology. In Rakel RE, editor: *Textbook of Family Medicine*, ed 7, Philadelphia, 2007, Saunders.)

myoma
This is a benign tumor. Myomas commonly occur in the uterus and are known as fibroids. See Figure 3-5.

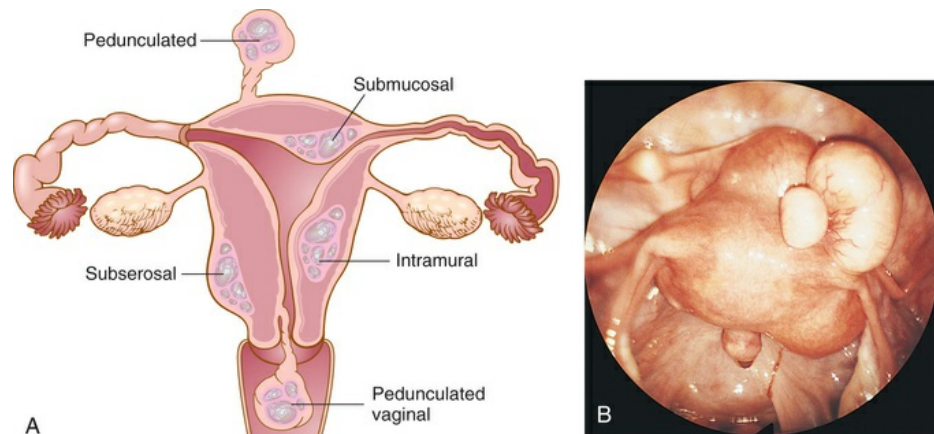


FIGURE 3-5 A, Location of uterine fibroids (leiomyomas). Pedunculated growths protrude on stalks. A subserosal mass lies under the serosal (outermost) layer of the uterus. A submucosal leiomyoma grows under the mucosal (innermost) layer. Intramural (mural means wall) masses arise within the muscular uterine wall. B, Multiple myomas viewed laparoscopically. (A, From Damjanov I: *Pathology for the Health-Related Professions*, ed 5, Philadelphia, 2017, Saunders. B, From Hunt RB: *Text and Atlas of Female Infertility Surgery*, ed 3, St. Louis, 1999, Mosby.)

myosarcoma
Sarcomas are malignant tumors of connective (flesh) tissue. Muscle, bone, cartilage, fibrous tissue, and fat are examples of connective tissues. Table 3-2.

Table 3-2
SARCOMAS

chondrosarcoma	Cancer of cartilage tissue (CHONDR/O means cartilage)
fibrosarcoma	Cancer of fibrous tissue (FIBR/O means fibrous tissue)

	leiomyosarcoma	Cancer of visceral (attached to internal organs) muscle (LEIOMY/O means visceral or “smooth” muscle)
	liposarcoma	Cancer of fatty tissue (LIP/O means fat)
	osteogenic sarcoma	Cancer of bone (OSTE/O means bone)
	rhabdomyosarcoma	Cancer of skeletal (attached to bones) muscle (RHABDOMY/O means skeletal muscle)
	myeloma	MYEL/O means bone marrow in this term. Also called multiple myeloma , this is a malignant tumor of cells in the bone marrow. See Table names of other malignant tumors that do not contain the combining forms CARCIN/O and SARC/O .

Table 3-3
MALIGNANT TUMORS WHOSE NAMES DO NOT CONTAIN THE COMBINING FORMS CARCIN/O AND SARC/O

hepatoma	Malignant tumor of the liver (commonly called hepatocellular carcinoma)
lymphoma	Malignant tumor of lymph nodes (previously called lymphosarcoma)
melanoma	Malignant tumor of pigmented (MELAN/O means black) cells in the skin
mesothelioma	Malignant tumor of pleural cells (membrane surrounding the lungs)
multiple myeloma	Malignant tumor of bone marrow cells
thymoma	Malignant tumor of the thymus gland (located in the mediastinum)

-osis	condition, abnormal condition	nephrosis
		necrosis
		erythrocytosis
		leukocytosis

Ischemia may lead to necrosis. Gangrene is type of necrosis.
When -OSIS is used with blood cell words, it means a slight increase in number of cells.

Leukocytosis versus leukemia

Leukocytosis—slight increase in normal white blood cells (WBCs)—is the body’s response to bacterial infection. **Leukemia** is a malignant condition marked by a dramatic increase in cancerous WBCs.

-pathy	disease condition	encephalopathy
		cardiomyopathy
		nephropathy
		retinopathy

Pronunciation is en-sef-ah-LOP-ah-the.
Pronunciation is kar-de-o-mi-OP-ah-the.
Pronunciation is neh-FROP-ah-the. Table 3-4 lists other disease conditions.

Table 3-4
DISEASE CONDITIONS (-PATHIES)

adenopathy	Disease condition of lymph nodes (“glands”); lymphadenopathy
adrenopathy	Disease condition of the adrenal glands
hepatopathy	Disease condition of the liver
lymphadenopathy	Disease condition of the lymph nodes (previously called glands)
myopathy	Disease condition of muscles
neuropathy	Disease condition of nerves
osteopathy	Disease condition of bones
retinopathy	Disease condition of the retina of the eye

Cardiomyopathy and myocardial infarction (MI)

Cardiomyopathy is chronic (ongoing) disease of heart muscle with inflammation and weakness. A **myocardial infarction (MI)** is an acute (sudden) condition involving an area of heart muscle that has died as a result of ischemia. An MI is a heart attack.

-rrhea	flow, discharge	rhinorrhea
		menorrhea
-rrhage or -rrhagia	excessive discharge of blood	hemorrhage
		menorrhagia

Normal menstrual flow.
Excessive bleeding during menstruation.

Menorrhea and menorrhagia

Menorrhea is the normal discharge of blood and tissue from the lining of the uterus. **Menorrhagia** is abnormally heavy or long menstrual periods. Chronic menorrhagia can result in anemia. Menorrhagia is a common complication of uterine myomas (fibroids).

-sclerosis	hardening	arteriosclerosis
------------	-----------	------------------

Atherosclerosis is the most common type of arteriosclerosis. A fatty plaque (atheroma) collects on the lining of arteries. See Figure 3-6.

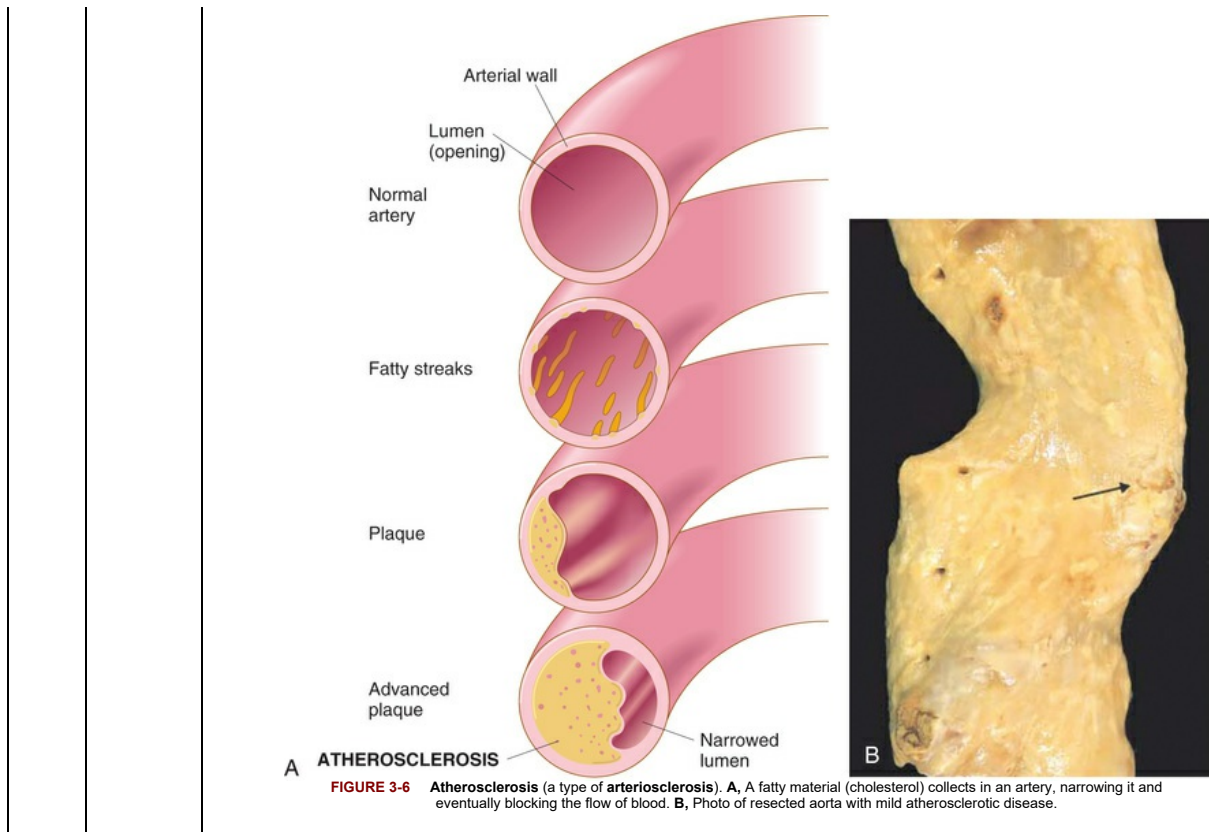


FIGURE 3-6 Atherosclerosis (a type of arteriosclerosis). **A**, A fatty material (cholesterol) collects in an artery, narrowing it and eventually blocking the flow of blood. **B**, Photo of resected aorta with mild atherosclerotic disease.

-uria	condition of urine	hematuria <i>Bleeding into the urinary tract can cause this sign of kidney disease or of disorders of the urinary and genital tracts.</i>
--------------	--------------------	--

Hematuria and uremia

Hematuria is blood in the urine, whereas **uremia** is high levels of urea in the blood.

All of the following **adjective suffixes** mean *pertaining to* and describe a part of the body, process, or condition. Do not worry about which suffix (-al, -eal, or -ic) to use with a particular organ or root. Just identify the suffix as meaning “pertaining to” in each term.

-al or -eal	pertaining to	peritoneal
		inguinal
		renal
		esophageal
		myocardial
<i>Don't forget that a heart attack is a myocardial infarction (MI). An infarction is an area of dead tissue caused by ischemia (a condition in which blood supply is held back from a part of the body).</i>		
-ar	pertaining to	vascular <i>A cerebrovascular accident (CVA) is a stroke.</i>
-ary	pertaining to	axillary
		mammary
		pulmonary
-ic	pertaining to	chronic <i>Chronic conditions occur over a long period of time, as opposed to acute conditions, which are sharp, sudden, and brief.</i>
		pelvic

Procedural Suffixes

The following suffixes describe *procedures* used in patient care.

Suffix	Meaning	Terminology	Meaning
-centesis	surgical puncture to remove fluid	thoracentesis <i>This term is a shortened form of thoracocentesis. See Figure 3-7.</i>	

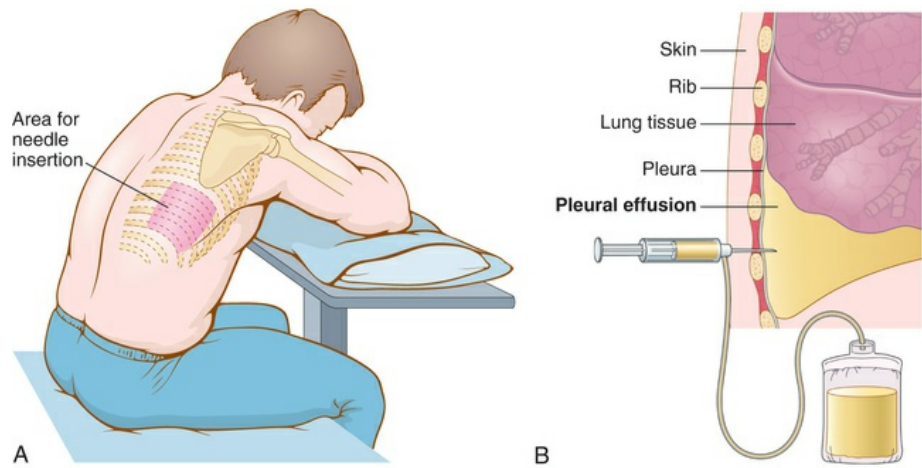


FIGURE 3-7 Technique of thoracentesis. **A**, The patient is sitting in the correct position for the procedure. **B**, The needle is advanced, and the fluid (pleural effusion) is drained.

amniocentesis _____

See [Figure 3-8](#).

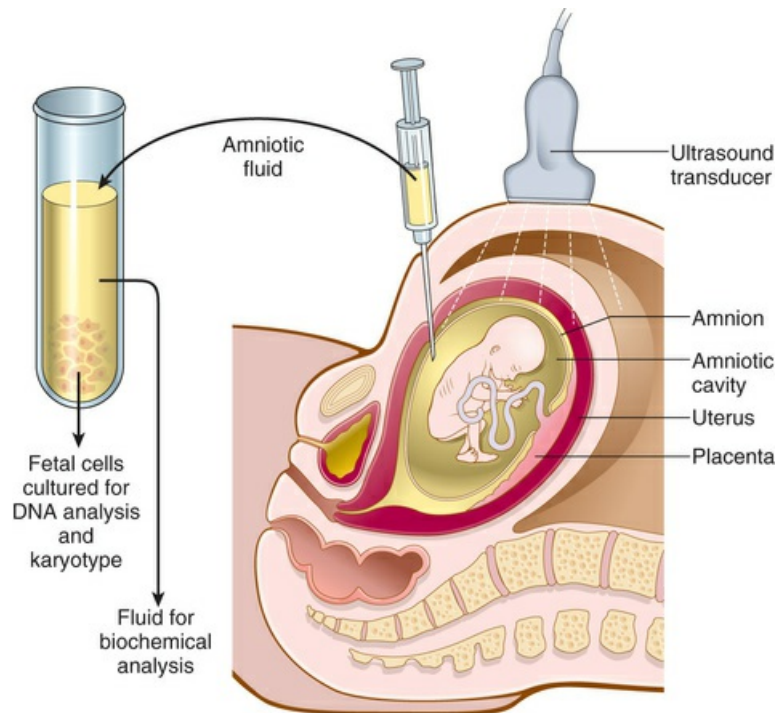


FIGURE 3-8 Amniocentesis. Under ultrasound guidance (imaging based on high-frequency sound waves), the physician inserts a needle through the uterine wall and amnion, into the amniotic cavity. Amniotic fluid, containing fetal cells, is withdrawn and examined for chemicals that indicate fetal defects.

arthrocentesis _____

This procedure is commonly performed on the knee joint to withdraw fluid for diagnosis or treatment.

-ectomy removal,
resection,
excision

tonsillectomy _____

Tonsils and adenoids are lymph tissue in the pharynx (throat). Lymph is composed of white blood cells that fight infection. See [Figure 3-9](#).

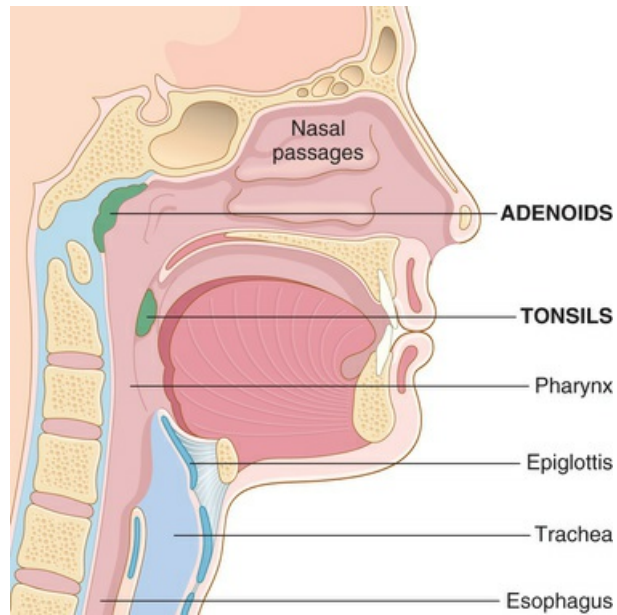


FIGURE 3-9 Tonsils and adenoids. Removal of the tonsils and adenoids is called tonsillectomy and adenoidectomy (T&A).

hysterectomy

In a **total hysterectomy**, the entire uterus, including the cervix, is removed. If only a portion of the uterus is removed, the procedure is a **partial hysterectomy**. See [Figure 3-10](#) on page 98.

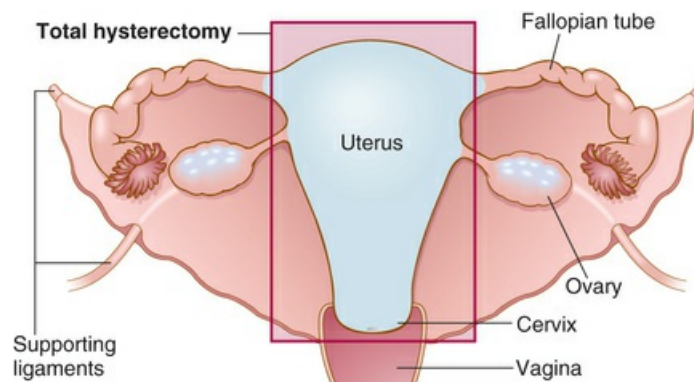


FIGURE 3-10 Total hysterectomy. In a total abdominal hysterectomy (TAH), the uterus is removed through the abdomen. A TAH-BSO is a total abdominal hysterectomy with bilateral salpingectomy and oophorectomy. Laparoscopic hysterectomy can be performed as well.

oophorectomy

[Figure 3-11](#) shows a laparoscopic oophorectomy.

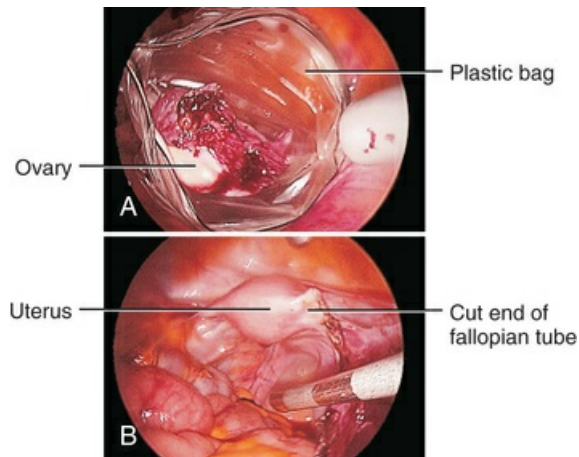


FIGURE 3-11 Laparoscopic oophorectomy. **A**, Notice the ovary within a plastic bag. The bag was inserted through the laparoscope and then opened, and the ovary was placed inside. **B**, Both are extracted through the laparoscope, leaving the uterus and the cut end of the fallopian tube. (A and B, Courtesy Dr. A.K. Goodman, Massachusetts General Hospital, Boston, Massachusetts.)

salpingectomy
 cholecystectomy
 See [Figure 3-12](#). Laparoscopic cholecystectomy is performed whenever possible, instead of an open (more invasive) procedure. See **In Person: Gallbladder Stones** on page 106.

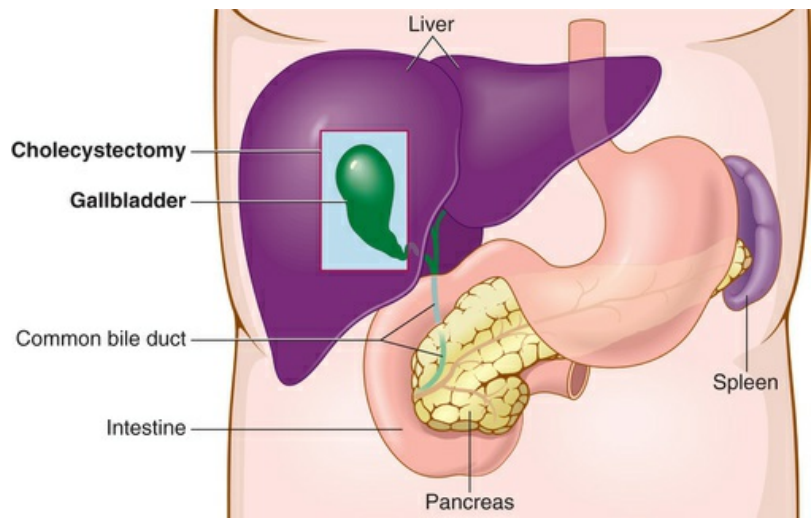


FIGURE 3-12 Cholecystectomy. The liver is lifted up to show the gallbladder underneath. The pancreas is a long, thin gland located behind and to the left of the stomach, toward the spleen. The common bile duct carries bile from the liver and gallbladder to the intestine. After cholecystectomy, the liver continues to produce bile and release it, via the common bile duct, into the intestine.

mastectomy
 Table 3-5 lists additional resection procedures.

Table 3-5
RESECTIONS

adenectomy	Excision of a gland
adenoidectomy	Excision of the adenoids
appendectomy	Excision of the appendix
colectomy	Excision of the colon
gastrectomy	Excision of the stomach
laminectomy	Excision of a piece of backbone (lamina) to relieve pressure on nerves from a (herniating) d
myomectomy	Excision of a muscle tumor (commonly a fibroid of the uterus)
pneumonectomy	Excision of lung tissue: total pneumonectomy (an entire lung) or lobectomy (a single lobe)
prostatectomy	Excision of the prostate gland
splenectomy	Excision of the spleen

-gram record

myelogram
 MYEL/O means spinal cord in this term. Contrast material is injected into the membranes around the spinal cord (by lumbar puncture), and the pictures are taken of the spinal cord. This procedure is performed less frequently now that MRI is available.

mammogram
 See [Figure 3-13](#).

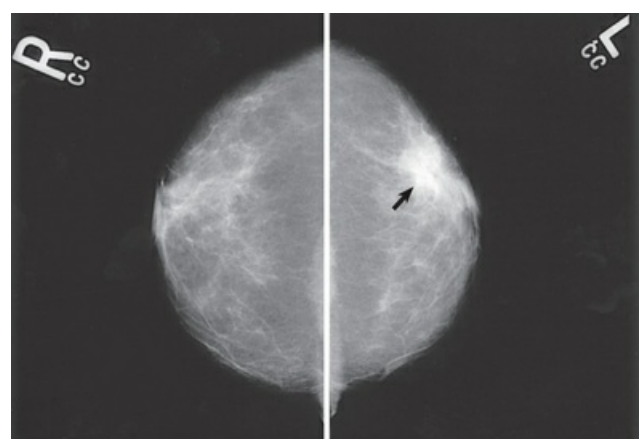


FIGURE 3-13 Mammograms from a 63-year-old woman. The right breast is normal, and the left breast contains a carcinoma (breast cancer) (arrow). (From Frank ED, et al: *Merrill's Atlas of Radiographic Positions and Radiologic Procedures*, ed 11, vol 2, St. Louis, 2007, Mosby.)

-graphy process of recording

electroencephalography _____

mammography _____

Tomosynthesis is a new mammographic technique that shows clearer and more detailed images. See Figure 3-14, A and B.

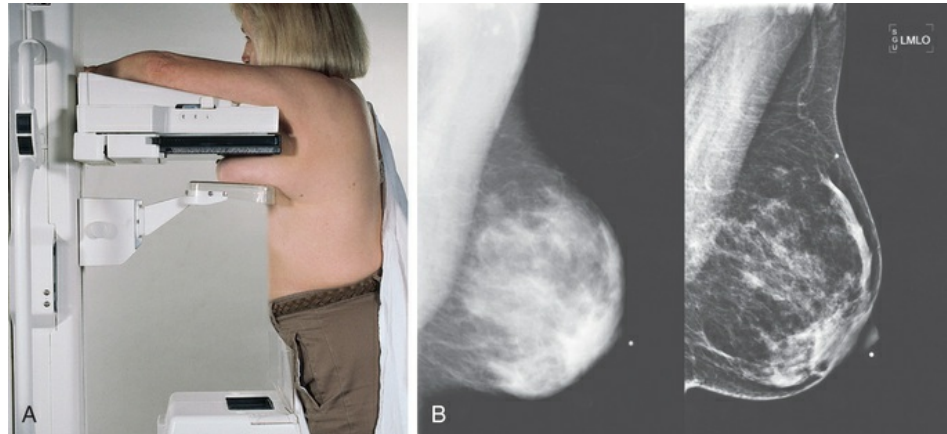


FIGURE 3-14 A, Mammography. The breast is compressed, and x-ray images, craniocaudal (top to bottom) and lateral, are taken. **B,** Image on the left is a mammogram and the image on the right is the same anatomy viewed by digital mammography **tomosynthesis.** (A from Frank ED, et al: *Merrill's Atlas of Radiographic Positions and Radiologic Procedures*, ed 11, St. Louis, 2007, Mosby. B from Klatt E: *Robbins and Coltran Atlas of Pathology*, ed 2, Philadelphia, 2010, Saunders.)

angiography _____

Contrast material (such as iodine) is injected into an artery or vein, and x-ray images are taken.

-lysis separation, breakdown, destruction

dialysis _____

*The root (LYS, meaning to loosen) in this term is embedded in the suffix (-LYSIS). **Hemodialysis** is the removal of blood for passage through (means through or complete) a kidney machine to filter out waste materials, such as urea. Another form of dialysis is **peritoneal dialysis.** A spe is inserted into the peritoneal cavity through a tube in the abdomen. The wastes seep into the fluid from the blood during a period of time. The fl wastes are then drained from the peritoneal cavity. See Figure 3-15.*

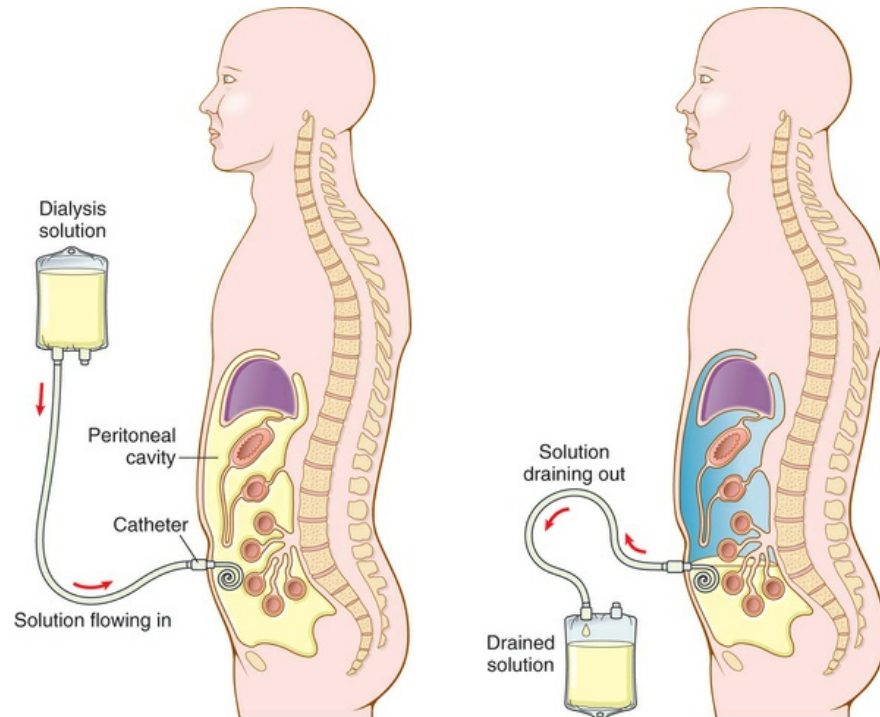


FIGURE 3-15 Peritoneal dialysis. This procedure (or the alternative method of hemodialysis) is necessary when the kidneys are not functioning to remove waste materials (such as urea) from the blood. Without dialysis or kidney transplantation, uremia can result. (From Chabner D-E: *The Language of Medicine*, ed 11, St. Louis, 2017, Elsevier.)

-plasty surgical repair, or surgical correction

mammoplasty _____

rhinoplasty _____

angioplasty _____

*Balloon angioplasty is performed on narrowed, blocked coronary arteries that surround the heart. A wire with a collapsed balloon is placed in a artery. Opening of the balloon widens the vessel, allowing more blood to flow through. A **stent** (mesh tube) is placed in the artery to hold it open Figure 3-16.*

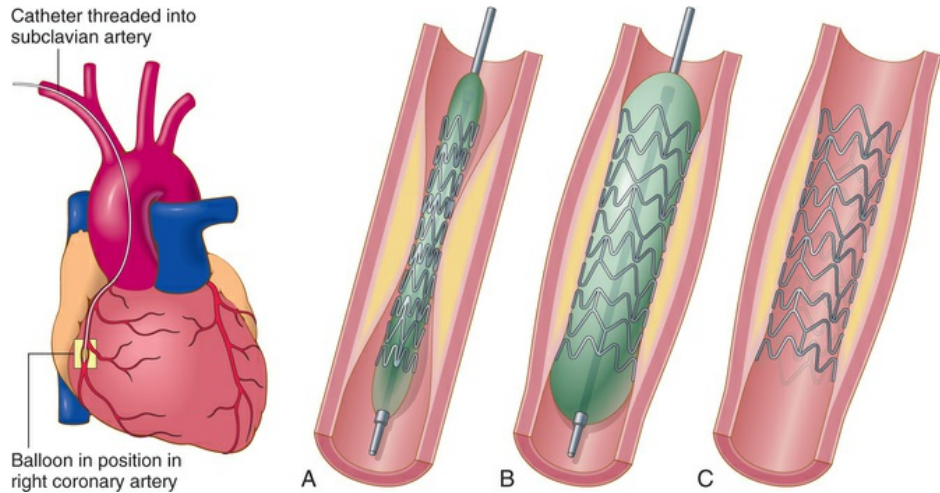


FIGURE 3-16 Angioplasty and placement of an intracoronary artery stent. A, The stent is positioned at the site of the lesion. B, The balloon is inflated, expanding the stent. C, The balloon is then deflated and removed, and the implanted stent is left in place. Coronary artery stents are stainless steel mesh, tubelike devices that help hold arteries open. Drug-eluting stents release chemicals to dissolve plaque.

-scopy process of visual examination

bronchoscopy

laparoscopy

A common weight loss technique is a laparoscopic gastric band procedure. A band is placed around the upper part of the stomach to create a *smu* which reduces the capacity of the stomach and helps decrease appetite.

laryngoscopy

See [Figure 3-17](#).

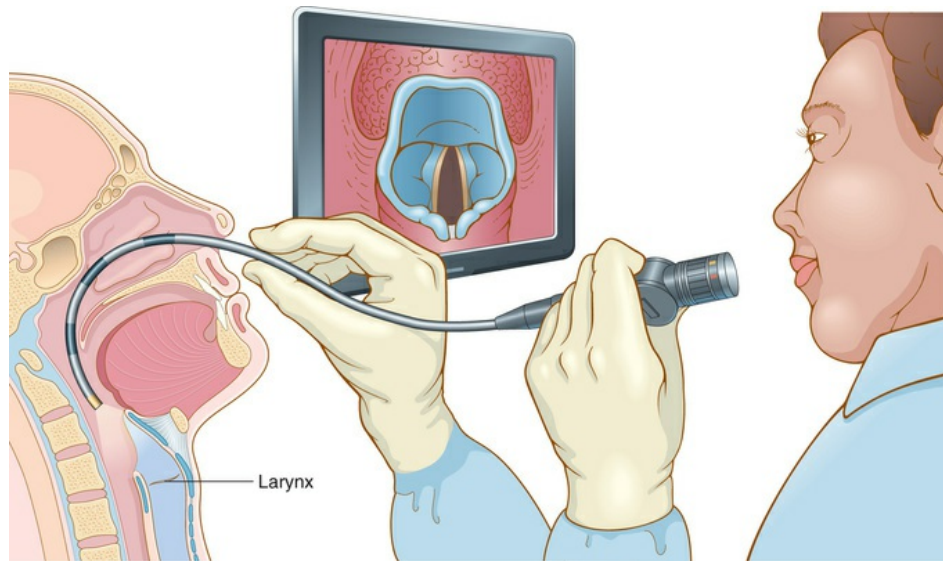


FIGURE 3-17 Laryngoscopy.

-stomy opening

colostomy

A **-STOMY** procedure is the creation of a permanent or semipermanent opening (*stoma*) from an organ to the outside of the body. See [Figure 3-19](#). Images of colostomy care are pictured in [Figure 3-19](#). When two tube-like structures are surgically connected within the body, the new connection is called **anastomosis** (see [Figure 3-20](#)). A **colocolostomy** is an anastomosis, a new connection between two previously unconnected portions of the co

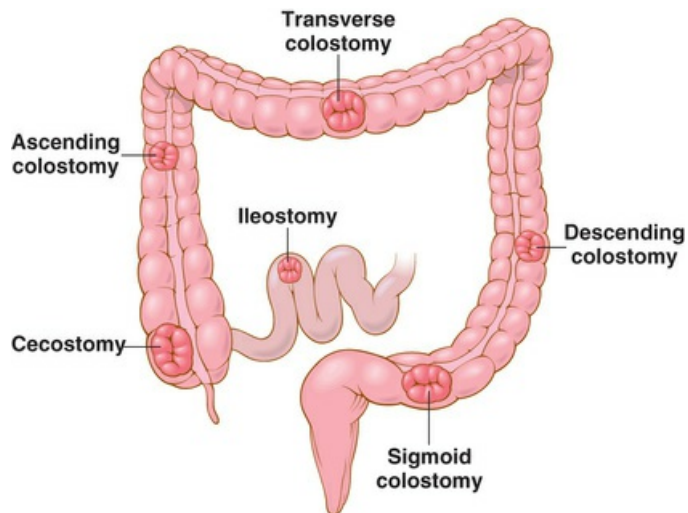


FIGURE 3-18 Locations of stomas in the ileum and colon. (Modified from Chabner D-E: *The Language of Medicine*, ed 11, St. Louis, 2017, Elsevier.)

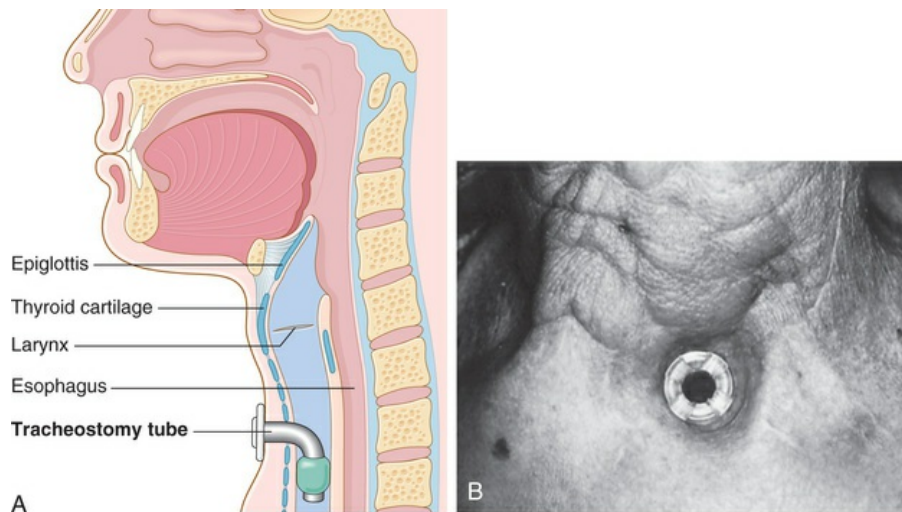


FIGURE 3-21 A, Tracheostomy with tube in place. B, Healed tracheostomy incision after laryngectomy. (B, From Black JM, Hawks JH, Keene AM: *Medical-Surgical Nursing: Clinical Management for Positive Outcomes*, ed 6, Philadelphia, 2001, Saunders.)

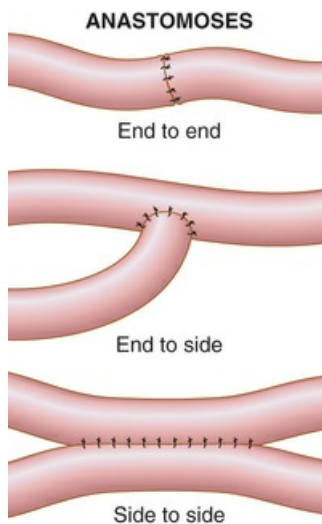


FIGURE 3-20 Anastomoses are new surgical connections between previously unconnected tube-like structures. (Modified from Chabner D-E: *The Language of Medicine*, ed 11, Philadelphia, 2017, Saunders.)

tracheostomy
See Figure 3-21.

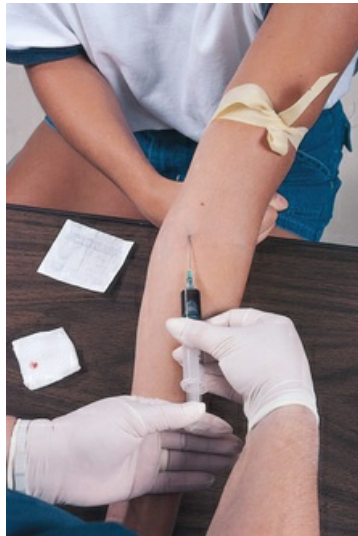

FIGURE 3-22 Phlebotomy. After a vein is entered with a needle inserted through the skin, the plunger of the syringe is slowly pulled out to withdraw blood. (From Bonewit-West K: *Clinical Procedures for Medical Assistants*, ed 6, Philadelphia, 2004, Saunders.)

- therapy	treatment	radiotherapy
		chemotherapy
		cryotherapy

Skin lesions, such as warts, are removed with cryotherapy. Liquid nitrogen or carbon dioxide snow is applied and blistering followed by necrosi:

Radiotherapy versus radiology

Radiotherapy (radiation therapy) is directed by a radiation oncologist, a medical doctor specializing in **treating** cancer using radiation to kill tumor cells. **Radiology** is the specialty of a radiologist, also a medical doctor, who primarily **diagnoses** conditions using x-ray, magnetic wave, and ultrasound technic

-tomy	incision, cutting into	craniotomy
		laparotomy
		phlebotomy See Figure 3-22.

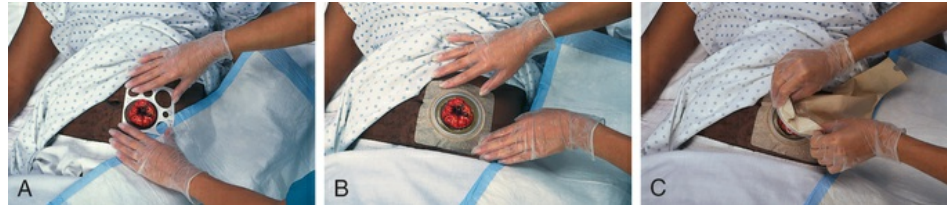

FIGURE 3-19 Colostomy care.

TOMY versus -STOMY

-TOMY indicates a temporary **incision**, as opposed to -STOMY, which is a permanent or semipermanent **opening**.

In Person: Gallbladder Stones

This first-person narrative describes the symptoms and treatment of a 46-year-old woman with gallbladder stones.



Everyone enjoys a little dessert after dinner, but when the ice cream or a creamy tart leads to pain, most would avoid it. I loved sweets, and despite the revenge they took on my waistline, I still would not pass up an ice cream cone—until my gallbladder decided it had had enough. After several late nights spent doubled over in pain, I tried to steer clear of fatty foods but could not resist the temptation of frozen yogurt.

With one hand I pushed my cart through the supermarket; with the other hand I fed myself some delicious low-fat (not non-fat) frozen yogurt. I never dreamed that the attendant at the quick service window actually gave me soft-serve ice cream. Within 10 minutes of eating the questionable yogurt, I broke out into a sweat; a wave of nausea took me, over and a knifelike pain stabbed me in my right upper quadrant. It hurt even more when I pressed my hand on the area in an attempt to brace the pain.

Several months earlier, after a similar painful episode, I had undergone an ultrasound of my gallbladder, and the surgeon then recommended cholecystectomy. The US showed multiple stones in my gallbladder. Most of the stones were just the right size to lodge in the common bile duct and cause blockage of the outflow of bile that occurs after a fatty meal. When I heard the ultrasound results, I swore off all fatty foods.

I just did not imagine that ice cream masquerading as “low-fat yogurt” would be the straw that broke the camel’s back! Soon enough, I abandoned my shopping cart and apologized to the manager of the store for vomiting all over aisle 4. The unrelenting pain did not cease when I vomited—it only intensified. I have no idea how I made it home and into bed, but my husband found me several hours later in a deep sweat. I managed to call my surgeon and arrange for “semiemergent” surgery the next morning.

Dr. Fernandez and his team performed a laparoscopic cholecystectomy and relayed to me as I came out of anesthesia that I no longer had a “bag of marbles” for a gallbladder. I had a gassy, distended feeling in my abdomen over the two weeks after surgery (carbon dioxide gas is injected into the abdomen before surgery to allow space between abdominal organs). I felt “tight as a drum” for the first few days, and then day by day it went away. My four tiny incisions healed just fine, and in about 2 weeks I was feeling back to normal. Now I can eat ice cream to my heart’s content, only suffering the padding on my waistline, not the stabbing pain just above. Without missing a beat, my liver now delivers the bile into my small intestine right after I eat a fatty meal. The bile emulsifies (breaks down) the fat. I just don’t have a storage bag to hold bile in reserve.

I’ve had an appendectomy, my wisdom teeth removed, and now I gave up my gallbladder! How many more “useless” body parts are there to go?

Elizabeth Chabner Thompson is the CEO/founder of BFFL Co, a company devoted to improving the patient experience. She is also a physician, ultra-marathoner, wife, and the mother of four children, ages 13 to 19.

📖 Exercises and Answers

Complete these exercises and check your answers. An important part of your success in learning medical terminology is checking your answers carefully with the Answers to Exercises beginning on page 113. Visit the Evolve website (<http://evolve.elsevier.com/Chabner/medtermshort>) for additional interactive activities and information.

A Give meanings for the following suffixes.

1. -algia _____
2. -emia _____
3. -itis _____
4. -megaly _____
5. -oma _____
6. -pathy _____
7. -rrhea _____
8. -rrhagia _____
9. -sclerosis _____
10. -uria _____

B Give definitions for the following terms:

1. myalgia

2. septicemia _____
3. uremia _____
4. phlebitis

5. cardiomegaly

6. myosarcoma

7. nephrosis

8. encephalopathy

9. rhinorrhea

10. menorrhagia

C Match the following medical terms with their meanings below. Write each term next to its meaning.

adenocarcinoma

cardiomyopathy

esophagitis

hematoma

hepatomegaly

ischemia

leukocytosis

myeloma

otalgia

pneumonia

1. Enlargement of the liver _____

2. Pain in the ear

3. Holding back blood from an organ (depriving it of blood supply) _____

4. Abnormal condition of white blood cells (slight increase in normal cells to fight infection)

5. Abnormal condition of the lung (inflammation and accumulation of material often caused by bacterial infection) _____

6. Tumor (malignant) of bone marrow _____

7. Inflammation of the tube leading from the throat to the stomach _____

8. Disease of heart muscle

9. Collection or mass of blood

10. Tumor (cancerous) of glandular tissue

D Underline the suffix meaning pertaining to in the following terms and give the area or part of the body referred to.

1. esophageal

2. inguinal

3. renal

4. vascular

5. pelvic

6. pulmonary

7. axillary

8. peritoneal

9. mammary

10. myocardial

E Give meanings for the following suffixes related to procedures.

1. -ectomy

2. -gram

3. -centesis

4. -graphy

5. -plasty

6. -lysis

7. -stomy

8. -scopy

9. -tomy

10. -therapy

F Select from the following terms to complete the sentences below.

angiography

angioplasty

bronchoscopy

chemotherapy

colocolostomy

colostomy

hysterectomy

laryngoscopy

mammogram

oophorectomy

phlebotomy

thoracentesis

1. Surgical repair of a blood vessel using a catheter (tube), balloon, and stent is

2. Treatment using chemicals to destroy malignant cells is _____.

3. X-ray record of the breast is a/an _____.

4. Surgical puncture to remove fluid from the chest is _____.

5. A new opening of the large intestine to the outside of the body is a/an _____.

6. A new internal connection (anastomosis) between two parts of the large bowel (intestine) is a/an _____.

7. Removal of the uterus is a/an _____.

8. Process of recording x-ray images of blood vessels after injection of contrast is

9. Visual examination of the voice box is _____.

10. Incision of a vein to withdraw blood is _____.

G Write the medical term for the following definitions.

1. Excessive bleeding (discharge of blood) _____
2. Hardening of fatty plaque (in the lining of the arteries) _____
3. Pertaining to time (occurring over a long period of time) _____
4. X-ray record of the spinal cord _____
5. Sharp, sudden, brief

6. Treatment using cold temperatures _____
7. Record of electricity in the brain _____
8. Surgical puncture to remove fluid from the membrane surrounding the fetus

9. Muscle pain

10. Malignant tumor of bone marrow

11. Enlargement of the heart _____
12. Abnormal condition of the death of cells _____
13. Disease condition of the kidney

14. Incision of the skull

H What part of the body is inflamed?

1. neuritis _____
2. arthritis _____
3. salpingitis _____
4. otitis _____
5. hepatitis _____
6. nephritis _____
7. esophagitis _____
8. laryngitis _____
9. encephalitis _____
10. osteitis _____

11. meningitis _____
12. bronchitis _____
13. rhinitis _____
14. peritonitis _____
15. vasculitis _____
16. mastitis _____
17. tonsillitis _____
18. colitis _____
19. pharyngitis _____
20. phlebitis _____

I Provide the terms for the following procedures.

1. Excision of the gallbladder _____
2. Excision of the appendix _____
3. Excision of a breast _____
4. Excision of the uterus _____
5. Excision of an ovary

6. Excision of the voice box

7. Excision of a kidney

8. Excision of a gland

9. Excision of the large intestine _____
10. Excision of a fallopian tube

11. Excision of tonsils

12. Incision of the skull

13. Incision of the abdomen

14. Incision of the chest _____

15. Opening of the windpipe to the outside of the body _____

16. Opening of the colon to the outside of the body _____

17. Surgical puncture to remove fluid from the chest _____

18. Surgical puncture to remove fluid from a joint _____

19. Incision of a vein (needle or catheter is inserted) _____

20. Visual examination of the voice box _____

J Supply the correct medical term for the following:

1. A stroke is a **cerebro** _____ [two words].

2. A heart attack is a **myo** _____ [two words].

3. Use of a machine that filters wastes from the blood is **hemo** _____.

4. Injection of fluid into the abdominal cavity and then withdrawal of that fluid (containing waste material) is **peri** _____ [two words].

5. A benign tumor of muscle is a **my** _____.

6. A malignant tumor of muscle is a **myo** _____.

7. High levels of wastes (urea) in the blood is **ur** _____.

8. Blood in the urine is **hemat** _____.

9. High numbers of malignant (cancerous) white blood cells is **leuk** _____.

10. Slightly elevated numbers of white blood cells due to an infection in the body is **leuko** _____.

11. Normal discharge of blood during menstruation is **men** _____.

12. Excessive bleeding during menstruation is **men** _____.

13. Hardening of arteries is called **arterio** _____.

14. Use of high-energy rays to treat cancerous tumors is **radio** _____.

K Circle the boldface term that best completes the meaning of the sentences in the following medical vignettes.

1. After routine breast self-examination, Nora felt a small lump in her breast. She consulted her doctor, who scheduled a diagnostic (**mammoplasty, mastectomy, mammogram**). The examination showed a stellate (star-shaped) mass, and a

(biopsy, necropsy, laparoscopy) revealed an infiltrating ductal carcinoma. Nora decided to have her breast removed **(hysterectomy, mastectomy, salpingectomy)**, although her physician gave her the option of having lumpectomy followed by **(cryotherapy, thoracotomy, radiotherapy)**.

2. In addition to her surgery, Nora had a sentinel node biopsy of a/an **(inguinal, thoracic, axillary)** lymph node to determine whether the cancer had spread. Injection of contrast revealed the primary (sentinel) lymph node, which was removed and microscopically examined.
3. Victoria had never been comfortable with the bump on her nose. She saw a plastic surgeon, who performed **(mammoplasty, rhinoplasty, angioplasty)**.
4. Sylvia had irregular bleeding in between her periods. She was 50 years old and beginning menopause. On pelvic exam, Dr. Hawk felt a large, lobulated uterus. Biopsy revealed a large fibroid, which is a benign (noncancerous) tumor of muscle tissue **(myeloma, myoma, hematoma)**. The doctor discussed three surgical options: removal of the fibroid, blockage of blood flow to the fibroid (embolization), or a total abdominal **(gastrectomy, hysterectomy, cholecystectomy)**.
5. Sam was experiencing cramps, diarrhea, and a low-grade fever. He was diagnosed with ulcerative **(colitis, meningitis, laryngitis)** and had several bouts of **(uremia, menorrhagia, septicemia)** caused by inflammation and rupture of the bowel wall.
6. Bill felt chest pain every time he climbed a flight of stairs. He went to his doctor, who did a coronary **(myelogram, angiogram, dialysis)**, which revealed **(adenocarcinoma, nephrosis, atherosclerosis)** in one of his coronary arteries. The doctor recommended **(angioplasty, thoracentesis, amniocentesis)**. This would prevent further **(myosarcoma, ischemia, leukocytosis)** and help Bill avoid a **(peritoneal, vascular, myocardial)** infarction, or heart attack, in the future.

Answers to Exercises

A

1. condition of pain
2. blood condition
3. inflammation
4. enlargement
5. tumor, mass
6. disease condition
7. flow, discharge
8. excessive discharge of blood
9. hardening
10. condition of urine

B

1. muscle pain
2. blood infection
3. high levels of wastes (urea) in the blood
4. inflammation of a vein
5. enlargement of the heart
6. malignant tumor of muscle
7. abnormal condition of the kidney
8. disease of the brain
9. discharge from the nose
10. excessive bleeding during menstruation.

C

1. hepatomegaly
2. otalgia
3. ischemia
4. leukocytosis
5. pneumonia
6. myeloma (also called multiple myeloma)
7. esophagitis
8. cardiomyopathy
9. hematoma
10. adenocarcinoma

D

1. esophageal—esophagus (tube leading from the throat to the stomach)
2. inguinal—groin (area where the thigh meets the trunk of the body)
3. renal—kidney
4. vascular—blood vessels
5. pelvic—hip area
6. pulmonary—lungs
7. axillary—armpit (underarm area)
8. peritoneal—peritoneum (membrane surrounding the abdominal cavity)
9. mammary—breast

10. myocardial—heart muscle

E

1. removal, excision, resection
2. record
3. surgical puncture to remove fluid
4. process of recording
5. surgical repair
6. separation; breakdown
7. new opening
8. process of visual examination
9. cutting into, incision, section
10. treatment

F

1. angioplasty
2. chemotherapy
3. mammogram
4. thoracentesis
5. colostomy
6. colocolostomy
7. hysterectomy
8. angiography
9. laryngoscopy
10. phlebotomy

G

1. hemorrhage
2. atherosclerosis
3. chronic
4. myelogram
5. acute
6. cryotherapy
7. electroencephalogram

8. amniocentesis
9. myalgia
10. myeloma or multiple myeloma
11. cardiomegaly
12. necrosis
13. nephropathy
14. craniotomy

H

1. nerve
2. joint
3. fallopian tubes
4. ear
5. liver
6. kidney
7. esophagus
8. larynx (voice box)
9. brain
10. bone
11. meninges (membranes surrounding the brain and spinal cord)
12. bronchial tubes
13. nose
14. peritoneum
15. blood vessels
16. breast
17. tonsils
18. colon (large intestine)
19. throat (pharynx)
20. veins

I

1. cholecystectomy
2. appendectomy

3. mastectomy
4. hysterectomy
5. oophorectomy
6. laryngectomy
7. nephrectomy
8. adenectomy
9. colectomy
10. salpingectomy
11. tonsillectomy
12. craniotomy
13. laparotomy
14. thoracotomy
15. tracheostomy
16. colostomy
17. thoracentesis
18. arthrocentesis
19. phlebotomy
20. laryngoscopy

J

1. **cerebrovascular accident**—clot or hemorrhage in an artery of the brain leads to decreased blood flow (ischemia) to brain tissue and necrosis (death of brain cells).
2. **myocardial infarction**—ischemia of heart muscle leads to infarction (necrosis of heart muscle cells).
3. **hemodialysis**—complete separation of waste material from the blood using a machine that receives the patient's blood and after filtration sends the blood back into the patient's body.
4. **peritoneal dialysis**—fluid is introduced into the abdominal cavity and then removed after wastes have passed into the fluid from the peritoneal blood vessels.
5. **myoma**—benign muscle tumors occurring in the uterus are fibroids.
6. **myosarcoma**—malignant tumors of connective or flesh tissue are sarcomas.
7. **uremia**—this indicates failure of the kidneys to eliminate nitrogen-containing wastes, such as urea, creatinine, and uric acid, from the bloodstream.
8. **hematuria**—this indicates bleeding in the urinary tract.
9. **leukemia**—immature, cancerous white blood cells are produced in excess from the bone marrow or lymph nodes.

10. **leukocytosis**—normal, mature white blood cells are produced to fight infection.
11. **menorrhoea**—lining of the uterus breaks down as a result of changes in hormone levels.
12. **menorrhagia**—long or heavy menstrual periods; often caused by benign muscle tumors or fibroids in the uterus.
13. **arteriosclerosis**—the most common type is atherosclerosis, or the collection of fatty plaques in arteries.
14. **radiotherapy**—using high-energy x-rays, gamma rays, and protons to destroy cancerous cells.

K

1. mammogram, biopsy, mastectomy, radiotherapy
2. axillary
3. rhinoplasty
4. myoma, hysterectomy
5. colitis, septicemia
6. angiogram, atherosclerosis, angioplasty, ischemia, myocardial

■ Pronunciation of Terms

The terms that you have learned in this chapter are presented here with their pronunciations. The capitalized letters in **BOLDFACE** represent the accented syllable. Pronounce each word out loud; then write the meaning in the space provided. Meanings of all terms can be checked with the Mini-Dictionary beginning on page 349 and on the audio section of the Evolve website (<http://evolve.elsevier.com/Chabner/medtermshort>).

Term	Pronunciation	Meaning
acute	ah-KUT	
adenocarcinoma	ah-deh-no-kar-sih-NO-mah	
adenoma	ah-deh-NO-mah	
amniocentesis	am-ne-o-sen-TE-sis	
anastomosis	ah-nah-sto-MO-sis	
angiography	an-je-OG-rah-fe	
angioplasty	AN-je-o-plas-te	
arteriosclerosis	ar-te-re-o-skleh-RO-sis	
arthralgia	ar-THRAL-je-ah	
arthropathy	ar-THROP-ah-the	
atherosclerosis	ah-theh-ro-skleh-RO-sis	
axillary	AKS-ih-lair-e	
bronchitis	brong-KI-tis	
bronchoscopy	brong-KOS-ko-pe	
carcinoma	kar-sih-NO-mah	
cardiomegaly	kar-de-o-MEG-ah-le	
cardiomyopathy	kar-de-o-mi-OP-ah-the	
chemotherapy	ke-mo-THER-ah-pe	
cholecystectomy	ko-le-sis-TEK-to-me	
chronic	KRON-ik	
colitis	ko-LI-tis	
colostomy	ko-LOS-to-me	
colocolostomy	ko-lo-ko-LOS-to-me	
craniotomy	kra-ne-OT-o-me	
cystitis	sis-TI-tis	
dialysis	di-AL-ih-sis	
electroencephalography	e-lek-tro-en-sef-ah-LOG-rah-fe	
encephalopathy	en-sef-ah-LOP-ah-the	
erythrocytosis	eh-riith-ro-si-TO-sis	
esophageal	e-sof-ah-JE-al	
esophagitis	e-sof-ah-JI-tis	
hematuria	he-mah-TUR-e-ah	
hemorrhage	HEM-o-rij	
hysterectomy	his-teh-REK-to-me	
infarction	in-FARK-shun	
inguinal	ING-gwih-nal	
ischemia	is-KE-me-ah	
laparoscopy	lap-ah-ROS-ko-pe	
laparotomy	lap-ah-ROT-o-me	
laryngitis	lah-rin-JI-tis	
laryngoscopy	lah-rin-GOS-ko-pe	
leukemia	loo-KE-me-ah	
leukocytosis	loo-ko-si-TO-sis	
mammogram	MAM-o-gram	
mammography	mah-MOG-rah-fe	
mammoplasty	MAM-o-plas-te	
mastectomy	mas-TEK-to-me	
meningitis	men-in-JI-tis	
menorrhagia	men-or-RA-jah	
menorrhea	men-o-RE-ah	
myalgia	mi-AL-jah	
myelogram	MI-eh-lo-gram	
myeloma	mi-eh-LO-mah	
myocardial	mi-o-KAR-de-al	
myoma	mi-O-mah	
myosarcoma	mi-o-sar-KO-mah	
necrosis	neh-KRO-sis	
nephrosis	neh-FRO-sis	
neuralgia	nu-RAL-jah	
oophorectomy	o-of-o-REK-to-me or oo-for-EK-to-me	
otalgia	o-TAL-jah	
pelvic	PEL-vik	

peritoneal	per-rih-to-NE-al
phlebitis	fleh-BI-tis
phlebotomy	fleh-BOT-o-me
pneumonia	noo-MO-ne-ah
pulmonary	PUL-mo-nair-re
radiotherapy	ra-de-o-THAIR-ah-pe
renal	RE-nal
rhinoplasty	RI-no-plas-te
rhinorrhea	ri-no-RE-ah
salpingectomy	sal-pin-JEK-to-me
septicemia	sep-tih-SE-me-ah
thoracentesis	tho-rah-sen-TE-sis
tonsillectomy	ton-sih-LEK-to-me
tracheostomy	tra-ke-OS-to-me
uremia	u-RE-me-ah
vascular	VAS-ku-lar

Practical Applications

Answers are given on page 119.

Matching

A Match the procedure in Column I with an abnormal condition (diagnosis) it is associated with in Column II.

Column I Procedure	Column II Abnormal Condition (Diagnosis)
1. angioplasty	_____ A. uterine adenocarcinoma
2. mammoplasty	_____ B. ligament tear of the patella (kneecap)
3. cholecystectomy	_____ C. ovarian cyst
4. tonsillectomy	_____ D. blockage of the windpipe
5. dialysis	_____ E. renal failure
6. hysterectomy	_____ F. absence of a breast (postmastectomy)
7. thoracentesis	_____ G. pleural effusion (collection of fluid)
8. oophorectomy	_____ H. coronary atherosclerosis
9. tracheostomy	_____ I. gallbladder calculi (stones)
10. arthroscopy	_____ J. pharyngeal lymph node enlargement

B Match the sign/symptom (abnormal condition) in Column I with an organ or tissue in Column II.

Column I Sign/Symptom (Abnormal Condition)	Column II Organ or Tissue
1. colitis	_____ A. uterus
2. phlebitis	_____ B. ear
3. menorrhagia	_____ C. bone marrow
4. myocardial ischemia	_____ D. coronary arteries
5. otalgia	_____ E. large bowel
6. uremia	_____ F. membrane surrounding spinal cord or brain
7. meningitis	_____ G. vein
8. leukemia	_____ H. kidney

What's Your Diagnosis?

Case Study

A 45-year-old obese woman presents complaining of menorrhagia [heavy periods] with cramping pelvic pain, dizziness when standing, and rapid heart rate. Manual physical examination demonstrates multiple enlarged masses in her uterus. Blood workup reveals low RBCs [red blood cells] and hematocrit [percentage of red blood cells in a volume of blood], normal WBCs and platelets, and slightly elevated blood sugar level. U/S [ultrasound] of the abdomen and pelvis shows multiple fibroids [leiomyomas] of the uterine wall. Patient is admitted to the hospital with recommendation for hysterectomy. During the course of admission she speaks to the resident dietitian about a compulsive eating disorder and agrees to undergo therapy at the hospital's weight loss clinic.

Using the information presented in the case study, what's your diagnosis?

- A. Pelvic pain—female
- B. Obesity
- C. Anemia
- D. Menorrhagia
- E. Fibroid uterus

Answers to Practical Applications

Matching

A

1. H

2. F

3. I

4. J

5. E

6. A

7. G

8. C

9. D

10. B

B

1. E

2. G

3. A

4. D

5. B

6. H

7. F

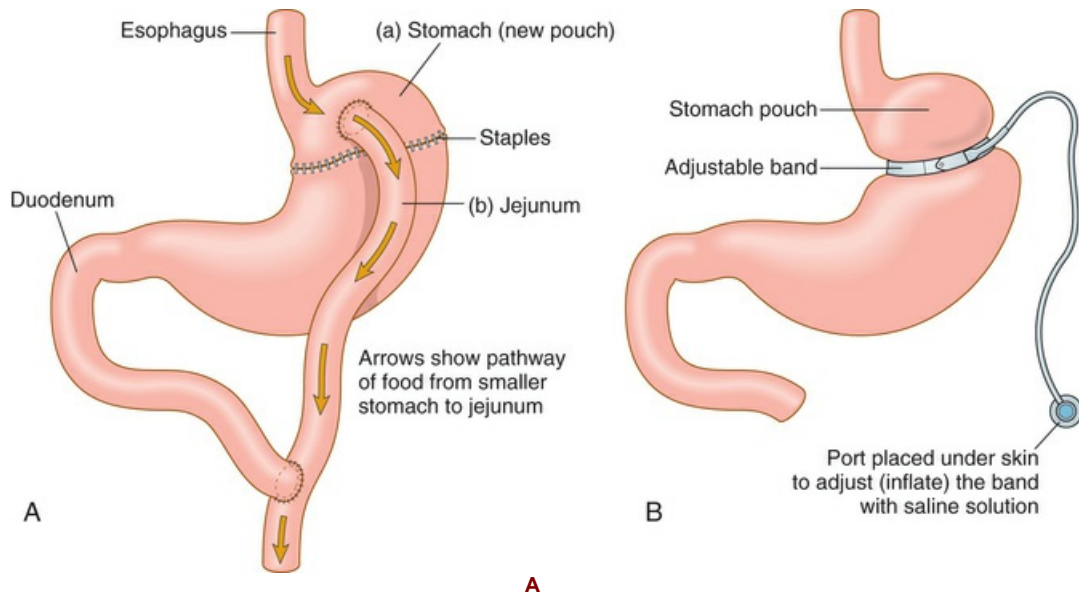
8. C

What's Your Diagnosis?

Answer: E. Fibroid uterus

Picture Show

Answer the questions that follow each image. Correct answers are found on [page 123](#).



1. The drawing in Figure A shows a procedure (**bariatric surgery**)* used to treat extreme obesity. First, the stomach (a) is stapled so that it is reduced to the size of a small pouch. Next, the jejunum (b), which is the second part of the small intestine, is brought up to connect with the smaller stomach. This diverts food so that it has a shorter travel time through the intestine with less time for absorption into the bloodstream. What is the name of this surgical procedure?

- a. esophageal bypass
- b. total gastric resection
- c. gastric bypass
- d. duodenal resection

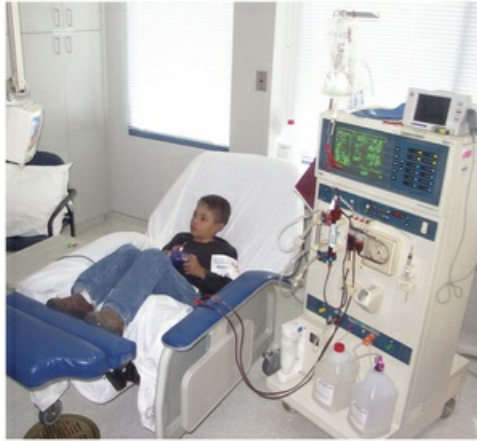2. The new connection, or anastomosis (See [Figure 3-20](#)), between the stomach and the second part of the small intestine is a:

- a. gastrostomy
- b. jejunostomy
- c. gastroduodenostomy
- d. gastrojejunostomy

3. The drawing in Figure B shows another type of bariatric surgery. It is a simpler procedure that creates a small, adjustable stomach pouch without the complications of more invasive surgery. It is called a/an:

- a. lap band procedure

- b. duodenal anastomosis
- c. laparoscopic gastrectomy
- d. esophageal pouch procedure



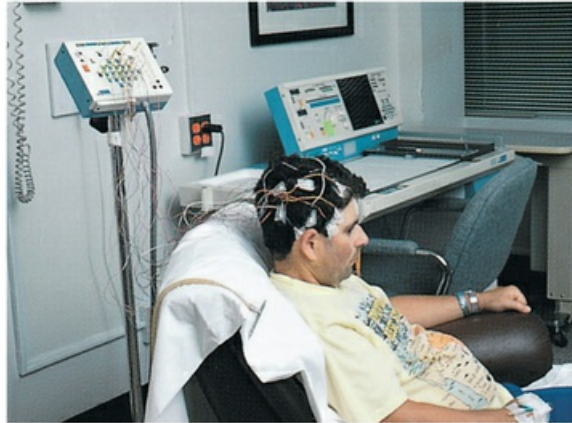B (From Lewis SM, Heitkemper MM, Dirksen SR: *Medical-Surgical Nursing: Assessment and Management of Clinical Problems*, ed 5, St. Louis, 2000, Mosby.)

1. In the image shown, blood leaves the patient's body to enter a machine that filters out impurities. The filtered blood then circulates back to the patient's body. This procedure is:

- a. pericardiocentesis
- b. peritoneal dialysis
- c. hemodialysis
- d. amniocentesis

2. The procedure is a treatment for patients with failure of the:

- a. kidneys
- b. pancreas
- c. liver
- d. all three organs listed



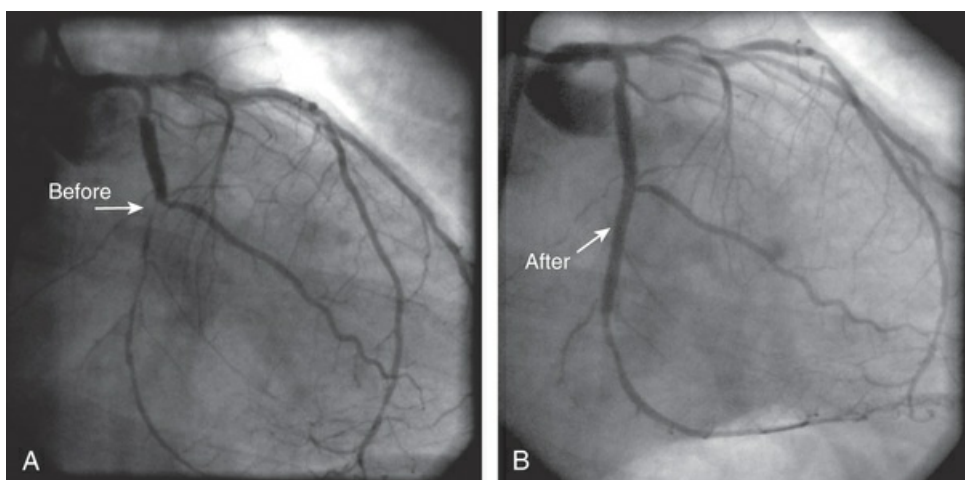
C (From Chipps EM, Clanin NJ, Campbell VG: *Neurologic Disorders*, St. Louis, 1992, Mosby.)

1. This patient is undergoing a procedure that records brain wave activity. It is called:

- a. electrocardiography
- b. electroencephalography
- c. electromyography
- d. electrocraniography

2. It may be used to diagnose:

- a. seizure disorders (epilepsy)
- b. dyspnea
- c. paraplegia
- d. quadriplegia
- e. all four disorders listed



D (Courtesy Dr. Daniel Simon and Mr. Paul Zampino.)

1. The arrow in *A* shows a narrowing of a coronary artery, preventing blood flow to the heart

muscle. A condition caused by decreased blood flow is called:

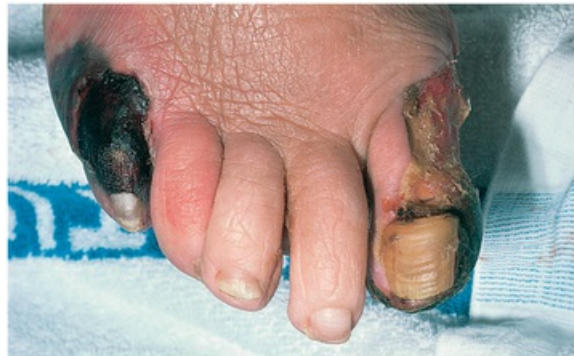- a. nephrosis
- b. uremia
- c. cardiomegaly
- d. ischemia

2. *B* shows the coronary artery after stenting. The imaging procedure that is shown is:

- a. electrocardiography
- b. angiography
- c. radiotherapy
- d. mammography

3. The treatment procedure in which coronary arteries are opened using a balloon catheter and stenting is:

- a. rhinoplasty
- b. phlebotomy
- c. angioplasty
- d. thoracentesis



E

1. The darkened tissue on the toes pictured in the image is called **gangrene**. It is an example of:

- a. dermatitis
- b. necrosis
- c. uremia
- d. hematoma

2. Gangrene may develop as a result of blood vessel injury, frostbite, or conditions such as diabetes

and atherosclerosis. It results from:

- a. hematuria
- b. chronic cystitis
- c. ischemia
- d. cardiomyopathy

Answers to Picture Show

A

- 1. c
- 2. d
- 3. a

B

- 1. c
- 2. a

C

- 1. b
- 2. a

D

- 1. d
- 2. b
- 3. c

E

- 1. b
- 2. c

Review

Write the meanings for the following word parts. Remember to check your answers with the Answers to Review section on page 126.

Suffixes

Suffix	Meaning
1. -al	_____
2. -algia	_____
3. -ar	_____
4. -ary	_____
5. -centesis	_____
6. -eal	_____
7. -ectomy	_____
8. -emia	_____
9. -gram	_____
10. -graphy	_____
11. -ia	_____
12. -ic	_____
13. -itis	_____
14. -lysis	_____
15. -megaly	_____
16. -oma	_____
17. -osis	_____
18. -pathy	_____
19. -plasty	_____
20. -rrhage	_____
21. -rrhagia	_____
22. -rrhea	_____
23. -sclerosis	_____
24. -scopy	_____
25. -stomy	_____
26. -therapy	_____
27. -tomy	_____
28. -uria	_____

Combining Forms

Combining Form	Meaning
1. aden/o	_____
2. amni/o	_____
3. angi/o	_____
4. arteri/o	_____
5. arthr/o	_____
6. ather/o	_____
7. axill/o	_____
8. bronch/o	_____
9. carcin/o	_____
10. cardi/o	_____
11. chem/o	_____
12. cholecyst/o	_____
13. chron/o	_____
14. col/o	_____
15. crani/o	_____
16. cry/o	_____
17. cyst/o	_____
18. encephal/o	_____
19. erythr/o	_____
20. esophag/o	_____
21. hemat/o	_____
22. hepat/o	_____
23. hyster/o	_____
24. inguin/o	_____
25. isch/o	_____
26. lapar/o	_____
27. laryng/o	_____
28. leuk/o	_____
29. mamm/o	_____
30. mast/o	_____

31. men/o _____
32. mening/o _____
33. my/o _____
34. myel/o _____
35. necr/o _____
36. nephr/o _____
37. neur/o _____
38. oophor/o _____
39. oste/o _____
40. ot/o _____
41. pelv/o _____
42. peritone/o _____
43. phleb/o _____
44. pneumon/o _____
45. pulmon/o _____
46. radi/o _____
47. ren/o _____
48. rhin/o _____
49. salping/o _____
50. sarc/o _____
51. septic/o _____
52. thorac/o _____
53. tonsill/o _____
54. trache/o _____
55. ur/o _____
56. vascul/o _____

Answers to Review

Suffixes

1. pertaining to
2. condition of pain, pain
3. pertaining to
4. pertaining to
5. surgical puncture to remove fluid
6. pertaining to
7. removal, resection, excision
8. blood condition
9. record
10. process of recording
11. condition
12. pertaining to
13. inflammation
14. separation, breakdown, destruction
15. enlargement
16. tumor, mass
17. abnormal condition
18. disease condition

19. surgical repair
20. excessive discharge of blood
21. excessive discharge of blood
22. flow, discharge
23. hardening
24. visual examination
25. opening
26. treatment
27. incision; cutting into
28. urine condition

Combining Forms

1. gland
2. amnion
3. vessel
4. artery
5. joint
6. plaque, collection of fatty material
7. armpit
8. bronchial tubes
9. cancerous
10. heart
11. drug, chemical
12. gallbladder
13. time
14. colon (large intestine)
15. skull
16. cold
17. urinary bladder
18. brain
19. red
20. esophagus

21. blood
22. liver
23. uterus
24. groin
25. to hold back
26. abdomen
27. larynx (voice box)
28. white
29. breast
30. breast
31. menstruation
32. meninges
33. muscle
34. spinal cord or bone marrow
35. death
36. kidney
37. nerve
38. ovary
39. bone
40. ear
41. hip area
42. peritoneum
43. vein
44. lung
45. lung
46. x-rays
47. kidney
48. nose
49. fallopian tube
50. flesh
51. pertaining to infection

52. chest

53. tonsil

54. trachea (windpipe)

55. urine, urinary tract

56. blood vessel

Terminology Checkup

In your own words, write the answers on the lines provided. Confirm your answers and check the box next to each item when you know you've "got" it!

1. Explain the concept of **ischemia**. How can it lead to **necrosis**? How does this relate to a **myocardial infarction** and a **cerebrovascular accident**?

2. Explain the difference between the following procedural suffixes: **-tomy**, **-ectomy**, and **-stomy**. Congratulate yourself if you can explain what a surgeon does in an **anastomosis**!

3. What is **uremia**? How is it treated? Name two different types of **treatments for uremia**.

4. What is the difference between the combining forms, **my/o** and **myel/o**? Give meanings for the following terms that contain these combining forms: **myoma**, **myosarcoma**, **myeloma**, and **myelogram**.

5. Define the following surgical resections: **cholecystectomy**, **splenectomy**, and **oophorectomy**.

Answers to Terminology Checkup

1. **Ischemia** leads to necrosis because cells are deprived of necessary blood supply (containing oxygen and nutrients). A **myocardial infarction (heart attack)** is when ischemia and necrosis occur in the heart muscle. A **cerebrovascular accident (stroke)** is when ischemia and necrosis occur in the brain.

2. A procedure ending in **-tomy** is an incision or section. A procedure ending in **-ectomy** is an excision or resection. A procedure ending in **-stomy** is the creation of a new opening in an organ to the outside of the body. An **anastomosis** is a new surgical connection between two tubelike structures **within** the body.

3. **Uremia** is a high concentration of waste products (urea, creatine, and uric acid) in the blood when the kidneys fail to function. It is treated by **dialysis**. Two types of dialysis are **hemodialysis** and **peritoneal dialysis**.

4. **My/o** means muscle. **Myel/o** can mean either bone marrow or spinal cord. **Myoma** is a tumor (benign) of muscle. **Myosarcoma** is a tumor (malignant) of muscle. **Myeloma** is malignant condition occurring in bone marrow. **Myelogram** is an x-ray record of the spinal cord.

5. **Cholecystectomy** is removal of a gallbladder. **Splenectomy** is removal of the spleen.

Oophorectomy is removal of one or both (bilateral) ovaries.

In case you are wondering, the body copes very well without these organs. After **cholecystectomy**, without a gallbladder to store bile, the liver secretes bile as needed. After **splenectomy**, without a spleen to produce white blood cells and process worn-out red blood cells, lymph nodes and the liver take over these functions. After **bilateral oophorectomy**, without ovaries to produce eggs and female hormones, adrenal glands produce small amounts of female hormones.

*Bar/o = weight.

-iatic = pertaining to treatment.



CHAPTER 4

Prefixes

CHAPTER SECTIONS

Introduction	130
Combining Forms and Suffixes	130
Prefixes and Terminology	132
In Person: Total Knee Replacement (TKR)	149
Exercises and Answers	150
Pronunciation of Terms	160
Practical Applications	163
Picture Show	166
Review	169
Terminology CheckUp	173

CHAPTER OBJECTIVES

- To identify and define common prefixes used in medical terms
- To analyze, spell, and pronounce medical terms that contain prefixes
- To apply medical terms in real-life situations

Introduction

This chapter reviews the prefixes you studied in [Chapter 1](#) and introduces new prefixes. The list of Combining Forms and Suffixes that follows will help you understand the terminology presented beginning on [page 132](#). Remember to complete all exercises and check your answers. The Pronunciation of Terms and Review are opportunities to test your understanding of all terminology in this chapter.

■ Combining Forms and Suffixes

Combining Form	Meaning
abdomin/o	abdomen
an/o	anus (opening of the digestive tract to the outside of the body)
bi/o	life
cardi/o	heart
carp/o	carpals (wrist bones)
cis/o	to cut
cost/o	ribs
crani/o	skull
cutane/o	skin
dur/o	dura mater (outermost meningeal membrane surrounding the brain and spinal cord)
gen/o	to produce, to begin
glyc/o	sugar
hemat/o	blood
later/o	side
men/o	menses (monthly discharge of blood from the lining of the uterus)
nat/i	birth
neur/o	nerve
norm/o	rule, order
oste/o	bone
peritone/o	peritoneum (membrane surrounding the organs in the abdomen)
plas/o	formation, growth, development
ren/o	kidney
scapul/o	scapula (shoulder blade)
son/o	sound
thyroid/o	thyroid gland
top/o	to put, place, position
troph/o	development, nourishment
urethr/o	urethra (tube leading from the bladder to the outside of the body)
uter/o	uterus
ven/o	vein
vertebr/o	vertebra (backbone)
Suffix	Meaning
-al	pertaining to
-ation	process, condition
-cision	process of cutting
-crine	secretion
-dipsia	thirst
-emia	blood condition
-gen	to produce
-graphy	process of recording
-ia	condition
-ic	pertaining to
-ine	pertaining to
-ism	condition, process
-lapse	to fall, slide
-lysis	loosening, breakdown, separation, destruction
-meter	to measure
-mission	to send
-mortem	death
-oma	tumor, mass
-ous	pertaining to
-partum	birth
-pathy	disease condition
-phagia	eating
-phasia	speech
-plasia	formation (condition)
-plasm	formation (tissue)
-plegia	paralysis
-pnea	breathing
-rrhea	flow, discharge
-scopy	process of visual examination
-section	to cut
-stasis	to stand, place, stop, control
-tension	pressure
-thesis	to put, place (state of putting or placing)
-tic	pertaining to
-trophy	nourishment; development

-um	structure
-uria	urine condition
-y	process, condition

Prefixes and Terminology

Prefix	Meaning	Terminology	Meaning
a-, an-	no, not, without	apnea _____	
		<i>In this term, the root (PNE, meaning breathing) is embedded in the suffix (-PNEA). Sleep apnea occurs when breathing stops suddenly during sleep.</i>	
		aphasia _____	
		<i>A stroke affecting the language area of the brain can produce this condition.</i>	
		atrophy _____	
		<i>Disuse of a muscle can result in muscular atrophy. Muscles shrink as cells decrease in size.</i>	
		anemia _____	
		<i>Anemia is a condition in which there is a lower-than-normal number of red blood cells or a decrease in hemoglobin within the cells. Table 4-1 different forms of anemia.</i>	
		amenorrhea _____	

TABLE 4-1
ANEMIAS

aplastic anemia	Bone marrow fails to produce red blood cells (erythrocytes), white blood cells (leukocytes), and clotting cells (platelets).
hemolytic anemia	Red blood cells are destroyed (-LYTIC), and bone marrow cannot compensate for their loss. This condition can be hereditary or acquired (after infection or chemotherapy) or can occur when the immune system acts against normal red blood cells (autoimmune condition).
iron deficiency anemia	Low iron levels lead to low hemoglobin concentration or deficiency of red blood cells.
pernicious anemia	The mucous membrane of the stomach fails to produce a substance (intrinsic factor) that is necessary for the absorption of vitamin B ₁₂ and the proper formation of red blood cells.
sickle cell anemia	Erythrocytes assume an abnormal crescent or sickle shape; this “sickling” is due to the inheritance of an abnormal type of hemoglobin. The sickle-shaped cells clump together, causing clots that block blood vessels.

ab-	away from	abnormal _____
ad-	toward, near	adrenal glands _____ <i>See Figure 4-1.</i>

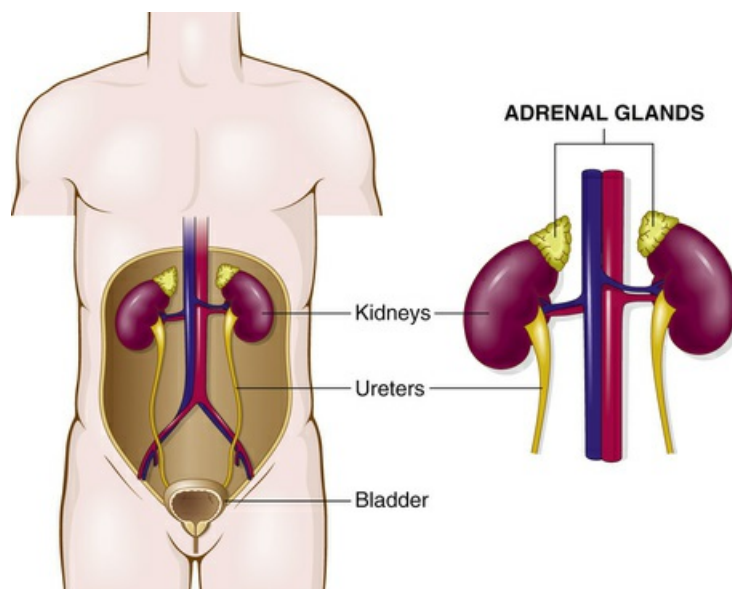


FIGURE 4-1 Adrenal glands. These two endocrine glands are above each kidney. (Modified from Chabner D-E: *The Language of Medicine*, ed 11, St. Louis, 2017, Elsevier.)

ana-	up, apart	analysis _____
ante-	before, forward	ante partum _____
anti-	against	antibody _____ <i>Protein made by white blood cells—literally, a “body” working “against” foreign substances.</i>
		antigen _____ <i>Antigens are foreign substances, such as bacteria and viruses. When antigens enter the body, they stimulate white blood cells to produce antibodies that act against the antigens.</i>

		<u>antibiotic</u> _____ Antibiotics are produced outside the body by micro-organisms and primitive plants called molds. Examples are penicillin and erythromycin. <i>disease-fighting medications, they are taken by mouth or through intravenous injection, or applied topically to be absorbed through the skin.</i>
bi-	two, both	<u>bilateral</u> _____
brady-	slow	<u>bradycardia</u> _____
con-	with, together	<u>congenital</u> _____ <i>A congenital anomaly is an irregularity (anomaly) present at birth. Examples are webbed fingers and toes and heart defects. See Figure 4-2.</i>

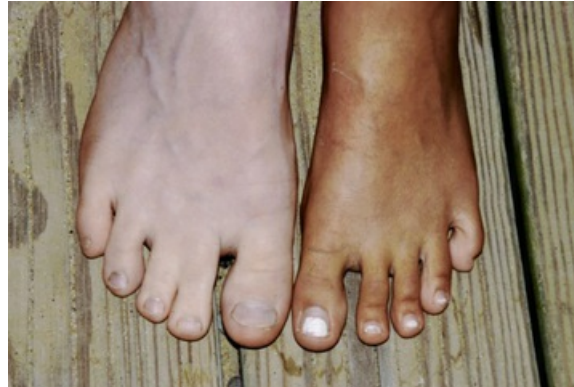

FIGURE 4-2 Webbed toes. The foot on the left (pale) shows “webbing” of the toes (syndactyly). On the right, another person’s foot (darker) has normal toes. (From Chabner D-E: *The Language of Medicine*, ed 11, St. Louis, 2017, Elsevier.)

dia-	complete, through	<u>diarrhea</u> _____ <i>Feces (stools) are loose and watery. Normal water reabsorption through the walls of the colon is impaired.</i>
dys-	bad, painful, difficult, abnormal	<u>dyspnea</u> _____
		<u>dysphagia</u> _____
		<u>dysplasia</u> _____
		<u>dysmenorrhea</u> _____
		<u>dysuria</u> _____ <i>Dysuria is often a symptom of a urinary tract infection (UTI).</i>
ec-	out, outside	<u>ectopic pregnancy</u> _____ <i>Figure 4-3 shows an ectopic tubal pregnancy.</i>

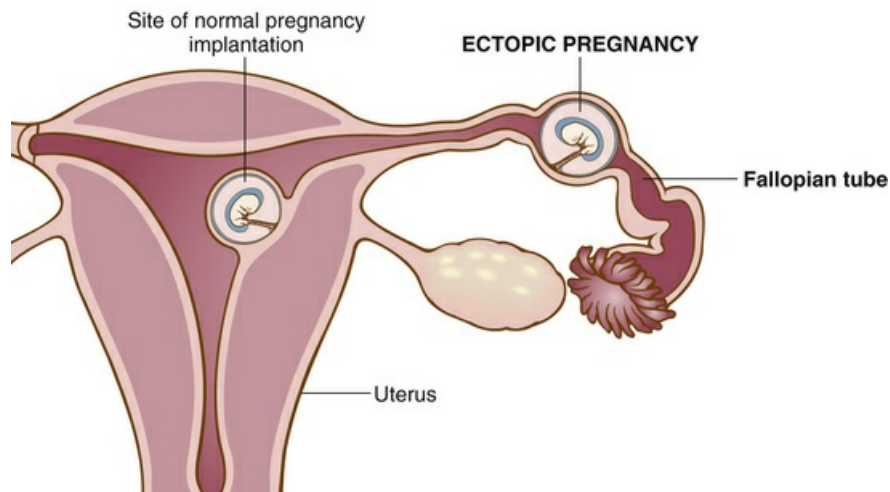


FIGURE 4-3 Ectopic pregnancy. The fallopian tube (ectopic tubal pregnancy) is the most common site for ectopic pregnancies (95%), but they can also occur on the ovary or on the surface of the peritoneum. Normal implantation takes place on the inner lining (endometrium) of the uterus.

endo-	within, in, inner	<u>endoscopy</u> _____ <i>Table 4-2 lists types of endoscopy procedures.</i>
		<u>endocrine glands</u> _____ <i>The adrenal glands are endocrine glands. Table 4-3 lists the major endocrine glands and the hormones that they secrete.</i>

TABLE 4-2
TYPES OF ENDOSCOPY PROCEDURES*

arthroscopy	Visual examination of a joint
bronchoscopy	Visual examination of the bronchial tubes
colonoscopy	Visual examination of the colon (large intestine)
cystoscopy	Visual examination of the urinary bladder
esophagogastrosocopy	Visual examination of the esophagus and stomach

hysteroscopy	Visual examination of the uterus
laparoscopy	Visual examination of the abdomen
laryngoscopy	Visual examination of the larynx (voice box)
mediastinoscopy	Visual examination of the mediastinum
sigmoidoscopy	Visual examination of the sigmoid colon (the lower, S-shaped part of the large intestine)

*For images of these procedures, visit the Evolve website for this book (<http://evolve.elsevier.com/Chabner/medtermshort>).

TABLE 4-3
MAJOR ENDOCRINE GLANDS AND SELECTED HORMONES

Gland	Hormones
adrenal glands	Adrenaline (epinephrine)
ovaries	Estrogen Progesterone
pancreas	Insulin
parathyroid glands	Parathyroid hormone (PTH)
pituitary gland	Adrenocorticotropic hormone (ACTH) Follicle-stimulating hormone (FSH) Growth hormone (GH) Thyroid-stimulating hormone (TSH)
testes	Testosterone
thyroid gland	Thyroxine (T4)

epi- above, upon	epidural hematoma _____ <i>Figure 4-4 illustrates epidural and subdural hematomas.</i>
	epidermis _____ <i>The three layers of the skin, from outermost to innermost, are the epidermis, dermis, and subcutaneous layer. See Appendix 1, Body System page 215.</i>

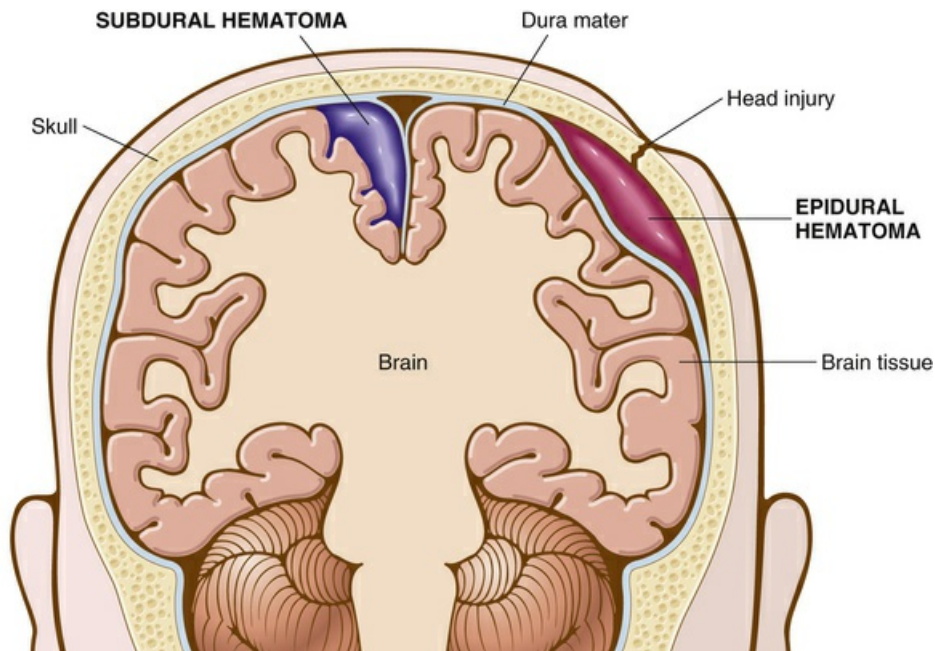


FIGURE 4-4 Epidural and subdural hematomas. The dura mater is the outermost of the three meninges (membranes) around the brain and spinal cord.

ex-	out	excision _____
extra-	outside of	extrahepatic _____
hemi-	half	hemigastrectomy _____
		hemiplegia _____ <i>One side of the body is paralyzed; usually caused by a cerebrovascular accident or brain lesion, such as a tumor. The resulting paralysis occur the side opposite the brain disorder.</i>
hyper-	excessive, too much, above	hyperthyroidism _____ <i>Figure 4-5 shows position of the thyroid gland in the neck.</i>
		hyperplasia _____ <i>Cells increase in number. The prostate gland is enlarged in benign prostatic hyperplasia (BPH).</i>
		hypertrophy _____ <i>Cells increase in size, not in number. The opposite of hypertrophy is atrophy (cells shrink in size). See Figure 4-6.</i>
		hypertension _____

Risk factors that contribute to high blood pressure are increasing age, smoking, obesity, heredity, and stressful lifestyle.

hyperglycemia

May also be a sign of **diabetes mellitus**. Insulin either is not secreted or is improperly utilized so that sugar accumulates in the bloodstream spills over into the urine (glycosuria).

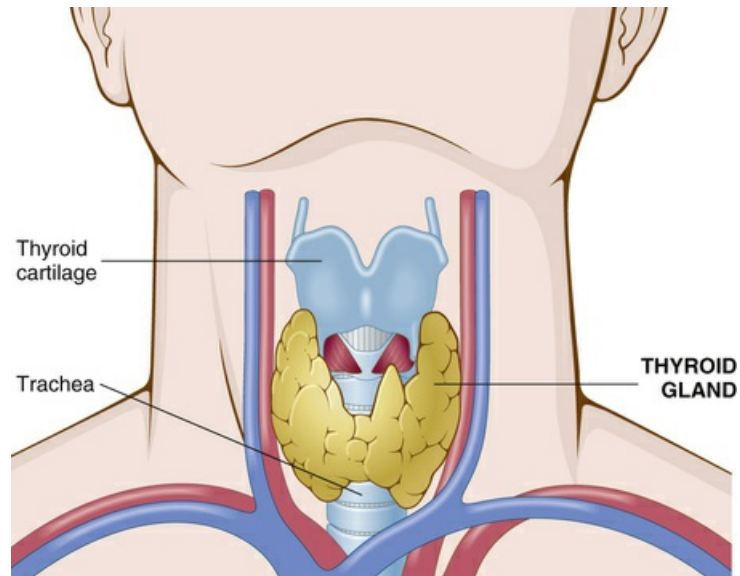


FIGURE 4-5 Thyroid gland, located in the front of the trachea in the neck. The thyroid gland produces too much hormone in hyperthyroidism.

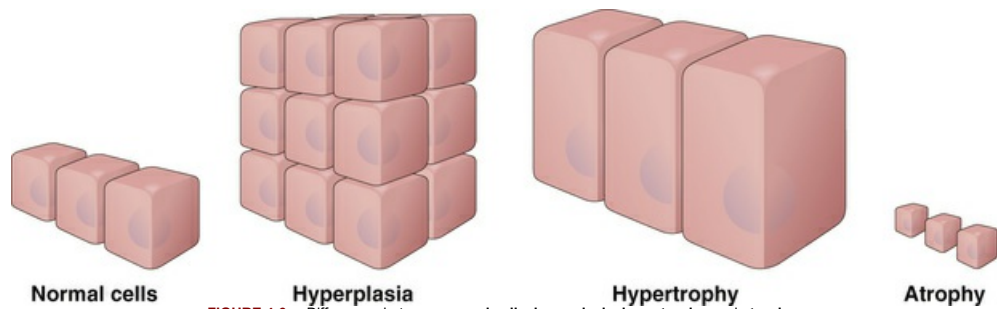



FIGURE 4-6 Differences between normal cells, hyperplasia, hypertrophy, and atrophy.

hypo-	deficient, too little, below	<u>hypoglycemia</u> Overproduction of insulin or an overdose (from outside the body—exogenously) of insulin can lead to hypoglycemia, as glucose is removed from the blood at an increased rate.
in-	in, into	<u>incision</u>
inter-	between	<u>intervertebral</u> An intervertebral disk lies between any two vertebrae.
intra-	within	<u>intrauterine</u>
		<u>intravenous</u> The abbreviation for intravenous is IV. See Figure 4-7.

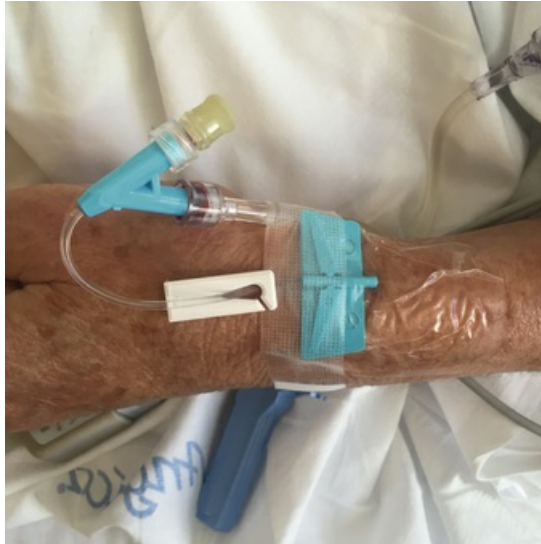

FIGURE 4-7 Intravenous set up for anesthesia administration.

mal-	bad	malignant 
meta-	change, beyond	metastasis This term literally means a “change of place” (-STASIS).It is the spread of a cancerous tumor from its original place to a secondary location in body. See Figure 4-8 .
		metacarpals The carpal bones are the wrist bones, and the metacarpals are the hand bones, which are beyond the wrist. See the x-ray image of the hand in Figure 4-9 .

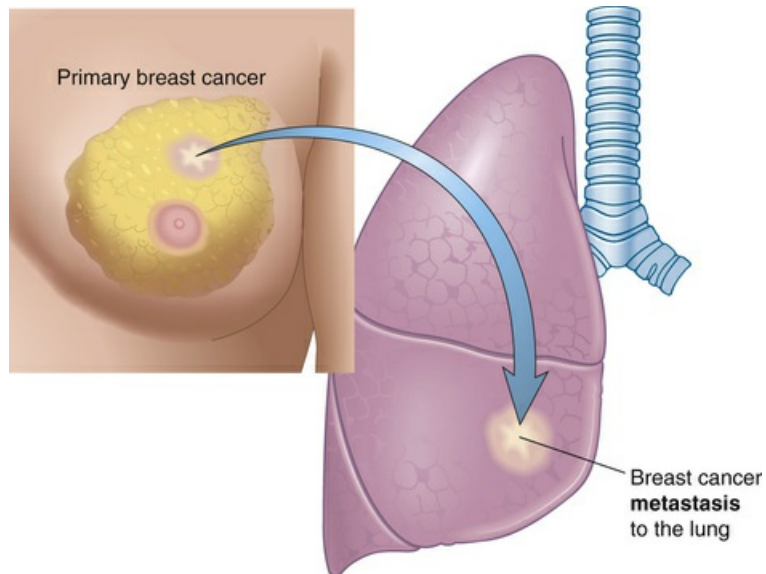


FIGURE 4-8 Metastasis. Note the difference between a primary breast cancer and breast cancer that has metastasized to the lung.

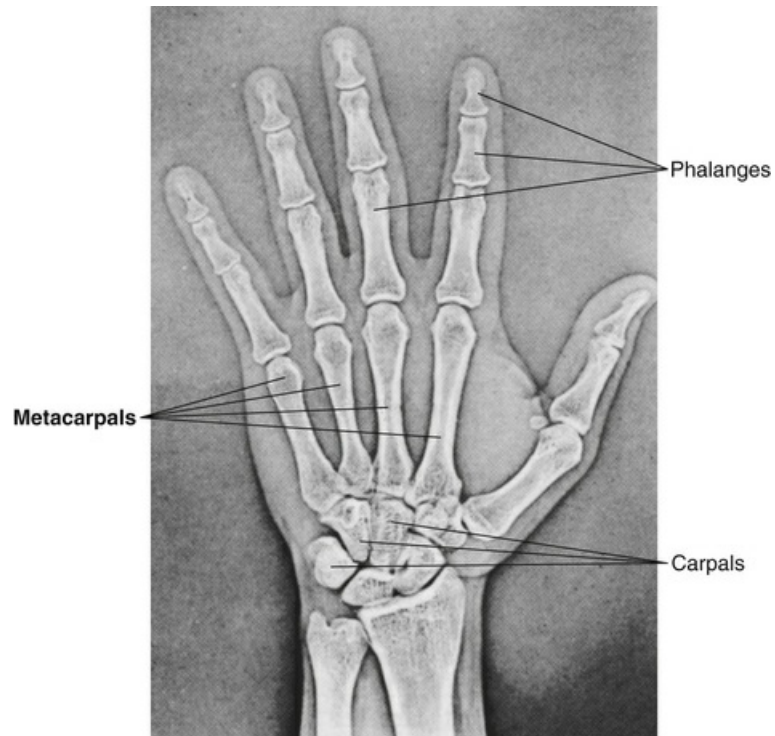


FIGURE 4-9 Metacarpals. This x-ray image of a hand shows metacarpals, carpals (wrist bones), and phalanges (finger bones).

neo-	new	<u>neoplasm</u>
		<u>neoplastic</u>
		<u>neonatal</u>
		Neonates (see Figure 4-10) who are born prematurely are often cared for in the neonatal intensive care unit (NICU—pronunciation is NIK-u). See Figure 4-10 .

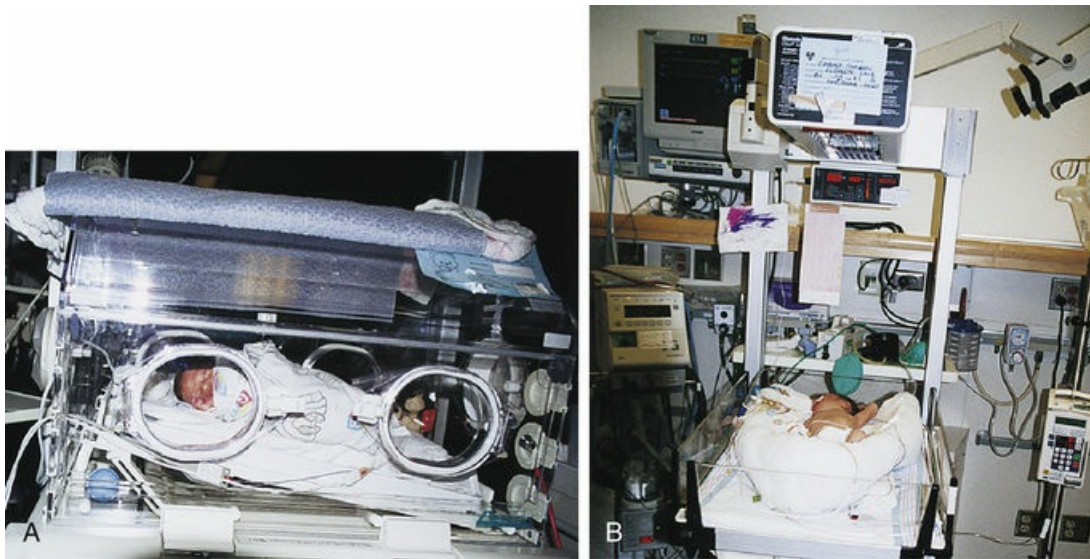


FIGURE 4-10 Neonates in the neonatal intensive care unit (NICU). A, Benjamin Oliver Chabner, born May 22, 2001, at 32 weeks (8 weeks premature). B, Samuel August “Gus” Thompson, born August 13, 2001, at 36 weeks. Gus needed an endotracheal tube through which he received surfactant, a substance necessary to inflate his lungs. Both children are healthy and a delight to their grandmother. See the dedication page for a current photo!

para-	beside, near, along the side of	<u>parathyroid glands</u>
		Figure 4-11 shows the position of the parathyroid glands on the back side of the thyroid gland. The parathyroid glands are endocrine glands that regulate the amount of calcium in bones and in the blood.

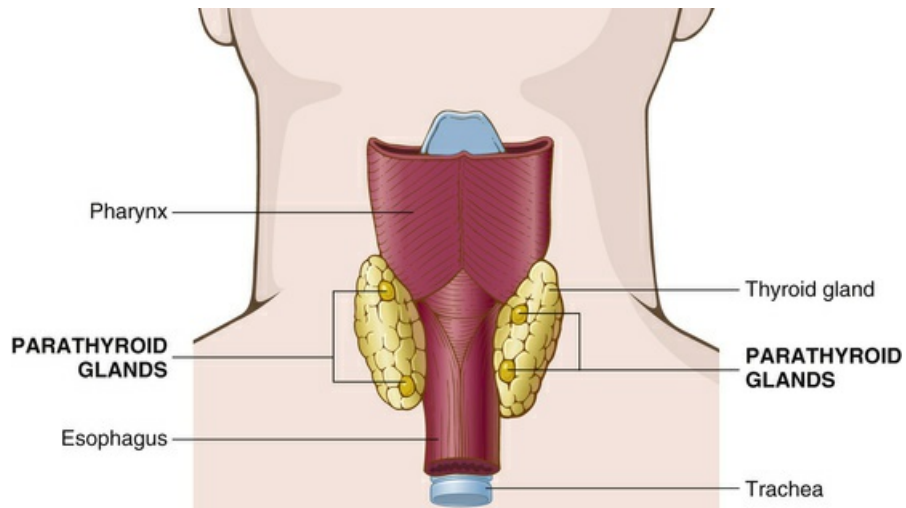


FIGURE 4-11 Parathyroid glands. These are four endocrine glands on the posterior (back side) of the thyroid gland.

		<u>paralysis</u> _____ <i>This term came from the Greek paralytikos, meaning “one whose side was loose or weak,” as after a stroke. Now it means a loss of movement any part of the body caused by a break in the connection between nerve and muscle.</i>
		<u>paraplegia</u> _____ <i>-PLEGIA means paralysis, and this term originally meant paralysis of any limb or side of the body. Since the nineteenth century, however, it indicated paralysis of the lower half of the body.</i>
peri-	surrounding	<u>periosteum</u> _____ <u>perianal</u> _____
poly-	many, much	<u>polyuria</u> _____ <u>polyneuropathy</u> _____ <u>polydipsia</u> _____ <i>Symptoms of diabetes mellitus are polyuria and polydipsia.</i>
post-	after, behind	<u>postpartum</u> _____ <u>postmortem</u> _____
pre-	before	<u>precancerous</u> _____ <i>An example of a precancerous lesion is a polyp (benign growth), commonly found in the colon. Polyps are often removed via colonoscopy, because they may eventually become malignant.</i> <u>prenatal</u> _____
pro-	before, forward	<u>prolapse</u> _____ <i>-LAPSE means to slide. Figure 4-12 shows both the normal position of the uterus and its position when prolapsed.</i>

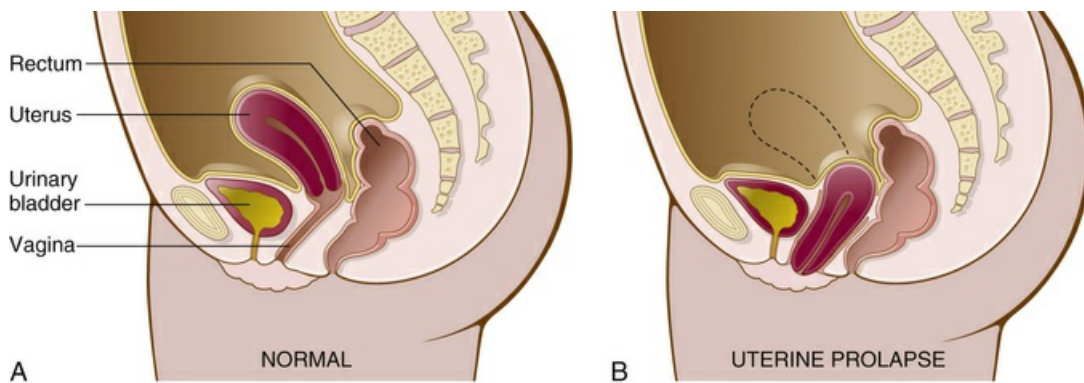


FIGURE 4-12 Uterine prolapse. Prolapsed uterus is shown in B. Normally, the uterus is tilted forward, above the urinary bladder.

pros-	before, forward	<u>prosthesis</u> _____ <i>An artificial limb is a prosthesis—literally, something “placed before” (as a replacement). Figure 4-13 shows Amy Palmiero-Winters running with a sports prosthetic leg. Figure 4-14 shows a total hip replacement and a total knee joint replacement. See <i>In Person: Total Knee Replacement</i> on page 149.</i>
--------------	-----------------	--



FIGURE 4-13 Amy Palmiero-Winters is the first female with a prosthetic leg to finish the Badwater 135, a 135-mile race from Badwater in Death Valley to Mount Whitney, California.

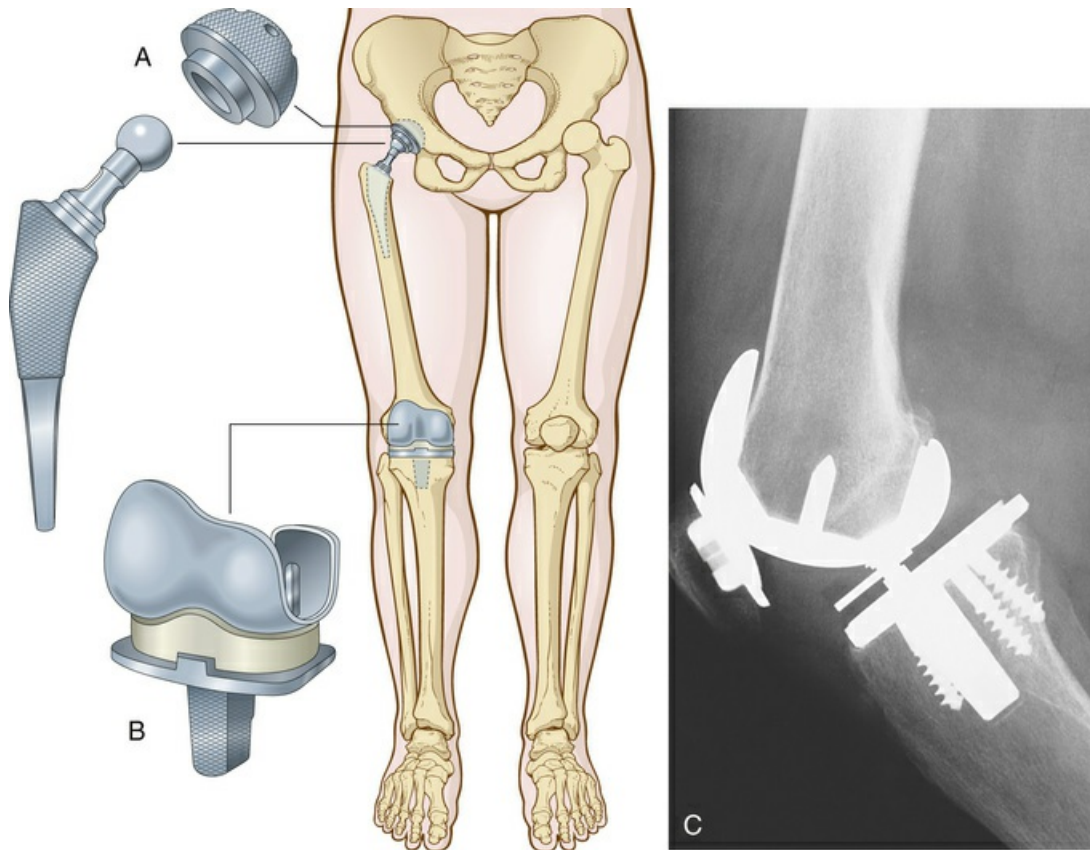


FIGURE 4-14 Total hip joint replacement and total knee joint replacement. A, In total hip joint replacement, a cementless prosthesis allows porous ingrowth of bone. B, In total knee joint replacement, the prosthesis includes a tibial metal retainer and a femoral component. The femoral component is chosen individually for each patient according to the amount of healthy bone present. C, X-ray image of knee replacement. (C, From Mettler FA: *Essentials of Radiology*, ed 3, Philadelphia, 2014, Saunders.)

quadri-	four	<u>quadriplegia</u> <i>Paralysis of all four limbs.</i>
re-	back, behind	<u>relapse</u> <i>Symptoms of disease return when a patient has a relapse. Exacerbation is an increase in the severity of a disease or any of its symptoms.</i> <u>remission</u> <i>Symptoms of disease lessen when the disease goes into remission.</i> <u>resection</u>
retro-	back, behind	<u>retroperitoneal</u> <i>The kidneys are retroperitoneal organs. (See Figure 2-4 on page 52.)</i>
sub-	under, less than	<u>subcostal</u> <u>subcutaneous</u> <u>subtotal</u> <i>A subtotal gastrectomy is a partial resection of the stomach.</i>

subscapular _____
 The scapula is the shoulder bone. *Figure 4-15* shows its location.

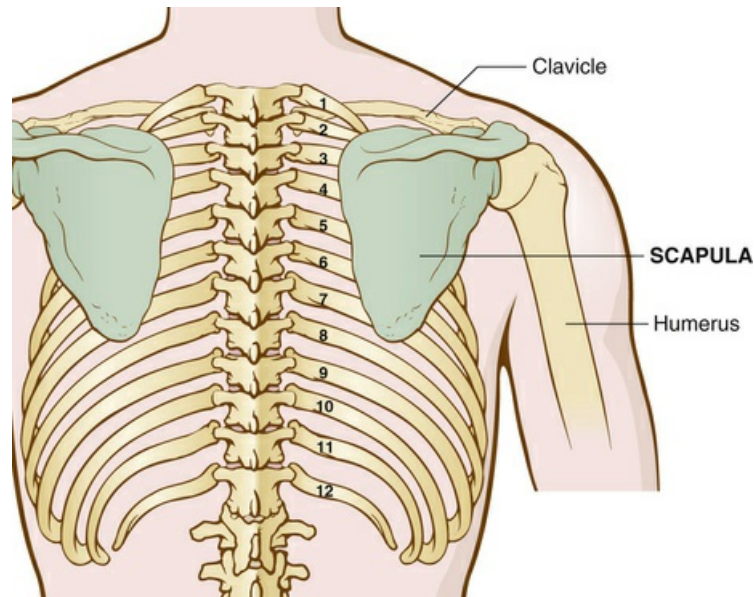


FIGURE 4-15 Scapula (shoulder bone), posterior view. The clavicle is the collarbone, and the humerus is the upper arm bone. (Modified from Chabner D-E: *The Language of Medicine*, ed 11, St. Louis, 2017, Elsevier.)

syn- with, together syndrome _____
 -DROME means running or occurring. A syndrome is a group of symptoms and signs of illness that occur together. *Table 4-4* gives example syndromes.

Table 4-4
SYNDROMES*

Syndrome	Signs and Symptoms
acquired immunodeficiency syndrome (AIDS)	Severe infections, malignancy (Kaposi sarcoma and lymphoma), fever, malaise (discomfort), and gastrointestinal disturbances. It is caused by a virus that damages lymphocytes (white blood cells).
carpal tunnel syndrome	Pain, tingling, burning, and numbness of the hand and wrist. A nerve leading to the hand is compressed l connective tissue fibers in the wrist.
Down syndrome	Mental retardation, flat face with a short nose, slanted eyes, broad hands and feet, stubby fingers, and protruding lower lip. The syndrome occurs when an extra chromosome is present in each cell of the body
mitral valve prolapse syndrome	Abnormal sounds (murmurs) heard through a stethoscope placed on the chest. These murmurs indicate t the mitral valve is not closing properly. Chest pain, dyspnea (difficult breathing), and fatigue are other symptoms.
toxic shock syndrome	High fever, vomiting, diarrhea, rash, hypotension (low blood pressure), and shock. It typically is caused t bacterial infection in the vagina of menstruating women using superabsorbent tampons.

* See the Evolve website for additional information about syndromes (<http://evolve.elsevier.com/Chabner/medtermshort>).

tachy-	fast	tachycardia _____ tachypnea _____
trans-	across, through	transabdominal _____ transurethral _____ In a <i>transurethral resection of the prostate gland (TURP)</i> , pieces of the prostate gland are removed through the urethra. This procedure relieves symptoms of <i>benign prostatic hyperplasia (BPH)</i> . See <i>Figure 1-13</i> page 20.
tri-	three	tricuspid valve _____ -CUSPID means "pointed end," as of a spear. The tricuspid valve is on the right side of the heart, while the mitral (bicuspid) valve is on the l side of the heart. <i>Figure 4-16</i> shows the location of both valves and indicates the pathway of blood through the heart.

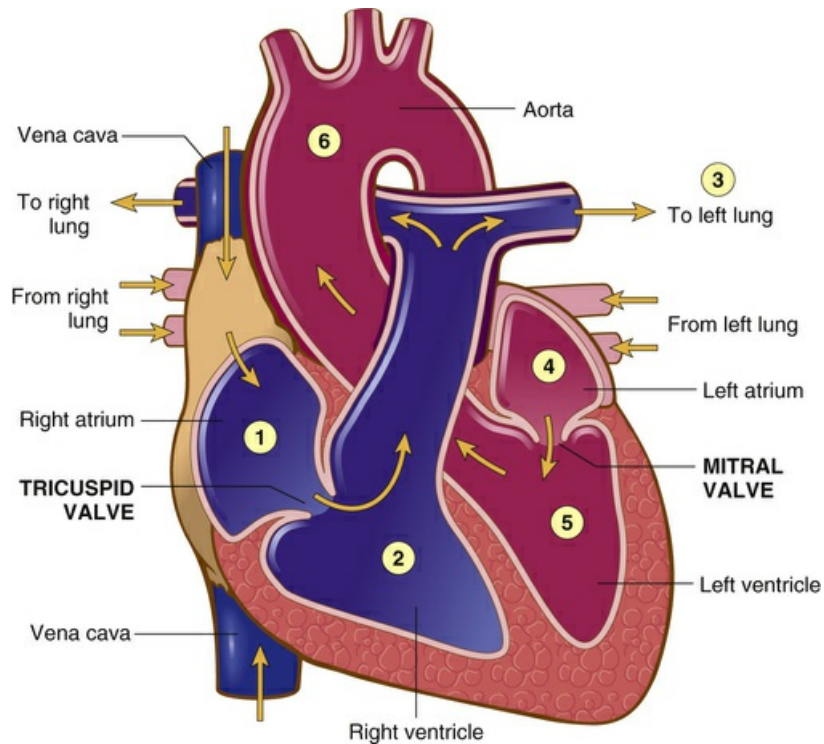


FIGURE 4-16 Tricuspid and mitral valves of the heart. Blood enters the *right atrium* of the heart (1) from the big veins (venae cavae) and passes through the *tricuspid valve* to the *right ventricle* (2). Blood then travels to the *lungs* (3), where it loses carbon dioxide (a gaseous waste) and picks up oxygen. Blood returns to the heart into the *left atrium* (4) and passes through the *mitral valve* to the *left ventricle* (5). It is then pumped from the left ventricle out of the heart into the largest artery, the *aorta* (6), which carries the blood to all parts of the body.

ultra- beyond ultrasonography
Figure 4-17 shows an ultrasonogram (sonogram) of a fetus.

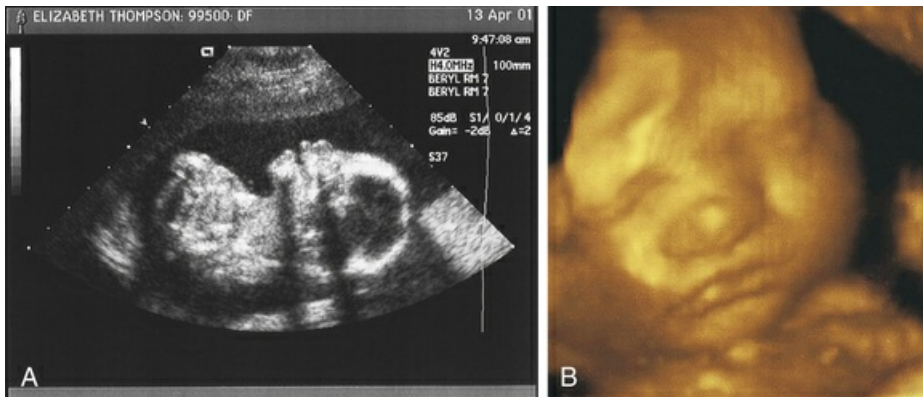


FIGURE 4-17 **A**, Ultrasonogram showing my grandson Samuel August "Gus" Thompson as a 19-week-old fetus. **B**, Three-dimensional sonogram. (A, Courtesy Dr. Elizabeth Chabner Thompson. B, From Hagen-Ansert SL: *Textbook of Diagnostic Ultrasonography*, ed 6, St. Louis, 2006, Mosby.)

uni- one unilateral

■ Analysis of urine

A **urinalysis** (urine + analysis) is the separation of urine to determine its components. The following chart shows typical urinalysis findings:

Test	Normal	Abnormal
1. Color	light yellow	red (hematuria)
2. Clarity	clear	cloudy (infection)
3. pH (chemical nature)	slightly acidic	alkaline (infection)
4. Protein	very slight	proteinuria (renal disease)
5. Sugar	none	glycosuria (diabetes mellitus)

■ -Plasia, -phagia, and -phasia

Don't confuse these very different suffixes: **-plasia** (PLAY-zhah) means formation, **-phagia** (FAY-

jah) means eating or swallowing, and **-phasia** (FAY-ze-ah) means speech.

■ Malignant versus benign

The root **IGN** comes from the Latin *ignis*, meaning “fire.” A malignant tumor is a cancerous growth that spreads like a “wildfire” from its original location to other organs. A **benign** tumor (**BEN-** means “good”) is a noncancerous growth that does not spread.

■ Intensive care units

Note the pronunciations and meanings of other hospital intensive care units:

MICU (MIK-u)	medical intensive care unit
MSICU (M-SIK-u)	medical/surgical intensive care unit
PACU (PAK-U)	post anesthesia care unit
PICU (PIK-u)	pediatric or psychiatric intensive care unit
SICU (SIK-u)	surgical intensive care unit

■ Polyuria and diuretics

Polyuria is the excretion of abnormally large quantity of urine. Diuretics (**DI-** from **DIA-**, meaning “complete”) are drugs that promote polyuria. They are used in the treatment of hypertension to lower blood pressure by removing excess fluid from the body.

■ In Person: Total Knee Replacement (TKR)



I had endured many years of diminishing mobility in my right leg, alleviated somewhat by occasional cortisone shots and two arthroscopic surgeries. While stitching the second arthroscopic wound, my orthopedist said, “Nothing more to be done with this one. ... next stop: total knee replacement!” He was right! My TKR procedure was inevitable and indeed very radical.

It involved major trauma to all the supporting muscles, tendons, nerves, and blood vessels. Hence a long period of recuperation was involved. I took advantage of the extra day that was offered to me at MGH (bless Medicare!) for a total hospitalization of five days, during which I had to learn how to perform the most basic functions in new ways. I found, after many trials, that a walker is preferable to crutches. Both are hard on the hands, but the walker is more stable, and the attachable basket is a boon.

For those who are contemplating TKR, the question of where to do the rehab is crucial. If, as I did, you have the conditions to recover at home, that is preferable. The necessary conditions are, first, a partner or caregiver who is available 24/7 for the first few days and who doesn't decide to take a prolonged vacation after that. ... The second relates to the physical conditions at home. Preferably the living area should all be on one level; although climbing stairs becomes one of the protocols of physical therapy, it takes a while to get to that point, and one is not very steady until that time. Easy access to bathrooms and to other living areas is crucial. The third necessary condition is the availability of the physical therapist. Living in the summer and fall months in rural New Hampshire, I was fortunate to qualify for the services of the local VNA [Visiting Nurse Association], and a marvelous physical therapist visited me three times a week for about six weeks. In between visits, I worked hard to win her approval, and although it seemed at first like tackling Everest to lift my leg even one inch off the floor, let alone walk, within about six weeks I could drive, even if I was getting around outside with crutches; within two months I had regained good mobility, and six months later I was as good as new, and ever so grateful. ...

Although I consider this procedure to be nothing short of miraculous, like any major elective surgery, one should not undertake it unless the pain of daily life outweighs its joys. ... when the doctors ask you about the pain, on a scale of 1 to 10, take them seriously. Don't undergo this surgery until it hovers around 8 or 9 ... and then—well, enjoy the results!

Sidra DeKoven Ezrahi is a professor emeritus of Comparative Literature at the Hebrew University and is a Guggenheim Fellow. She divides her time between Jerusalem, Israel, and Wilmot, New Hampshire.

Exercises and Answers

Complete these exercises and check your answers. An important part of your success in learning medical terminology is checking your answers carefully with the Answers to Exercises beginning on [page 158](#). Don't forget to *wRite, Review, and Repeat!*

A Give meanings for the following prefixes.

1. anti-

2. ana-

3. ad-

4. bi-

5. brady-

6. ab-

7. a-, an-

8. ante-

9. con-

10. dia-

B Complete the following sentences with the medical terms listed below.

analysis

anemia

antibiotic

antibody

antigen

apnea

atrophy

bilateral

bradycardia

diarrhea

1. A patient with hearing loss in both ears has a/an _____ condition.
2. When airways collapse or are blocked during sleep, a condition called sleep _____ may occur.
3. A protein produced by white blood cells in response to a foreign substance, such as a bacterium or virus, is a/an _____.
4. A foreign substance, such as a bacterium or virus, is a/an _____.
5. Decrease in hemoglobin in the blood to below the normal range produces a condition known as _____.
6. A condition of frequent loose, watery stools that seem to “flow through” the body is called _____.
7. The separation of substances into their component parts is known as _____.
8. A medication produced from molds or synthesized in a laboratory to destroy microorganisms is a/an _____.
9. A condition in which the heart rate is less than 60 beats per minute is _____.
10. Having an arm in a cast and not using it can cause _____.

C Give medical terms for the following meanings.

1. Without speech:

2. Lack of menstrual flow:

3. Before birth:

4. Glands located near the kidneys: _____ glands
5. An irregularity appearing with birth: _____ anomaly
6. Separation of waste materials from the blood when the kidneys fail: _____

D Give meanings for the following prefixes.

1. ec- _____
2. epi- _____
3. hemi- _____
4. hyper- _____
5. hypo- _____

6. dys- _____

7. endo- _____

8. ex- _____

9. extra- _____

10. in- _____

E Complete the following sentences using the medical terms listed below.

dysmenorrhea

dysphagia

dysplasia

dyspnea

dysuria

endoscopy

epidermis

excision

extrahepatic

incision

1. Pain associated with menstrual flow is _____.

2. Cutting into a part of the body is a/an _____.

3. Any abnormal development in tissues or organs is _____.

4. Cutting out of a part of the body is a/an _____.

5. Painful burning sensation upon urination is _____.

6. Painful breathing that may be caused by anxiety, strenuous exercise, or certain heart conditions is _____.

7. The outer layer of skin is the _____.

8. Pertaining to outside the liver is _____.

9. Difficulty in swallowing is called _____.

10. Visual examination (via an endoscope) of what is within an organ is _____.

F Complete the following medical terms using the meanings provided.

1. High blood pressure is _____ **tension**.
2. A mass of blood above the membrane surrounding the brain is a/an _____ **dural hemat**_____.
3. A pregnancy that is out of its normal place is a/an _____ **topic pregnancy**.
4. A condition of excessive (too much) blood sugar is _____ **emia**.
5. A condition of deficient (too little) blood sugar is _____ **emia**.
6. Glands that secrete hormones within the body are _____ **crine glands**.
7. Increase in development (individual cells increase in size) often caused by overuse of a muscle or organ is **hyper**_____.
8. Paralysis of half of the body related to a stroke is _____ **plegia**.
9. Excessive secretion from a gland in front of the trachea is **hyper**_____.
10. Increased formation (numbers of cells) is **hyper**_____.

G Give meanings for the following prefixes.

1. intra- _____
2. mal- _____
3. para- _____
4. peri- _____
5. poly- _____
6. inter- _____
7. meta- _____
8. neo- _____
9. post- _____
10. pre- _____

H Give meanings for the following medical terms.

1. intervertebral

2. metastasis

3. metacarpals

4. intravenous

5. postmortem

6. periosteum

7. precancerous

8. neonatal

9. paraplegia

10. malignant

I Complete each of the sentences that follow by selecting from the list of terms below. The bold words in each sentence should help you choose the correct term.

adrenal glands

dyspnea

extracranial

intrauterine

neoplasm

parathyroid glands

perianal

polydipsia

polyneuropathy

polyuria

postpartum

1. An injury to the **outside** of the skull is a/an _____ lesion.
2. Four small glands in the neck region **near** (posterior to) another endocrine gland are the _____.
3. Common symptoms of diabetes are **much** urination, or _____ and **much** thirst, or _____.
4. People who experience asthma often have **difficult** breathing, which is called _____.

5. Bleeding can occur from cracks or sores **surrounding** the opening to the rectum. These are _____ fissures.
6. Two glands each located **near** (above) a kidney are _____.
7. A **new** growth, which can be malignant or benign, is a/an _____.
8. Disease of **many** nerves is known as a/an _____.
9. Any problem that affects the fetus **within** the womb is a/an _____ condition.
10. Women may experience moodiness and sad feelings **after** birth, a condition known as _____ depression.

J Give meanings for the following prefixes.

1. pro- _____
2. quadri- _____
3. sub- _____
4. tachy- _____
5. trans- _____
6. uni- _____
7. re- _____
8. pros- _____
9. retro- _____
10. syn- _____
11. ultra- _____
12. tri- _____

K Select from the list of terms below to complete each of the following sentences.

- prolapse
- prosthesis
- quadriplegia
- relapse
- remission
- resection
- subtotal

syndrome

tachypnea

tricuspid

ultrasonography

unilateral

1. Removal or cutting out of an organ is a/an _____.
2. Test that shows the structure of organs using sound waves beyond the normal range of hearing is _____.
3. An artificial part of the body is a/an _____.
4. Recurrence of symptoms of an illness is a/an _____.
5. Recovery and disappearance of symptoms is a/an _____.
6. Rapid breathing is _____.
7. If the spinal cord is severed in the cervical region, paralysis of all four limbs, known as _____, will result.
8. The _____ valve has three parts and is on the right side of the heart, between the upper and lower chambers.
9. If a patient has a/an _____ gastrectomy, less than the complete stomach is removed.
10. Pain, tingling, burning, and numbness of the hand are symptoms of carpal tunnel _____.

L Define the following terms that describe parts of the body.

1. subscapular

2. transabdominal

3. retroperitoneal

4. subcutaneous

5. intervertebral

M Select from the terms listed below to complete the sentences that follow.

anemia
aphasia
paralysis
prolapse
relapse
remission
tachycardia
transurethral

1. After her ninth child, muscles in Ms. Smith's uterine wall weakened, causing her uterus to fall and _____ through her vagina.
2. After Mr. Jones' heart attack, his cardiologist noticed a rapid heart rhythm, or _____
3. A cerebrovascular accident (CVA) on the left side of the brain can cause a loss of speech, or _____.
4. Menorrhagia and lack of iron in Sharon's diet led to a condition of low hemoglobin and iron deficiency _____.
5. The operation to remove part of Bill's enlarged prostate gland involved placing a catheter through his urethra and removing pieces of the gland. The surgery, called a TURP, or _____ resection of the prostate gland, improved his ability to urinate. The prostate gland is at the base of the urinary bladder in males (see [Figure 4-18](#)).

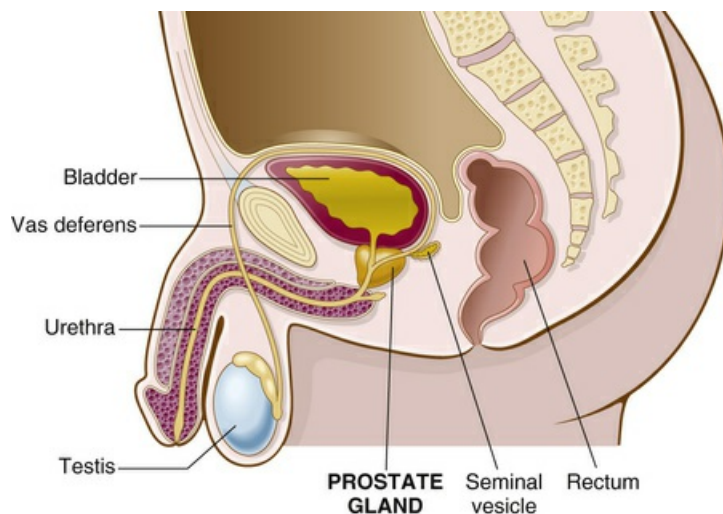


FIGURE 4-18 Prostate gland.

N Circle the correct meaning in bold in each of the following statements.

1. Dys- and mal- both mean (**outside, good, bad**).
2. Hypo- and sub- both mean (**under, above, outside**).
3. Epi- and hyper- both mean (**inside, beneath, above**).
4. Con- and syn- both mean (**apart, near, with**).
5. Ultra- and meta- both mean (**new, beyond, without**).
6. Ante-, pre-, and pro- all mean (**before, surrounding, between**).
7. Ec- and extra- both mean (**within, many, outside**).
8. Endo-, intra-, and in- all mean (**painful, within, through**).
9. Post-, re-, and retro- all mean (**behind, slow, together**).
10. Uni- means (**one, two, three**).
11. Tri- means (**one, two, three**).
12. Bi- means (**one, two, three**).

○ Circle the boldface term that best completes the meaning of the sentences in the following medical vignettes.

1. As part of her (**intravenous, postpartum, prenatal**) care, Beatrix underwent (**ultrasonography, endoscopy, urinalysis**) to determine the age, size, and development of her fetus.
2. Ellen's pregnancy test was positive, but she had excruciating pelvic pain. After a careful pelvic exam and ultrasound scan, the doctors diagnosed a/an (**epidural, ectopic, subscapular**) pregnancy. She then underwent emergency surgery to remove the implanted tissue from the fallopian tube.
3. After noticing a suspicious-looking mole on her upper arm, Carole was diagnosed with (**malignant, benign, subtotal**) melanoma. This type of skin cancer is a/an (**intrauterine, extrahepatic, neoplastic**) process and has a high likelihood of (**paralysis, dysplasia, metastasis**) to other areas of the body.
4. Carole's daughter, Annabelle, found a mole on her back and quickly had it checked by her physician. Fortunately, after a biopsy, the pathologic examination revealed a (**transabdominal, precancerous, perianal**) nevus (mole) that was considered (**chronic, unilateral, benign**). In the future, Annabelle will need close follow-up for other suspicious lesions.
5. Milton's blood pressure was 160/110 mm Hg. Normal blood pressure is 120/80 mm Hg. To reduce Milton's risk of stroke, his physician prescribed medication to treat his (**bradycardia, hypertension, dyspnea**).

Answers To Exercises

A

1. against
2. up, apart
3. toward, near
4. two, both
5. slow
6. away from
7. no, not, without
8. before, forward
9. with, together
10. through, complete

B

1. bilateral
2. apnea
3. antibody
4. antigen
5. anemia
6. diarrhea
7. analysis
8. antibiotic
9. bradycardia
10. atrophy

C

1. aphasia
2. amenorrhea
3. antepartum or prenatal
4. adrenal
5. congenital
6. dialysis

D

1. out, outside
2. above, upon

3. half
4. excessive, too much, above
5. deficient, too little, below
6. bad, painful, difficult, abnormal
7. within, in, inner
8. out
9. outside of
10. in, into

E

1. dysmenorrhea
2. incision
3. dysplasia
4. excision
5. dysuria
6. dyspnea
7. epidermis
8. extrahepatic
9. dysphagia
10. endoscopy

F

1. **hypertension**
2. **epidural hematoma**
3. ectopic
4. **hyperglycemia**
5. **hypoglycemia**
6. **endocrine**
7. hypertrophy
8. **hemiplegia**
9. **hyperthyroidism**
10. **hyperplasia**

G

1. within
2. bad
3. beside, near, along the side of
4. surrounding
5. many, much
6. between
7. change, beyond
8. new
9. after, behind
10. before

H

1. pertaining to between the vertebrae (backbones)
2. change of place or beyond control (spread of a cancerous tumor to a secondary location)
3. beyond the wrist bones (carpals); hand bones
4. pertaining to within a vein
5. after death
6. membrane surrounding a bone
7. pertaining to a condition that comes before malignancy—for example, dysplastic nevi (moles) that precede malignant melanoma
8. pertaining to new birth (a neonate is a newborn)
9. condition of paralysis of the lower half of the body
10. cancerous; not benign

I

1. extracranial
2. parathyroid glands
3. polyuria; polydipsia
4. dyspnea
5. perianal
6. adrenal glands
7. neoplasm
8. polyneuropathy
9. intrauterine

10. postpartum

J

1. before, forward

2. four

3. under, less than

4. fast

5. across, through

6. one

7. back, behind

8. before, forward

9. back, behind

10. with, together

11. beyond

12. three

K

1. resection

2. ultrasonography

3. prosthesis; literally, something "put forward"

4. relapse

5. remission

6. tachypnea

7. quadriplegia

8. tricuspid

9. subtotal

10. syndrome

L

1. pertaining to under the scapula (shoulder bone)

2. pertaining to across or through the abdomen

3. pertaining to behind the peritoneum

4. pertaining to under the skin

5. pertaining to between the vertebrae (backbones)

M

1. prolapse
2. tachycardia
3. aphasia
4. anemia
5. transurethral

N

1. bad
2. under
3. above
4. with
5. beyond
6. before
7. outside
8. within
9. behind
10. one
11. three
12. two

O

1. prenatal, ultrasonography
2. ectopic
3. malignant, neoplastic, metastasis
4. precancerous, benign
5. hypertension

■ Pronunciation of Terms

The terms that you have learned in this chapter are presented here with their pronunciations. The capitalized letters in **BOLDFACE** represent the accented syllable. Pronounce each word out loud; then write its meaning in the space provided. All terms are defined in the **Mini-Dictionary**, beginning on page 349, and on the audio section of the *Evolve* website (<http://evolve.elsevier.com/medtermshort>).

Term	Pronunciation	Meaning
abnormal	ab-NOR-mal	
adrenal glands	ah-DRE-nal glanz	
analysis	ah-NAL-ih-sis	
anemia	ah-NE-me-ah	
antepartum	an-te PAR-tum	
antibiotic	an-tih-bi-OT-ik	
antibody	AN-tih-bod-e	
antigen	AN-tih-jen	
aphasia	a-FAY-ze-ah	
apnea	AP-ne-ah	
atrophy	AT-ro-fe	
benign	be-NIN	
bilateral	bi-LAT-er-al	
bradycardia	bra-de-KAR-de-ah	
congenital anomaly	kon-JEN-ih-tal ah-NOM-ah-le	
dialysis	di-AL-ih-sis	
diarrhea	di-ah-RE-ah	
dysphagia	dis-FAY-jah	
dysplasia	dis-PLAY-zhah	
dyspnea	DISP-ne-ah or disp-NE-ah	
dysuria	dis-U-re-ah	
ectopic pregnancy	ek-TOP-ik PREG-nan-se	
endocrine glands	EN-do-krin glanz	
endoscopy	en-DOS-ko-pe	
epidural hematoma	ep-ih-DUR-al he-mah-TO-mah	
excision	ek-SIZH-un	
extrahepatic	eks-tra-heh-PAT-ik	
hemigastrectomy	heh-me-gast-REK-to-me	
hemiplegia	heh-me-PLE-jah	
hyperglycemia	hi-per-gli-SE-me-ah	
hyperplasia	hi-per-PLA-zhah	
hypertension	hi-per-TEN-shun	
hyperthyroidism	hi-per-THI-royd-izm	
hypertrophy	hi-PER-tro-fe	
hypoglycemia	hi-po-gli-SE-me-ah	
incision	in-SIZH-un	
intervertebral	in-ter-VER-teh-bral	
intrauterine	in-trah-U-ter-in	
intravenous	in-trah-VE-nus	
malignant	mah-LIG-nant	
metacarpal	met-ah-KAR-pal	
metastasis	meh-TAS-tah-sis	
neonatal	ne-o-NA-tal	
neoplastic	ne-o-PLAS-tik	
paralysis	pah-RAL-ih-sis	
paraplegia	par-ah-PLE-jah	
parathyroid glands	par-ah-THI-royd glanz	
perianal	per-e-A-nal	
periosteum	per-e-OS-te-um	
polydipsia	pol-e-DIP-se-	
polyneuropathy	pol-e-noo-ROP-ah-the	
polyuria	pol-e-UR-e-ah	
postmortem	post-MOR-tem	
postpartum	post-PAR-tum	
precancerous	pre-KAN-ser-us	
prolapse	pro-LAPS	
prosthesis	pros-THE-sis	
quadriplegia	quah-drih-PLE-jah	
relapse	re-LAPS	
remission	re-MISH-un	
resection	re-SEK-shun	
retroperitoneal	reh-tro-per-ih-to-NE-al	

subcostal	sub-KOS-tal
subcutaneous	sub-ku-TA-ne-us
subdural hematoma	sub-DUR-al he-mah-TO-mah
subscapular	sub-SKAP-u-lar
subtotal	SUB-to-tal
syndrome	SIN-drom
tachycardia	tak-eh-KAR-de-ah
tachypnea	tak-ip-NE-ah
transabdominal	trans-ab-DOM-ih-nal
transurethral	trans-u-RE-thral
tricuspid valve	tri-KUS-pid valv
ultrasonography	ul-trah-son-OG-rah-fe
unilateral	u-nih-LAT-er-al
urinalysis	u-rih-NAL-ih-sis

■ Practical Applications

Matching

Match the abnormal condition in Column I with the organ, lesion, or body part in Column II that may be involved in or cause the condition. Answers are found on [page 165](#).

Column I	Column II
1. aphasia	A. urinary bladder
2. dysphagia	B. colon
3. diarrhea	C. uterine cervix
4. quadriplegia	D. left-sided brain lesion
5. hyperglycemia	E. pancreas
6. dysuria	F. lungs
7. paraplegia	G. heart
8. bradycardia	H. cervical spinal cord lesion
9. dyspnea	I. esophagus
10. dysplasia	J. lumbar spinal cord lesion

Disease Description: Hyperthyroidism

From the list below, select terms to complete the sentences in the paragraphs that follow.

antibiotics

antibodies

bradycardia

dyspnea

exophthalmos

goiter

hyperplastic

hypersecretion

hypoplastic

hyposcretion

neoplastic

tachycardia

1. Hyperthyroidism, also known as thyrotoxicosis or Graves disease, is marked by an excess of thyroid hormones. There is much evidence for a hereditary factor in the development of this condition, and some researchers consider it to be an autoimmune disorder caused by _____ that bind to the surface of thyroid gland cells and stimulate _____ of hormones (T3 and T4—triiodothyronine and thyroxine). On histologic examination, the enlarged gland is composed of _____ follicles lined with hyperactive cells.

2. Signs and symptoms of hyperthyroidism include restlessness, insomnia, weight loss, sweating, and rapid heartbeat, or _____. Abnormal protrusion of the eyes, known as _____, is another clinical sign. The patient typically also has an enlarged thyroid gland, called a/an _____.

What's Your Diagnosis?

Case Study

A 22-year-old sexually active female presents to the ED [emergency department] with history of temperature of 104° F for 2 days, vomiting, diarrhea, and a red spotty rash over her chest and abdomen. She reports that she remembered not removing a tampon from her last menstrual cycle until a week after she had stopped menstruating. Other complaints include dysmenorrhea and dysuria.

Physical examination does not reveal an acute abdomen [sudden, severe abdominal pain] or any RLQ (right lower quadrant) tenderness. Blood test is negative for HCG [human chorionic gonadotropin or pregnancy test]; CBC [complete blood count] reveals elevated white blood cell count; blood cultures are positive for staphylococci.

The patient's fever and dehydration do not subside with initial emergency care, and she is subsequently admitted to the hospital. She is seen by a physician from ID [infectious disease], who confirms that the retained tampon has resulted in the above conditions. Her condition improves with IV fluids and antibiotics.

Using the information presented in this case study, what's your diagnosis? Answer is found on page 165.

- A. Dehydration
- B. Fever
- C. Toxic shock syndrome (TSS) with *Staphylococcus aureus*
- D. Rash
- E. Nausea/vomiting

Answers to Practical Applications

Matching

- 1. D
- 2. I
- 3. B
- 4. H
- 5. E
- 6. A
- 7. J
- 8. G
- 9. F
- 10. C

Disease Description: Hyperthyroidism

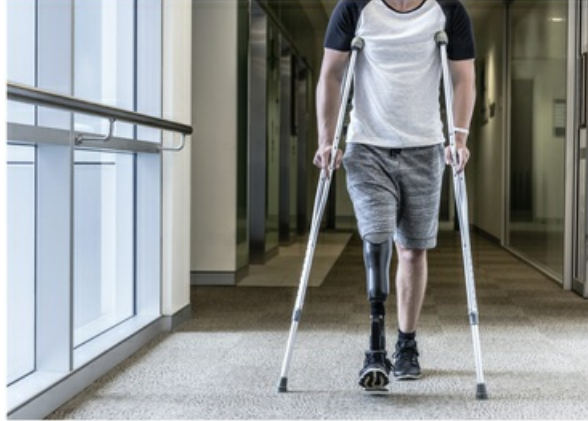- 1. antibodies, hypersecretion, hyperplastic
- 2. tachycardia, exophthalmos, goiter

What's Your Diagnosis?

Answer: C. Toxic shock syndrome (TSS) with *Staphylococcus aureus*

Picture Show

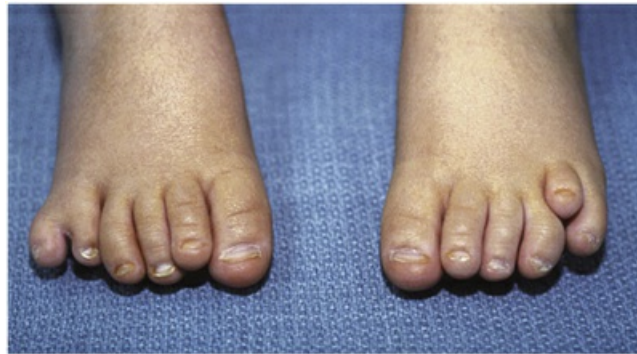Answer the questions that follow each image. Correct answers are given on [page 168](#).



A (Image from iStock.com/ Johnny Greigi.)

1. This man is walking with the assistance of a:

- a. polyneuropathy
- b. anastomosis
- c. prosthesis
- d. metastasis

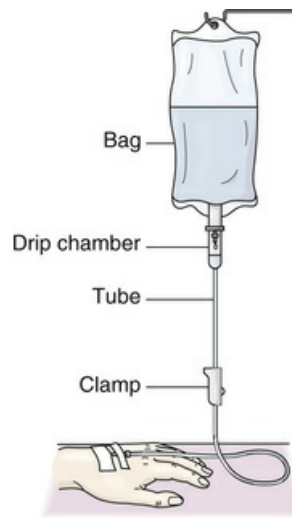


B (From Zitelli BJ, Davis HW: *Campbell's Operative Orthopaedics* ed 4, St. Louis, 2008, Saunders.)

1. This image shows the feet of a child with a condition called: (HINT: the combining form for toes is DACTYL/O):

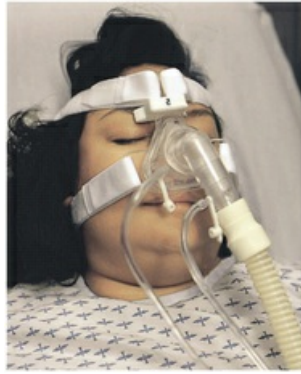- a. syndactyly
- b. conductyly
- c. transdactyly
- d. polydactyly

2. This condition occurs as a/an:
- a. neoplastic anomaly
 - b. congenital anomaly
 - c. hypertensive anomaly
 - d. ectopic pregnancy



C (Modified from Sorrentino SA: *Mosby's Textbook for Nursing Assistants*, ed 5, St. Louis, 2000, Mosby.)

1. This equipment permits nutrients to enter the bloodstream and is used for:
- a. hemodialysis
 - b. intrauterine feeding
 - c. intravenous feeding
 - d. peritoneal dialysis
2. Which term describes a condition or procedure that would be likely to make this equipment necessary?
- a. metacarpalgia
 - b. hemigastrectomy
 - c. polyneuropathy
 - d. epidural hematoma
 - e. ultrasonography



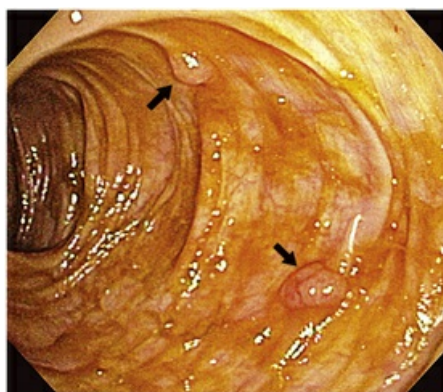
D (From Elkin MK, Perry AG, Potter PA: *Nursing Interventions and Clinical Skills*, ed 2, St. Louis, 2000, Mosby.)

1. The image shows a woman using a device that helps her maintain adequate blood oxygen levels while sleeping. This method is called:

- a. airway prosthesis
- b. nasogastric intubation
- c. bronchoscopy
- d. continuous positive airway pressure (CPAP)

2. The condition that may require use of such a device during sleep is:

- a. bradycardia
- b. aphasia
- c. apnea
- d. dysphagia



E (From Weinstein WM, Hawkey CJ, Bosch J: *Clinical Gastroenterology and Hepatology*, St. Louis, 2005, Mosby.)

1. The arrows in this image show abnormal, precancerous, neoplastic lesions in the colon. They are:

- a. polyps
- b. fibroids

- c. prolapsed mitral valves
 - d. metastases
2. This image was obtained using:
- a. intrauterine ultrasonography
 - b. electrocardiography
 - c. transabdominal ultrasonography
 - d. endoscopy

Answers to Picture Show

A

1. c

B

1. d

2. b

C

1. c

2. b

D

1. d

2. c

E

1. a

2. d

Review

Write the meaning of each of the following word parts, and remember to check your answers with the Answers to Review on page 172.

Prefixes

Prefix	Meaning
1. a-, an-	_____
2. ab-	_____
3. ad-	_____
4. ana-	_____
5. ante-	_____
6. anti-	_____
7. bi-	_____
8. brady-	_____
9. con-	_____
10. dia-	_____
11. dys-	_____
12. ec-	_____
13. endo-	_____
14. epi-	_____
15. ex-, extra-	_____
16. hemi-	_____
17. hyper-	_____
18. hypo-	_____
19. in-	_____
20. inter-	_____
21. intra-	_____
22. mal-	_____
23. meta-	_____
24. neo-	_____
25. para-	_____
26. peri-	_____
27. post-	_____
28. pre-	_____
29. pro-, pros-	_____
30. quadri-	_____
31. re-, retro-	_____
32. sub-	_____
33. syn-	_____
34. tachy-	_____
35. trans-	_____
36. tri-	_____
37. ultra-	_____
38. uni-	_____

Combining Forms

Combining Form	Meaning
1. abdomin/o	_____
2. an/o	_____
3. bi/o	_____
4. cardi/o	_____
5. carp/o	_____
6. cis/o	_____
7. cost/o	_____
8. crani/o	_____
9. cutane/o	_____
10. dur/o	_____
11. gen/o	_____
12. glyco/o	_____
13. hemat/o	_____
14. later/o	_____
15. nat/i	_____
16. neur/o	_____
17. norm/o	_____
18. oste/o	_____
19. peritone/o	_____
20. plas/o	_____

21. ren/o _____
22. scapul/o _____
23. son/o _____
24. thyroid/o _____
25. top/o _____
26. troph/o _____
27. urethr/o _____
28. uter/o _____
29. ven/o _____
30. vertebr/o _____

Suffixes

Suffix	Meaning
1. -al _____	
2. -ation _____	
3. -cision _____	
4. -crine _____	
5. -dipsia _____	
6. -emia _____	
7. -gen _____	
8. -graphy _____	
9. -ia _____	
10. -ic _____	
11. -ine _____	
12. -ism _____	
13. -lapse _____	
14. -lysis _____	
15. -meter _____	
16. -mission _____	
17. -mortem _____	
18. -oma _____	
19. -ous _____	
20. -partum _____	
21. -pathy _____	
22. -phagia _____	
23. -phasia _____	
24. -plasia _____	
25. -plasm _____	
26. -plegia _____	
27. -pnea _____	
28. -rrhea _____	
29. -scopy _____	
30. -section _____	
31. -stasis _____	
32. -tension _____	
33. -thesis _____	
34. -tic _____	
35. -trophy _____	
36. -um _____	
37. -uria _____	
38. -y _____	

Answers to Review

Prefixes

1. no, not, without
2. away from
3. toward
4. up, apart
5. before, forward
6. against

7. two
8. slow
9. with, together
10. through, complete
11. bad, painful, difficult, abnormal
12. out, outside
13. within, in, inner
14. above, upon
15. out, outside
16. half
17. excessive, above
18. below, under
19. in, into
20. between
21. within
22. bad
23. change, beyond
24. new
25. beside, near, along the side of
26. surrounding
27. after, behind
28. before
29. before, forward
30. four
31. back, behind
32. under, less than
33. with, together
34. fast
35. across, through
36. three
37. beyond

38. one

Combining Forms

1. abdomen

2. anus

3. life

4. heart

5. wrist bones

6. to cut

7. ribs

8. skull

9. skin

10. dura mater

11. to produce

12. sugar

13. blood

14. side

15. birth

16. nerve

17. rule, order

18. bone

19. peritoneum

20. formation, growth

21. kidney

22. shoulder blade (bone)

23. sound

24. thyroid gland

25. to put, place

26. development, nourishment

27. urethra

28. uterus

29. vein

30. vertebra (backbone)

Suffixes

1. pertaining to
2. process, condition
3. process of cutting
4. secretion
5. condition of thirst
6. blood condition
7. to produce
8. process of recording
9. condition
10. pertaining to
11. pertaining to
12. condition, process
13. to fall, slide
14. loosening, breakdown, separation, destruction
15. to measure
16. to send
17. death
18. tumor
19. pertaining to
20. birth
21. disease condition
22. to eat, swallow
23. to speak
24. formation
25. formation
26. paralysis
27. breathing
28. flow, discharge
29. process of visual examination

- 30. incision
- 31. to stand, place, stop, control
- 32. pressure
- 33. to put, place
- 34. pertaining to
- 35. nourishment; development
- 36. structure
- 37. urine condition
- 38. process, condition

Terminology Checkup

In your own words, write the answers on the lines provided. Confirm your answers and check the box next to each item when you know you've "got" it!

1. What is the difference between **antigens**, **antibodies**, and **antibiotics**?

2. Explain the difference between a **primary malignant tumor** in the lung and a **breast cancer metastasis** to the lung.

3. What is the difference between a **remission** and a **relapse** of a disease?

4. Define the term **paralysis**. Give meanings for the following terms: **hemiplegia**, **quadriplegia**, and **paraplegia**.

5. What is a **syndrome**? Name three syndromes.

Answers to Terminology Checkup

1. **Antigens** are foreign substances (bacteria, viruses, fungi) that stimulate white blood cells to make **antibodies**, which destroy the antigens.

Antibiotics, however, are medications produced *outside* the body to kill or inhibit the growth of antigens such as bacteria and other microorganisms.

2. A **primary malignant tumor** in the lung originates and grows in the lung. It is composed of lung cancer cells. A **breast cancer metastasis** in the lung originated in the breast and now has traveled to the lung. It is composed of breast cancer cells. A pathology report of the biopsy will reveal this distinction.

3. A **remission** is the *lessening or absence of disease symptoms* during an illness. Patients who have no signs or symptoms of illness are described as being "in remission."

A **relapse** is the *return of disease symptoms* (-LAPSE meaning to fall or slide) after a period of time.

4. **Paralysis** is the *loss of muscle function*. It can be caused by a cerebrovascular accident (stroke) or nerve damage in any part of the body. The suffix **-plegia** means *paralysis*. For example, **hemiplegia** (hemi means half) is paralysis of one side of the body, as occurs with a stroke. **Quadriplegia** is paralysis of all four (QUADRI- means four) limbs of the body when spinal nerves in the neck are damaged. **Paraplegia** is paralysis of the lower part of the body when there is damage to lower regions of the spinal cord.

5. A **syndrome** is a group of signs and symptoms that occur together indicating a particular condition, the cause of which is not always known. Examples are: **mitral valve prolapse syndrome**, **carpal tunnel syndrome**, and **acquired immunodeficiency syndrome (AIDS)**.



CHAPTER 5

Medical Specialists and Case Reports

CHAPTER SECTIONS

Introduction	176
Medical Specialists	176
Combining Forms and Vocabulary	179
Case Reports	184
In Person: Living With Crohn's	195
Exercises and Answers	196
Pronunciation of Terms	204
Practical Applications	207
Review	211
Terminology CheckUp	213

CHAPTER OBJECTIVES

- To describe the training process of physicians
- To identify medical specialists and describe their specialties
- To identify combining forms used in terms that describe specialists
- To decipher medical terminology as written in case reports

Introduction

This chapter reviews many of the terms you have learned in previous chapters and adds others related to medical specialists. In the following section, the training of physicians is described, and specialists are listed with their specialties. Next, on [page 179](#), useful combining forms are presented with terminology to increase your medical vocabulary. Finally, short case reports beginning on [page 184](#) illustrate the use of the medical language in context. As you read these reports, congratulate yourself on your understanding of medical terminology!

Medical Specialists

Doctors complete 4 years of medical school and then pass national medical board examinations to receive an MD degree (MD stands for Latin *Medicinae Doctor*, “teacher [doctor] of medicine”). They may then begin postgraduate training, which lasts at least 3 years, and in some cases, longer. This postgraduate training is known as *residency training*. Examples of residency programs are:

Anesthesiology	Administration of agents capable of bringing about a loss of sensation
Dermatology	Diagnosis and treatment of skin disorders
Emergency medicine	Care of patients that requires sudden and immediate action
Family practice	Primary care of all members of the family on a continuing basis
Internal medicine	Diagnosis and treatment of usually complex, nonsurgical disorders in adults
Ophthalmology	Diagnosis and treatment of eye disorders
Pathology	Diagnosis of the cause and nature of disease
Pediatrics	Diagnosis and treatment of children's disorders
Psychiatry	Diagnosis and treatment of disorders of the mind
Radiology	Diagnosis using x-ray studies, including ultrasound and magnetic resonance imaging (MRI)
Surgery	Treatment by manual (SURG- means hand) or operative methods

Examinations are administered after the completion of each residency program to certify the doctor's competency in that specialty area.

A physician may then choose to specialize further by doing *fellowship training*. Fellowship programs (lasting 2 to 5 years) train doctors in *clinical* (patient care) and research (laboratory) skills. For example, an *internist* (specialist in internal medicine) may choose fellowship training in internal medicine specialties such as neurology, nephrology, endocrinology, and oncology. A surgeon interested in further specialization may do fellowship training in thoracic surgery, neurosurgery, or plastic surgery. On completion of training and examinations, the doctor is then recognized as a specialist in that area of medical practice.

Medical specialists with explanations of their specialties are listed below:

Medical Specialist	Area of Practice
allergist	Treatment of hypersensitivity reactions
anesthesiologist	Administration of agents to prevent pain and unpleasant awareness during surgical and other procedures
cardiologist	Treatment of heart disease
cardiovascular surgeon	Surgery on the heart and blood vessels
colorectal surgeon	Surgery on the colon and rectum
dermatologist	Treatment of skin disorders
emergency practitioner	Immediate evaluation and treatment of acute injury and illness in a hospital setting
endocrinologist	Treatment of endocrine gland disorders
family practitioner	Primary care treatment for families on a continuing basis
gastroenterologist	Treatment of stomach and intestinal disorders
geriatrician	Treatment of diseases of old age
gynecologist	Surgery and treatment for diseases of the female reproductive system
hematologist	Treatment of blood disorders
hospitalist	General medical care of hospitalized patients
infectious disease specialist	Treatment of diseases caused by micro-organisms (bacteria, viruses, fungi, others)
internist	Adult comprehensive care in office of hospital setting
nephrologist	Treatment of kidney diseases
neurologist	Treatment of nerve disorders
neurosurgeon	Surgery on the brain, spinal cord, and nerves
obstetrician	Treatment of pregnant women; delivery of babies
oncologist	Diagnosis and treatment of malignant and benign tumors
ophthalmologist	Surgical and medical treatment of eye disorders
orthopedist	Surgical treatment of bone, muscle, and joint conditions
otolaryngologist	Surgical treatment of ear, nose, and throat disorders
pathologist	Diagnosis of disease by analysis of cells
pediatrician	Treatment of diseases of children
physiatrist	Treatment to restore function after injury or illness; physical medicine and rehabilitation specialist
psychiatrist	Treatment of mental disorders
pulmonologist	Treatment of lung diseases
radiologist	Examination of x-ray images for diagnosis; interpretation of ultrasound, MRI, and nuclear medicine studies
radiation oncologist	Treatment of disease with high-energy radiation
rheumatologist	Treatment of systemic diseases affecting joints and muscles
thoracic surgeon	Surgery on chest organs
urologist	Surgery on the urinary tract and for treatment of male reproductive disorders

Here are two groups of matching exercises for practice with this new terminology. Answers are found on

page 204.

A Match the medical specialists with the procedures and tests that they perform. Write the name of the specialist on the line provided.

allergist

anesthesiologist

cardiologist

cardiovascular surgeon

endocrinologist

gastroenterologist

gynecologist

hematologist

ophthalmologist

Procedure/Test	Medical Specialist
1. Esophagoscopy and colonoscopy	_____
2. Blood cell counts; bone marrow biopsy	_____
3. Ultrasound examination of the heart; angioplasty	_____
4. Skin testing to determine sensitivity to antigens	_____
5. Serum (blood) level of hormones	_____
6. Vision tests; retinoscopy	_____
7. Coronary artery bypass grafting (CABG)	_____
8. Catheter and IV line insertion for sedation during surgery	_____
9. Pap smear (microscopic examination of cells from the cervix and organs); hysterectomy	_____

B Match the medical specialists with the procedures and tests that they perform. Write the name of the specialist on the line provided.

neurologist

nephrologist

orthopedist

pathologist

psychiatrist

pulmonologist

radiologist

radiation oncologist

urologist

Procedure/Test	Medical Specialist
1. Nephrectomy; cystectomy; prostatectomy	_____
2. Personality and mental function tests	_____
3. Use of high-energy beams (photon and proton) to kill tumor cells	_____
4. Fixation of bone fracture; arthroscopic surgery	_____
5. Breathing function (spirometry) tests	_____

6. Microscopic examination of biopsy samples; autopsies	
7. CT scan; MRI; ultrasound examination	
8. Kidney function tests; dialysis	
9. Spinal and cranial nerve reflex tests	

Combining Forms and Vocabulary

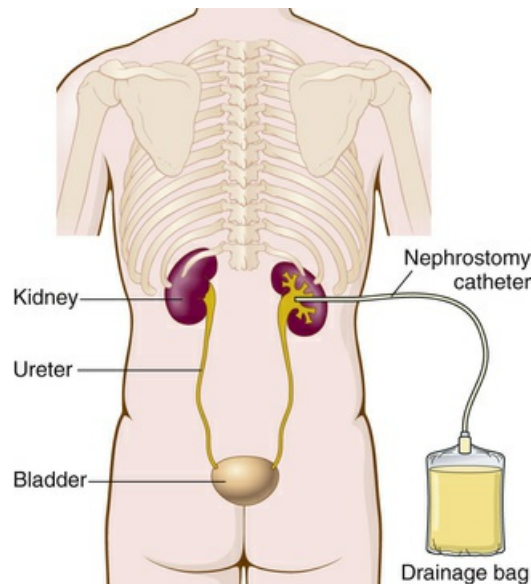
The combining forms below should be familiar because they are found in the listed terms describing medical specialists. A medical term is included to illustrate the use of the combining form. Write the meaning of the medical term in the space provided. You can always check your answers with the *Mini-Dictionary* beginning on [page 349](#).

Combining Form	Meaning	Medical Term	Meaning
cardi/o	heart	cardiomegaly _____	
col/o	colon (large intestine)	colitis _____	

Ulcerative Colitis and Crohn Disease (Crohn's)

Both of these conditions are types of **inflammatory bowel disease (IBD)**, with similar signs and symptoms, such as abdominal pain, diarrhea, and bleeding from the rectum. While **ulcerative colitis** is confined to the colon, **Crohn's** commonly affects the last part of the small intestine and may involve other areas of the gastrointestinal tract. Lesions can be identified, but causes of both types of IBD are unknown. See *In Person: Living with Crohn's* on [page 195](#).

dermat/o	skin	dermatitis _____
endocrin/o	endocrine glands	endocrinology _____
enter/o	intestines	enteritis _____
esthesi/o	sensation	anesthesiology _____
gastr/o	stomach	gastroscopy _____
ger/o	old age	geriatrics _____
gynec/o	woman, female	gynecology _____
hemat/o	blood	hematoma _____
iatr/o	treatment	iatrogenic _____ IATR/O means treatment by a physician or with medicines. An iatrogenic condition is produced (-GENIC) adversely by a treatment.
laryng/o	voice box	laryngeal _____
lymph/o	lymph	lymphadenopathy _____ Lymph "glands" are actually lymph nodes , located all over the body but especially in axillary (armpit), inguinal (groin), cervical (neck), and mediastinal (area between the lungs) regions. Lymphadenopathy often refers to the presence of malignant cells in lymph nodes.
nephro/o	kidney	nephrostomy _____ A catheter (tube) is inserted into the kidney for drainage of fluid. See Figure 5-1 .



neur/o	nerve	neuralgia _____
nos/o	disease	nosocomial _____ A nosocomial infection is acquired during hospitalization (COMI/O means to care for).
obstetr/o	midwife	obstetric _____
odont/o	tooth	orthodontist _____ ORTH/O means straight.

Dental Specialists

The following are other specialists in dental medicine:

Dental Specialist	Area of Expertise
periodontist	Gums (PERI- means surrounding)
endodontist	Root canal therapy (the root canal is the inner part of a tooth containing blood vessels and nerves)
pedodontist	Children (PED/O means child)
prosthodontist	Replacement of missing teeth with artificial appliances (PROSTH/O = artificial replacement)

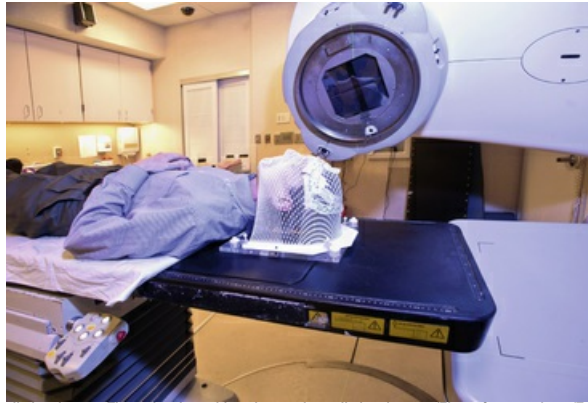

FIGURE 5-2 Radiation therapy. The patient is positioned to receive radiation therapy. (Figure from stanley45/E+Getty Images.)

onc/o	tumor	<u>oncogenic</u> _____ <i>Oncogenic viruses give rise to tumors.</i>
ophthalm/o	eye	<u>ophthalmologist</u> _____
opt/o	eye	<u>optometrist</u> _____ <i>An optometrist examines (METR/O means to measure) eyes and prescribes corrective lenses but cannot treat eye diseases.</i>
optic/o	eye	<u>optician</u> _____ <i>Opticians grind lenses and fit glasses, and may treat eye diseases.</i>
orth/o	straight	<u>orthopedist</u> _____ <i>PED/O comes from paidos, the Greek word for "child." In the past, orthopedists were concerned with straightening bone deformities in children. Today, they treat bone, muscle, and joint disorders in adults as well.</i>
ot/o	ear	<u>otitis</u> _____
path/o	disease	<u>pathology</u> _____
ped/o	child	<u>pediatrics</u> _____
psych/o	mind	<u>psychosis</u> _____
pulmon/o	lung	<u>pulmonary</u> _____
radi/o	x-rays	<u>radiotherapy</u> _____ <i>Radiotherapy is also called radiation therapy. See Figure 5-2.</i>
rect/o	rectum	<u>rectocele</u> _____ <i>-CELE means a hernia or protrusion. The walls of the rectum weaken and bulge forward toward the vagina. See Figure 5-3.</i>

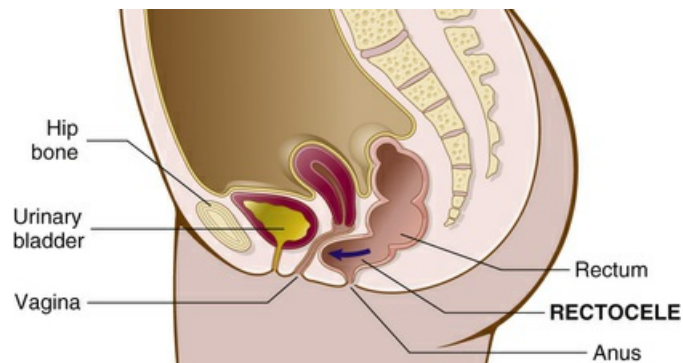
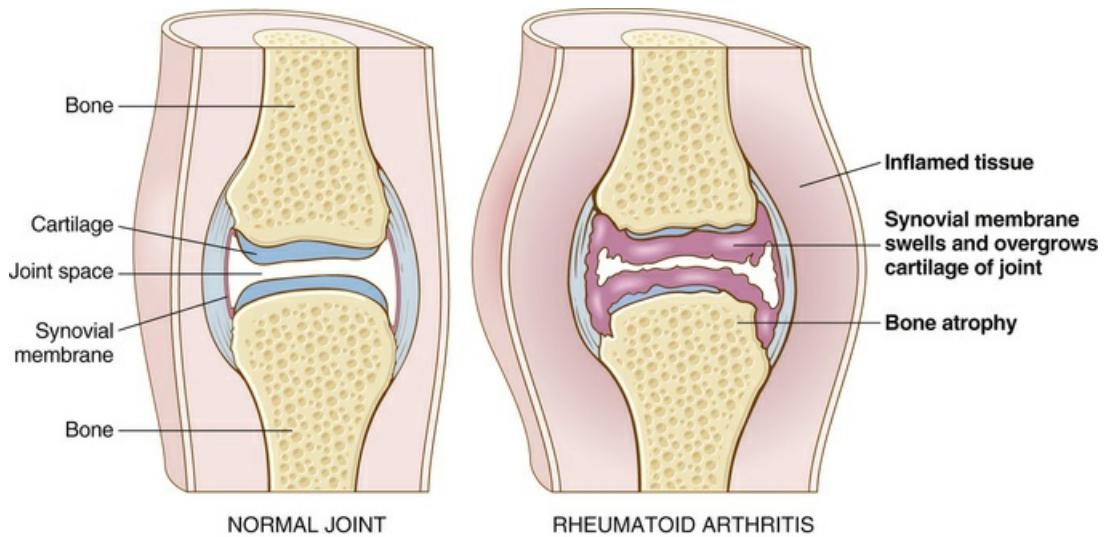


FIGURE 5-3 Rectocele. (Modified from Chabner D-E: *The Language of Medicine*, ed 11, St. Louis, 2017, Elsevier.)



rheumat/o	flow, fluid	<u>rheumatology</u> _____ <i>Joints can fill with fluid when diseased—hence, RHEUMAT/O indicates a problem with a swollen joint. Rheumatoid arthritis is a chronic inflammatory disease of joints and connective tissues that leads to deformation of joints. See Figures 5-4 and 5-5.</i>
------------------	-------------	---

Rheumatoid Arthritis and Osteoarthritis

Rheumatoid arthritis first appears when patients (often women) are young, and it has an autoimmune component (antibodies are found that destroy joint tissue). **Osteoarthritis** most often appears in older patients (both men and women) and is marked by degenerative changes that cause destruction of the joint space (see [Chapter 1, page 13](#)). Knee and hip replacements may be helpful treatments for patients with osteoarthritis.

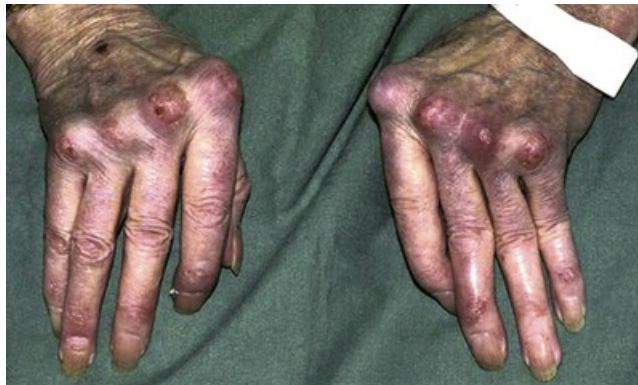

FIGURE 5-5 Advanced rheumatoid arthritis of the hands. Notice the soft tissue swelling and deformed joints—fingers, knuckles, and wrist. Atrophy of muscles and tendons (connecting muscles to bones) allows one joint surface to slip past the other (subluxation). (From Currie G, Douglas G: *The Flesh and Bones of Medicine*, St. Louis, Mosby, 2011.)

rhin/o	nose	<u>rhinorrhea</u> _____
thorac/o	chest	<u>thoracotomy</u> _____
ur/o	urinary tract	<u>urology</u> _____
vascul/o	blood vessels	<u>vasculitis</u> _____

Case Reports

Here are short case reports related to medical *specialties*. Many of the terms will be familiar to you; others are explained in the *Mini-Dictionary* (beginning on page 349). For every case report, write the meaning of the **boldface** terms in the spaces provided.

Case 1

Cardiology

Mr. Rose was admitted to the cardiac care unit (CCU) with **angina** and a history of **hypertension**.

A **coronary angiogram** (Figure 5-6, A) showed **spasm** of the right coronary artery (closed arrow), causing **acute myocardial ischemia**. The electrocardiogram (ECG) showed **ventricular arrhythmias** as well.

Nitroglycerin was administered, and within minutes, the angiogram showed reversal of the spasm (Figure 5-6, B). The ECG recorded reversal of the life-threatening arrhythmias as well. To prevent further ischemia and **myocardial infarction**, Mr. Rose's treatment will include **antiarrhythmic**, **diuretic**, and **anticoagulant** drugs. In the future, he may need an additional procedure to place a **stent** in his coronary artery to keep it open.

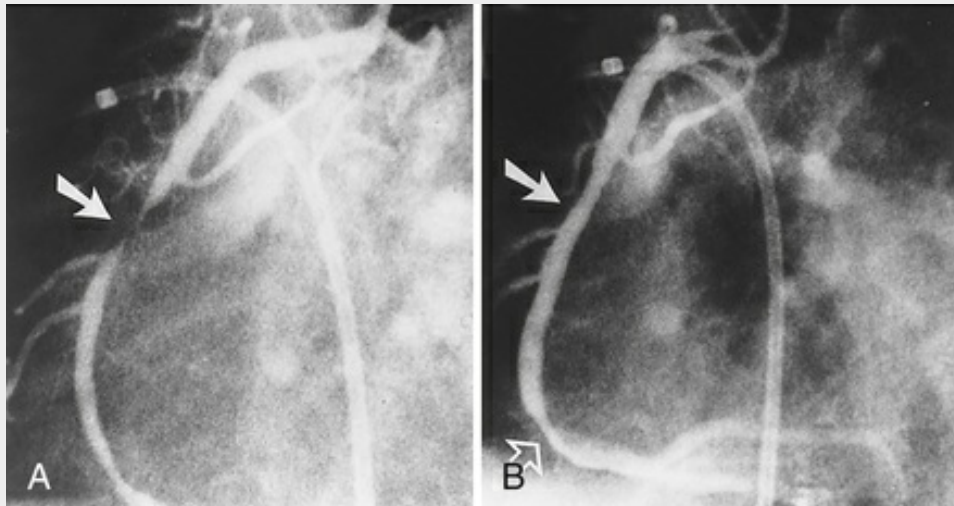


FIGURE 5-6 A, Coronary angiogram showing spasm of the right coronary artery (arrow). B, Angiogram showing reversal of the spasm (arrow). (A and B, From Zipes DP, et al: *Braunwald's Heart Disease: A Textbook of Cardiovascular Medicine*, ed 7, Philadelphia, 2005, Saunders.)

acute myocardial ischemia _____
angina _____
antiarrhythmic _____
anticoagulant _____
coronary angiogram _____
diuretic _____
hypertension _____
myocardial infarction _____
nitroglycerin _____
spasm _____
stent _____
ventricular arrhythmias _____

Case 2

Gynecology

Ms. Sessions has had **dysmenorrhea** and **menorrhagia** for several months. She is also **anemic**. Because of the presence of a **large fibroid**, as seen on a pelvic **ultrasound** image (**sonogram**) (see

Figure 5-7, A), a **hysterectomy** was recommended. After it was removed, the uterus was opened to reveal multiple fibroids (**leiomyomas**) bulging into the uterine cavity and displaying a firm, white appearance. See Figure 5-7, B.

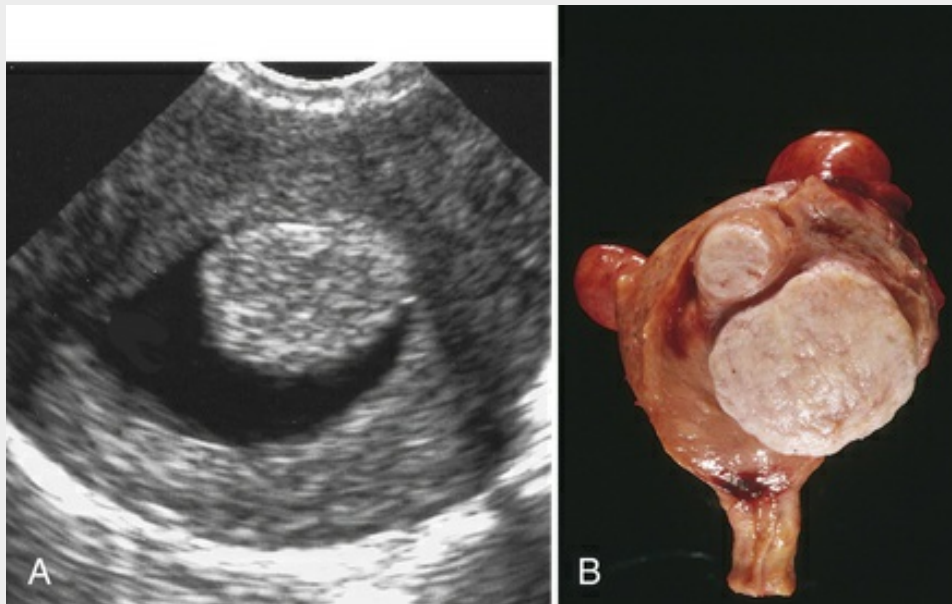


FIGURE 5-7 A, Pelvic sonogram. B, Fibroids (leiomyomas). These are benign tumors of the uterus. (A, From Salem S: The uterus and adnexa. In Rumack CM, Wilson SR, Charboneau JW, editors: *Diagnostic Ultrasound*, ed 2, St. Louis, 1998, Mosby. B, From Cotran RS, Kumar V, Collins T: *Robbins' Pathologic Basis of Disease*, ed 6, Philadelphia, 1999, Saunders.)

- anemic _____
- dysmenorrhea _____
- fibroids _____
- hysterectomy _____
- leiomyomas _____
- menorrhagia _____
- sonogram _____
- ultrasound _____

Case 3

Oncology

John Smith, a 26-year-old law student, was admitted to the hospital after experiencing several months of **fatigue**, low-grade fevers, chest pain, and night sweats. A chest **MRI** scan (see Figure 5-8) revealed large **mediastinal** masses, as shown by arrows. **Needle biopsy** confirmed a diagnosis of **Hodgkin lymphoma**. There was no evidence of **lymphadenopathy** or **hepatic** involvement. Treatment included **chemotherapy** followed by **radiotherapy** to the chest. Mr. Smith's **prognosis** is good.

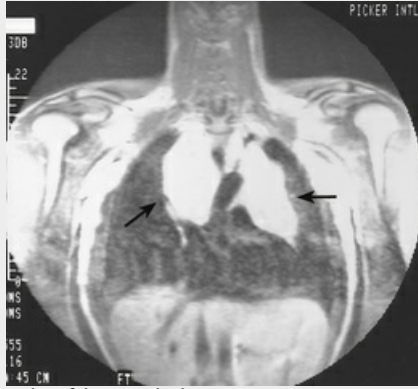


FIGURE 5-8 Magnetic resonance imaging of the upper body. (From Chabner D-E: *The Language of Medicine*, ed 11, St. Louis, 2017, Elsevier.)

- chemotherapy _____
- diagnosis _____
- fatigue _____
- hepatic _____
- Hodgkin lymphoma _____
- lymphadenopathy _____
- mediastinal _____
- MRI _____
- needle biopsy _____
- prognosis _____
- radiotherapy _____

Case 4

Urology

Scott Jones has a history of lower back pain, associated with **hematuria** and **dysuria**. An abdominal x-ray film (Figure 5-9, A) shows a **renal calculus** (black arrow) in the right upper quadrant. His doctor tells him that renal calculi should be suspected any time a calcification is seen within the renal outline or along the expected course of the **ureter** (dotted lines).

Treatment with shock wave **lithotripsy** (Figure 5-9, B) is expected to crush the stone and relieve his **symptoms**.

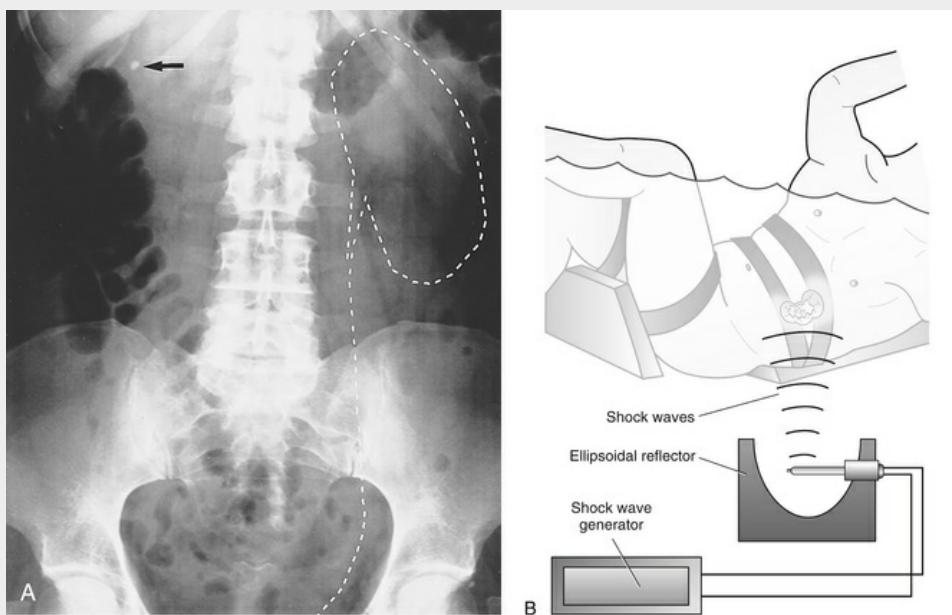


FIGURE 5-9 A, An abdominal x-ray image showing a **renal calculus** (arrow). B, **Lithotripsy**. (A, From Mettler FA: *Essentials of Radiology*, ed 2, Philadelphia, 2005, Saunders. B, From Rakel D: *Integrative Medicine*, ed 2, Philadelphia, 2007, Saunders.)

dysuria _____
 hematuria _____
 lithotripsy _____
 renal calculus _____
 symptoms _____
 ureter _____

Case 5

Gastroenterology

Mr. Pepper suffers from **dyspepsia**, acid reflux, and sharp **abdominal** pain. A recent episode of **hematemesis** has left him very weak and **anemic**. **Gastroscopy** and an **upper GI series with barium** revealed the presence of a large **ulcer**. **Figure 5-10** is a photograph of a peptic ulcer located in the stomach. Mr. Pepper will be admitted to the hospital and treated with medication to reduce gastric acid output and with antibiotics to control a bacterium (*Helicobacter*, or *H. pylori*) known to cause ulcers. He will also be scheduled for a partial **gastrectomy**.

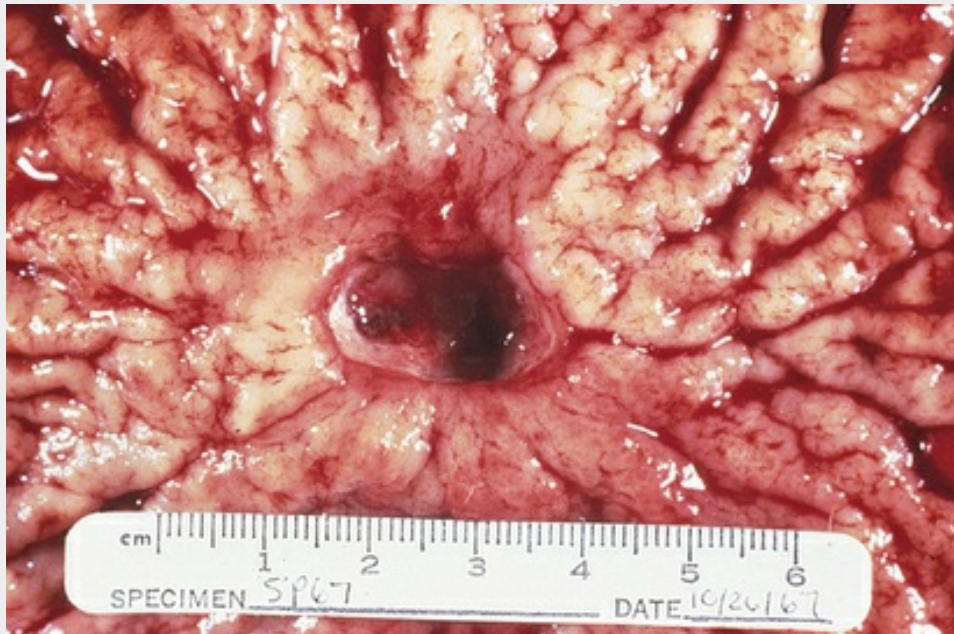

FIGURE 5-10 Peptic (gastric) ulcer. (From Lewis SM, Heitkemper MM, Dirksen SR: *Medical-Surgical Nursing: Assessment and Management of Clinical Problems*, ed 5, St. Louis, 2004, Mosby.)

abdominal _____
 anemic _____
 barium _____
 dyspepsia _____
 gastrectomy _____
 gastroscopy _____
 hematemesis _____
 ulcer _____
 upper GI series _____

Case 6

Radiology

Evaluation of David Green's **posteroanterior** chest x-ray film (**Figure 5-11, A**, arrows) shows an ill-defined mass near the right **hilum**. The **lateral** view (**Figure 5-11, B**, arrows) also shows the mass, and its shaggy outline is very suggestive of **carcinoma**. Further evaluation by **CT scan** (**Figure 5-11, C**) clearly shows the mass in relation to the **mediastinal** structures such as the **pulmonary artery** (PA) and **aorta** (Ao).

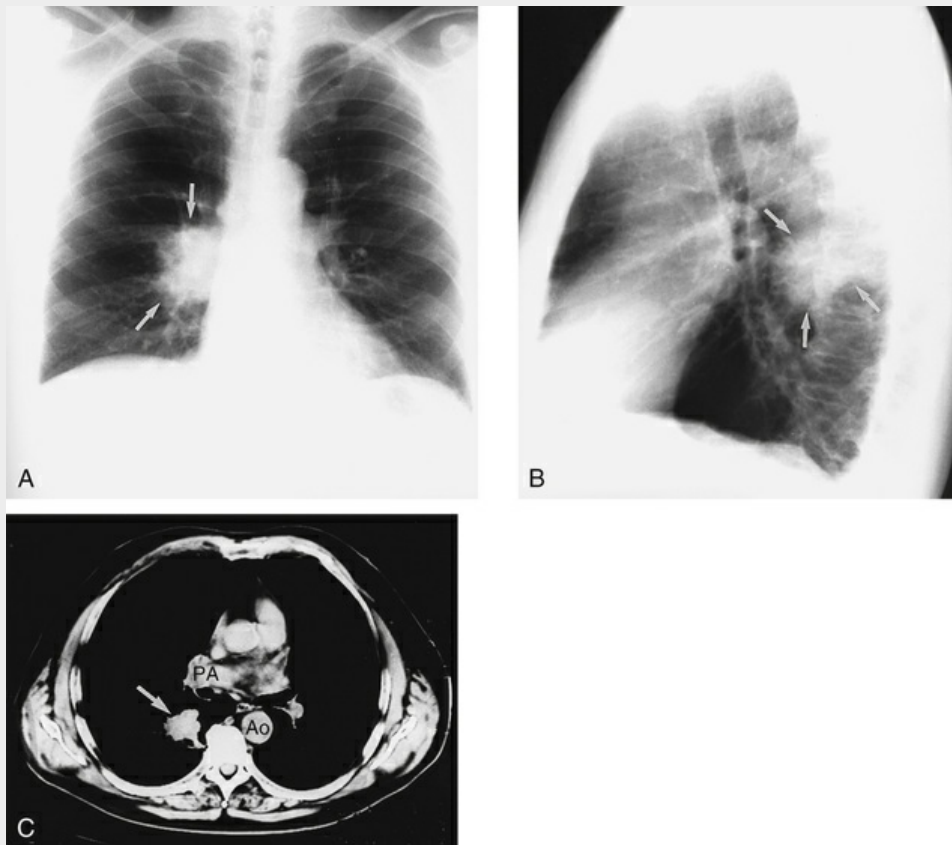


FIGURE 5-11 A, Posteroanterior chest x-ray view shows an ill-defined mass (arrows). B, Lateral chest x-ray view clearly shows the mass to be posterior to the hilum. C, Computed tomography image clearly shows the mass (arrow) in relation to the mediastinal structures. (A-C, From Mettler FA: *Essentials of Radiology*, ed 2, Philadelphia, 2005, Saunders.)

Impression: Lung cancer.

- aorta _____
- carcinoma _____
- CT scan _____
- hilum _____
- lateral _____
- mediastinal _____
- posteroanterior _____
- pulmonary artery _____

Case 7

Endocrinology

A 36-year-old woman known to have **type 1 diabetes mellitus** was brought to the emergency department after being found collapsed at home. She had experienced 3 days of extreme weakness, **polyuria**, and **polydipsia**. It was discovered that a few days before her admission, she had discontinued use of her external **insulin pump** (see [Figure 5-12](#)).

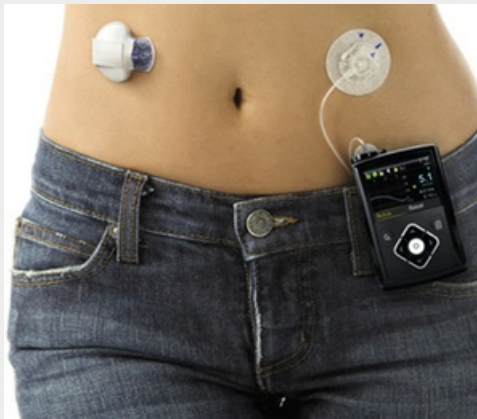

FIGURE 5-12 External insulin pump. The device on the patient's right side is an insulin sensor which continuously monitors insulin levels and communicates with the insulin pump. (Provided by Medtronic.)

insulin pump _____
 polydipsia _____
 polyuria _____
 type 1 diabetes mellitus _____

Case 8

Orthopedics

A 20-year-old male patient was admitted to the hospital after a motorcycle accident. He was found to have **fractures** of the right **fibula** (see [Figure 5-13, A](#)), right **femur**, and **pelvis** and **intra-abdominal** injuries. He was taken to surgery, and internal **fixation** of the right femur was performed. A cast was applied to the femur for immobilization, and the fibula healed on its own with **callus** formation ([Figure 5-13, B](#)).

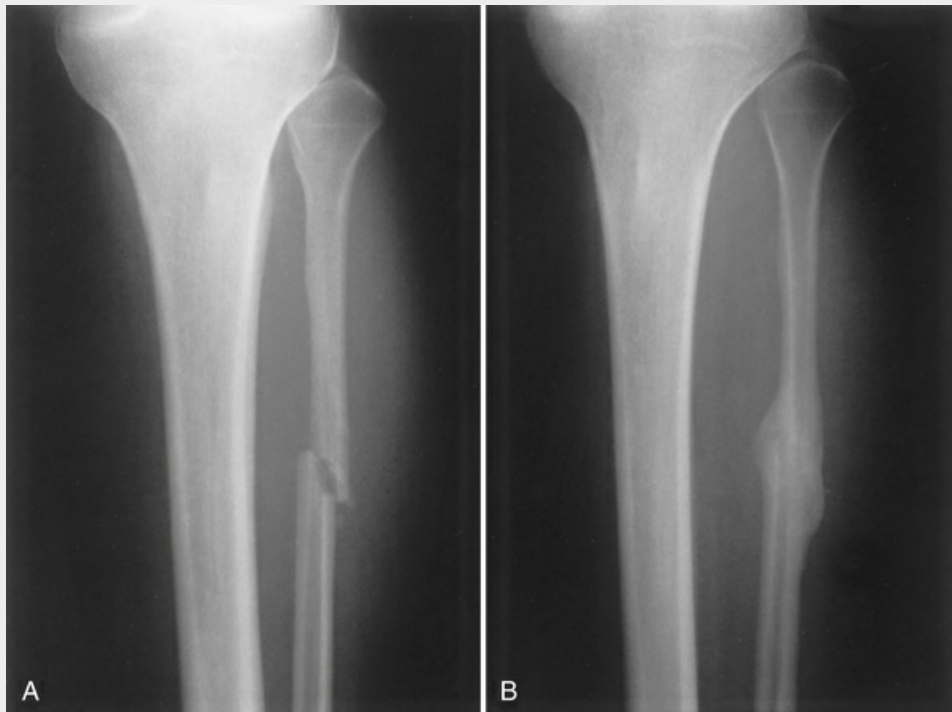


FIGURE 5-13 **A**, Fracture of the fibula. **B**, Callus formation, 6 weeks later. (Courtesy Dr. Barbara Weissman, Brigham and Women's Hospital, Boston, Massachusetts. **A** and **B**, From Cotran RS, Kumar V, Collins T: *Robbins' Pathologic Basis of Disease*, ed 6, Philadelphia, 1999, Saunders.)

callus _____
 femur _____

fibula _____
fixation _____
fracture _____
intra-abdominal _____
pelvis _____

Case 9

Nephrology

A 52-year-old woman with **chronic renal failure** secondary to long-standing **hypertension** has been maintained on **hemodialysis** for the past 18 months. An **arteriovenous fistula** (Figure 5-14) was created surgically to provide long-term vascular access for hemodialysis. For the past 3 weeks, during the dialysis sessions, she has become moderately **hypotensive**, with symptoms of dizziness. Consequently, we have decided to withhold her **antihypertensive** medications before dialysis.

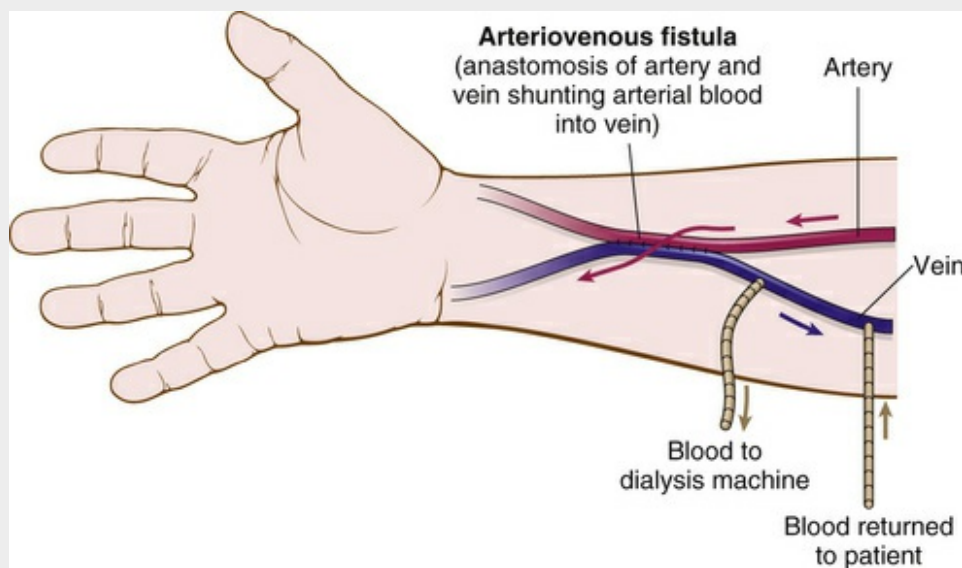


FIGURE 5-14 Arteriovenous fistula created for hemodialysis. (From Chabner D-E: *The Language of Medicine*, ed 11, St. Louis, 2017, Elsevier.)

antihypertensive _____
arteriovenous fistula _____
chronic _____
hemodialysis _____
hypertension _____
hypotensive _____
renal failure _____

Case 10

Neurology

Ms. Kindrick is admitted with severe, throbbing **unilateral frontal cephalgia** that has lasted for 2 days. Light makes her cringe, and she has **nausea**. Before the onset of these symptoms, she saw zigzag lines for about 20 minutes and a **scotoma** (see Figure 5-15). Diagnosis is **acute migraine with aura**. A **vasoconstrictor** is prescribed, and Ms. Kindrick's condition is improving. [Migraine headaches are thought to be caused by sudden **dilation** of blood vessels.]




FIGURE 5-15 Scotoma. This abnormal area of the visual field is both “positive” (consisting of bright flickering imagery) and “negative” (displaying a relatively dark area that obscures the visual field). It is called a scintillating scotoma. (From Yanoff M, Duker JS: *Ophthalmology*, ed 2, St. Louis, 2004, Mosby.)

- acute _____
- aura _____
- cephalgia _____
- dilation _____
- frontal _____
- migraine _____
- nausea _____
- scotoma _____
- unilateral _____
- vasoconstrictor _____

In Person: Living With Crohn's



When a friend told me she was felled by the flu yesterday, I was jealous. To someone with a chronic illness, like me, having something acute always seems luxurious. Lie in bed, read glossy magazines, take over-the-counter meds, sleep it off, and in a matter of days you're okay. I have Crohn disease, a chronic inflammation of the small intestine, which is characterized by flare-ups and remission. During flare-ups, I've experienced fever, diarrhea, vomiting, pain, and intestinal obstruction. Even in remission I am never "okay."

Right now I have been in remission two years after a third surgery to remove yet another portion of my small bowel. This time internal bleeding, a rather rare symptom of Crohn's, necessitated the surgery. I was enduring weekly iron infusions, which turned into bimonthly blood transfusions, as my hemoglobin plummeted to 6 (12 is normal). It was no way to live. After the surgery, the bleeding stopped, but I had bouts of urgent, watery diarrhea for a year. That was no way to live either, and unfortunately, as wonderful as my doctor is, I've found that few physicians want to address after-effects of small bowel surgery. After visiting several doctors and by trial-and-error, I finally got these symptoms under control with codeine, Lomotil, and Metamucil, but I will never be able to absorb vitamin B₁₂, so I must inject it monthly for the rest of my life. In addition to taking medicine to cope with having less and less small bowel, I take medicine in the hopes of preventing the next flare-up. Every few weeks, I inject myself with a biologic medicine, Humira, but I must eventually be weaned off this drug because it has possible long-term side effects, the scariest of which is lymphoma. At 52 and with two school-age children, however, I have learned to think of valuing my present quality of life the most, over possible unknown dangers lurking in the future.

I do often think about the past. What would my life be like if our family doctor hadn't told my parents that my constant episodes of diarrhea—which occurred since I was a child—were caused by "nerves?" By the time I was 21, my weight had dropped below 100 pounds, and I was twisted in pain after every meal. My dad arranged for me to visit his own doctor, who gave me a small bowel series that showed I had Crohn's, and that a portion of my small intestine was "as narrow as a pencil." By then it was too late for even prednisone (then the drug of choice despite side effects ranging from puffy face to psychosis) to open up the inflamed passage, and I had my first surgery just months after I was diagnosed. Thinking of those times—as well as all the other flare-up times—makes me flinch. While you can never relive pain, you can remember what it felt like. In my case, it was as if a large metal bike lock chain was being forced through my tender gut.

Before that first surgery, I was just out of college and longing to make my mark on the world, but I spent most of my evenings curled up in my small bedroom, listening to the soothing strains of "Make Believe Ballroom Hour" on the radio. Or, because vomiting and diarrhea usually accompanied the pain, I lay with my back pressed against the cold tiles of the bathroom floor. Later on, as a mom with two young children, I would lie on the couch watching life swirl around me, feeling guilty that I could not take part.

There was a silver lining to those flare-ups, and that is the tender affection of those around me: husband, family, and friends. When you have Crohn's, no one knows you have it until things get unbearable. It's not the kind of illness you discuss, but when you have pain and fever, you can kind of approximate those times of being felled by the flu. Yet you know that it will take more than a dose of Nyquil or a night's sleep to get "better." You know you'll face another course of medications—often untried ones—or that you will likely end up in the hospital undergoing yet another surgery.

Nancy J. Brandwein is a writer, editor, and food columnist.

🔍 Exercises and Answers

Complete these exercises and check your answers. An important part of your success in learning medical terminology is checking your answers carefully with the Answers to Exercises beginning on page 203.

A Match each of the listed residency programs to its description that follows.

anesthesiology

dermatology

emergency medicine

family practice

internal medicine

ophthalmology

pathology

pediatrics

psychiatry

radiology

surgery

1. Treatment by operation or manual (hand) methods _____
2. Diagnosis and treatment of often complex medical disorders in adult patients _____
3. Diagnosis and treatment of disorders of the mind _____
4. Primary care of all family members on a continuing basis _____
5. Diagnosis and treatment of skin disorders _____
6. Diagnosis and treatment of eye disorders _____
7. Diagnosis of disease using x-rays _____
8. Diagnosis and treatment of children's disorders _____
9. Care of patients with illness that requires immediate action _____
10. Administration of agents that produce loss of sensation/awareness _____
11. Diagnosis of disease by examining cells and tissues _____

B Name the physician who treats the following problems (first letters are given).

1. kidney diseases: **n**_____

2. tumors: **o** _____
3. broken bones: **o** _____
4. female diseases: **g** _____
5. eye disorders: **o** _____
6. heart disorders: **c** _____
7. nerve disorders: **n** _____
8. lung disorders: **p** _____
9. mental disorders: **p** _____
10. stomach and intestinal disorders: **g** _____

C Match the medical specialists in Column I to their area of practice in Column II.

Column I	Column II
1. urologist	A. operates on the large intestine
2. thoracic surgeon	B. treats blood disorders
3. radiation oncologist	C. treats thyroid and pituitary gland disorders
4. colorectal surgeon	D. rehabilitates after spinal injuries
5. endocrinologist	E. treats disorders of childhood
6. obstetrician	F. operates on the urinary tract
7. radiologist	G. treats disorders of the skin
8. pediatrician	H. delivers babies
9. hematologist	I. operates on the chest
10. dermatologist	J. examines x-ray images to diagnose disease
11. physiatrist	K. treats tumors using high-energy radiation

D Complete each of the sentences that follow using a term from the list below.

- clinical
- geriatrician
- hospitalist
- infectious disease specialist
- oncologist
- ophthalmologist
- optician
- optometrist
- pathologist
- research
- surgeon
- orthopedist

1. A doctor who diagnoses and treats diseases that are caused by micro-organisms is a/an _____.
2. A doctor who performs bone surgery is a/an _____.
3. A doctor who takes care of patients practices _____ medicine.
4. A medical professional who grinds lenses and fills prescriptions for eye glasses is a/an _____.
5. A doctor who reads biopsy samples and performs autopsies is a/an _____.
6. A doctor who treats cancerous tumors is a/an _____.
7. A medical professional (nonphysician) who examines eyes, prescribes eyeglasses, and treats eye disorders is a/an _____.
8. A doctor who operates on patients is a/an _____.
9. A doctor who does experiments with test tubes and laboratory equipment is interested in _____ medicine.
10. A doctor who specializes in surgery and medical treatment of disorders of the eye is a/an _____.
11. A doctor who specializes in the treatment of older people is a/an _____.
12. A physician who cares for hospitalized patients is a/an _____.

E Which medical specialist would you consult for the following medical conditions? The first letter of the specialist is given.

1. Arthritis:	r _____
2. Otitis media:	o _____
3. Anemia:	h _____
4. Urinary bladder displacement:	u _____
5. Chronic bronchitis:	p _____
6. Cerebrovascular accident:	n _____
7. Breast cancer:	o _____
8. Coronary artery blockages (bypass surgery):	c _____
9. Dislocated shoulder bone:	o _____
10. Thyroid gland enlargement:	e _____
11. Kidney disease:	n _____
12. Acne (skin disorder):	d _____
13. Hay fever (hypersensitivity reaction):	a _____
14. Viral and bacterial diseases:	i _____
15. Rehabilitation after herniated disk:	p _____

F Give the meaning for each of the following medical terms.

1. neuralgia _____
2. pathology _____
3. cardiomegaly _____
4. nephrostomy _____

5. thoracotomy _____
6. laryngeal _____
7. otitis _____
8. colitis _____
9. pulmonary _____
10. iatrogenic _____
11. gastroscopy _____
12. radiotherapy _____
13. anesthesiology _____
14. enteritis _____
15. nosocomial _____

G Use the following combining forms and suffixes to make the medical terms called for.

Combining Forms		Suffixes	
aden/o	onc/o	-algia	-pathy
col/o	ophthalm/o	-ectomy	-scopy
laryng/o	ot/o	-genic	-stomy
lymph/o	path/o	-itis	-therapy
neph/r/o	psych/o	-logy	-tomy
neur/o	thorac/o	-osis	

1. Inflammation of the ear: _____
2. Removal of a nerve: _____
3. Incision of the chest: _____
4. Study of tumors: _____
5. Pertaining to producing disease: _____
6. Inflammation of the voice box: _____
7. Opening of the large intestine to the outside of the body: _____
8. Visual examination of the eye: _____
9. Abnormal condition of the mind: _____
10. Inflammation of the kidney: _____
11. Removal of the large intestine: _____
12. Pain in the ear: _____
13. Treatment of the mind: _____

14. Pertaining to producing tumors: _____

15. Disease of lymph glands (nodes): _____

H Circle the bold term that best completes the meaning of the sentences in the following medical vignettes.

1. Dr. Butler is a physician who operates on hearts. He trained as a **(neurologic, cardiovascular, pulmonary)** surgeon. Often, his procedures require that Dr. Smith, a/an **(gynecologic, ophthalmic, thoracic)** surgeon, assist him when the surgical problem involves the chest and lungs.
2. Pauline noticed a rash over most of her body. First she saw Dr. Cole, her **(family practitioner, oncologist, radiologist)**, who performs her yearly physicals. Dr. Cole, who is not a/an **(endocrinologist, orthopedist, dermatologist)** by training, referred her to a skin specialist to make the proper diagnosis and treat the rash.
3. Dr. Liu is a/an **(internist, obstetrician, pediatrician)** as well as a/an **(nephrologist, urologist, gynecologist)** and can take care of her female patients before, during, and after their pregnancies.
4. After her sixth pregnancy, Sally developed an abnormal condition at the lower end of her colon. She went to a/an **(gastroenterologist, hematologist, optometrist)**, who made the diagnosis of protrusion of the rectum into the vagina. She then consulted colorectal and gynecologic surgeons to make an appropriate treatment plan for her condition, known as a **(vasculitis, rectocele, colostomy)**.
5. In the cancer clinic, patients often see a medical **(oncologist, orthopedist, rheumatologist)**, who prescribes and monitors chemotherapy, and a/an **(pulmonologist, radiation oncologist, radiologist)**, a physician who prescribes and supervises the use of **(drugs, surgery, radiation)** to treat tumors with high-energy beams.
6. During a lengthy hospitalization, Janet developed a cough and fever (unrelated to any treatment or procedure she received). Her surgeon ordered a chest x-ray, which showed a/an **(oncogenic, nosocomial, iatrogenic)** pneumonia. A/an **(anesthesiologist, neurologist, infectious disease specialist)** was called in to diagnose and treat the hospital-acquired disease condition.
7. Sam had noticed bright red rectal bleeding for several days when he finally saw his family practitioner. This physician referred him to a/an **(endocrinologist, urologist, gastroenterologist)**. A **(laparoscopy, colonoscopy, bronchoscopy)** was scheduled, which revealed a large pedunculated (on a stalk) polyp (benign growth) in the descending colon. See [Figure 5-16](#). The polyp was resected and sent to the **(pathology, hematology, infectious disease)** department for evaluation. Fortunately, it was a noncancerous or **(malignant, metastatic, benign)** lesion. Sam will need follow-up **(laparotomy, endoscopy, laparoscopy)** in a year.

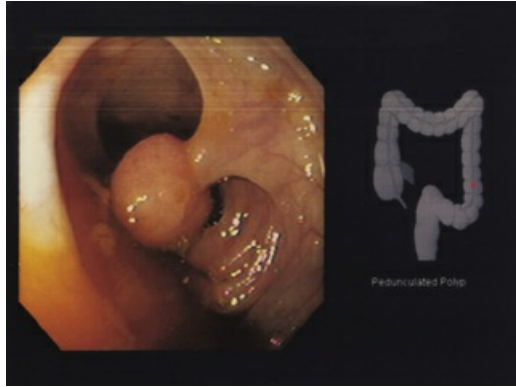


FIGURE 5-16 Pedunculated polyp in the descending colon. It arises from the mucosal surface of the colon and is projecting into the lumen of the colon. (From Lewis SM, Heitkemper MM, Dirksen SR: *Medical-Surgical Nursing: Assessment and Management of Clinical Problems*, ed 5, St. Louis, 2004, Mosby.)

Answers to Exercises

A

1. surgery
2. internal medicine
3. psychiatry
4. family practice
5. dermatology
6. ophthalmology
7. radiology
8. pediatrics
9. emergency medicine
10. anesthesiology
11. pathology

B

1. nephrologist
2. oncologist
3. orthopedist
4. gynecologist
5. ophthalmologist
6. cardiologist (internist) or cardiovascular surgeon (surgeon)
7. neurologist
8. pulmonary specialist

9. psychiatrist
10. gastroenterologist

C

1. F
2. I
3. K
4. A
5. C
6. H
7. J
8. E
9. B
10. G
11. D

D

1. infectious disease specialist
2. orthopedist
3. clinical
4. optician
5. pathologist
6. oncologist
7. optometrist
8. surgeon
9. research
10. ophthalmologist
11. geriatrician
12. hospitalist

E

1. rheumatologist
2. otolaryngologist
3. hematologist

4. urologist
5. pulmonary specialist
6. neurologist
7. oncologist
8. cardiovascular surgeon
9. orthopedist
10. endocrinologist
11. nephrologist
12. dermatologist
13. allergist
14. infectious disease specialist
15. physiatrist

F

1. nerve pain
2. study of disease
3. enlargement of the heart
4. opening from the kidney to the outside of the body
5. incision of the chest
6. pertaining to the voice box
7. inflammation of the ear
8. inflammation of the colon
9. pertaining to the lungs
10. pertaining to an abnormal condition that is produced by treatment
11. process of visual examination of the stomach (using an endoscope)
12. treatment of disease using high-energy radiation
13. study of loss of sensation or feeling
14. inflammation of the intestines (usually small intestine)
15. pertaining to a disease acquired in the hospital

G

1. otitis
2. neurectomy

3. thoracotomy
4. oncology
5. pathogenic
6. laryngitis
7. colostomy
8. ophthalmoscopy
9. psychosis
10. nephritis
11. colectomy
12. otalgia
13. psychotherapy
14. oncogenic
15. lymphadenopathy

H

1. cardiovascular, thoracic
2. family practitioner, dermatologist
3. obstetrician, gynecologist
4. gastroenterologist, rectocele
5. oncologist, radiation oncologist, radiation
6. nosocomial, infectious disease specialist
7. gastroenterologist, colonoscopy, pathology, benign, endoscopy

Medical Specialists Matching Exercises (on pages 178-179)

A

1. gastroenterologist
2. hematologist
3. cardiologist
4. allergist
5. endocrinologist
6. ophthalmologist
7. cardiovascular surgeon
8. anesthesiologist

9. gynecologist

B

1. urologist

2. psychiatrist

3. radiation oncologist

4. orthopedist

5. pulmonologist

6. pathologist

7. radiologist

8. nephrologist

9. neurologist

■ Pronunciation of Terms

The terms that you have learned in this chapter are presented here with their pronunciations. The capitalized letters in **BOLDFACE** represent the accented syllable. Pronounce each word out loud; then write the meaning in the space provided. Meanings of all terms can be checked with the *Mini-Dictionary* beginning on page 349 and on the audio section of the *Evolve* website (<http://evolve.elsevier.com/Chabner/medtermshort>).

Term	Pronunciation	Meaning
anesthesiology	an-es-the-ze- OL -o-je	
cardiologist	kar-de- OL -o-jist	
cardiovascular surgeon	kar-de-o- VAS -ku-lar SUR -jun	
clinical	KLIN -ih-kal	
colitis	ko- LI -tis	
colorectal surgeon	ko-lo- REK -tal SUR -jun	
dermatologist	der-mah- TOL -o-jist	
dermatology	der-mah- TOL -o-je	
emergency medicine	e- MER -jen-se MED -ih-sin	
endocrinologist	en-do-krih- NOL -o-jist	
enteritis	en-teh- RI -tis	
family practitioner	FAM -ih-le prak- TIH -shun-er	
gastroenterologist	gas-tro-en-ter- OL -o-jist	
gastroscopy	gas- TROS -ko-pe	
geriatric	jer-e- AH -trik	
geriatrician	jer-e-ah- TRISH -un	
gynecologist	gi-neh- KOL -o-jist	
gynecology	gi-neh- KOL -o-je	
hematologist	he-mah- TOL -o-jist	
hematoma	he-mah- TO -mah	
hospitalist	HOS -pih-tah-list	
iatrogenic	i-ah-tro- JEN -ik	
infectious disease	in- FEK -shus dih- ZEZ	
internal medicine	in- TER -nal MED -ih-sin	
laryngitis	lah-rin- JI -tis	
lymphadenopathy	limf-ah-deh- NOP -ah-the	
nephrologist	neh- FROL -o-jist	
nephrostomy	neh- FROS -to-me	
neuralgia	nu- RAL -jah	
neurologist	nu- ROL -o-jist	
neurosurgeon	nu-ro- SUR -jun	
nosocomial	nos-o- KO -me-al	
obstetrician	ob-steh- TRISH -an	
obstetrics	ob- STET -riks	
oncogenic	ong-ko- JEN -ik	
oncologist	ong- KOL -o-jist	
ophthalmologist	of-thal- MOL -o-jist	
ophthalmology	of-thal- MOL -o-je	
optician	op- TISH -an	
optometrist	op- TOM -eh-trist	
orthopedist	or-tho- PE -dist	
otitis	o- TI -tis	
otolaryngologist	o-to-lah-rin- GOL -o-jist	
pathologist	pah- THOL -o-jist	
pathology	pah- THOL -o-je	
pediatric	pe-de- AT -rik	
pediatrician	pe-de-ah- TRISH -un	
physiatrist	fih- ZI -ah-trist	
psychiatrist	si- KI -ah-trist	
psychosis	si- KO -sis	
pulmonary specialist	PUL -mo-nair-e SPESH -ah-list	
radiation oncologist	ra-de- A -shun ong- KOL -o-jist	
radiologist	ra-de- OL -o-jist	
radiotherapy	ra-de-o- THER -ah-pe	
rectocele	REK -to-sel	
research	RE -surch	
rheumatologist	roo-mah- TOL -o-jist	
rheumatology	roo-mah- TOL -o-je	
rhinorrhea	ri-no- RE -ah	
surgery	SUR -jer-e	

thoracic surgeon	tho-RAS-ik SUR-jun _____
thoracotomy	tho-rah-KOT-o-me _____
urologist	u-ROL-o-jist _____
vasculitis	vas-ku-LI-tis _____

■ Practical Applications

Allied Health Specialists

This section provides three groups of exercises on allied health specialists and their job descriptions. Answers are on [page 210](#). [Appendix 5, Health Professions Resource](#) beginning on [page 339](#) lists health professions with education requirements, national association information, and certificate and licensing requirements.

A Match each allied health specialist to the appropriate job description. Write your answer on the blank line.

- audiologist
 - blood bank technologist
 - chiropractor
 - clinical laboratory technician
 - dental assistant
 - dental hygienist
 - diagnostic medical sonographer
 - dietitian/nutritionist
 - nurse anesthetist
 - nurse practitioner
1. Treats health problems associated with the muscular, nervous, and skeletal systems, especially the spine _____
 2. Examines, diagnoses, and treats patients under the direct supervision of a physician _____
 3. Works with people who have hearing problems by using testing devices to measure hearing loss _____
 4. Provides preventive dental care and teaches the practice of good oral hygiene _____
 5. Collects, types, and prepares blood and its components for transfusions _____
 6. Aids in the delivery of anesthesia during surgery _____
 7. Assists a dentist with dental procedures _____
 8. Performs diagnostic ultrasound procedures _____
 9. Plans nutrition programs and supervises the preparation and serving of meals _____
 10. Performs tests to examine and analyze body fluids, tissues, and cells _____

B Select from the list of specialists to match the job description.

- ECG technician
 - emergency medical technician/paramedic
 - health information management professional
 - home health aide
 - licensed practical nurse
 - medical assistant
 - medical laboratory technician
 - nuclear medicine technologist
 - nursing aide
 - occupational therapist
1. Cares for elderly, disabled, and ill persons in their own homes, helping them live there instead of in an institution _____
 2. Performs routine tests and laboratory procedures _____
 3. Designs, manages, and administers the use of health care data and information _____
 4. Operates an electrocardiograph to record ECGs and for Holter monitoring and stress tests _____
 5. Performs radioactive tests and procedures under the supervision of a nuclear medicine physician, who interprets the results _____
 6. Gives immediate care to acutely ill or injured persons and transports them to medical facilities _____
 7. Helps physicians examine and treat patients and performs tasks to keep offices running smoothly _____
 8. Cares for the sick, injured, convalescing, and handicapped, under the direct supervision of physicians and registered nurses; provides basic bedside care _____
 9. Helps individuals with mentally, physically, developmentally, or emotionally disabling conditions to develop, recover, or maintain daily living and working skills _____
 10. Helps care for physically or mentally ill, injured, or disabled patients confined to nursing, hospital, or residential care facilities; also known as nursing assistants or hospital attendants _____

C Match the specialist to the appropriate job description.

- ophthalmic medical technician
- phlebotomist
- physical therapist
- physician assistant
- radiation therapist
- radiographer/radiologic technologist
- registered nurse
- respiratory therapist
- speech-language pathologist
- surgical technologist

1. Evaluates, treats, and cares for patients with breathing disorders

2. Draws and tests blood under the supervision of a medical technologist or laboratory manager _____
3. Cares for sick and injured people by assessing and recording symptoms, assisting physicians during treatments and examinations, and administering medications

4. Prepares cancer patients for treatment and administers prescribed doses of ionizing radiation to specific areas of the body _____
5. Helps ophthalmologists provide medical eye care _____
6. Examines, diagnoses, and treats patients under the direct supervision of a physician

7. Assists in operations under the supervision of surgeons or registered nurses

8. Improves mobility, relieves pain, and prevents or limits permanent physical disabilities in patients with injuries or disease _____
9. Produces x-ray images of parts of the body for use in diagnosing medical problems

10. Assesses and treats persons with speech, language, voice, and fluency disorders

Answers to Practical Applications

A

1. chiropractor
2. nurse practitioner
3. audiologist
4. dental hygienist
5. blood bank technologist
6. nurse anesthetist
7. dental assistant
8. diagnostic medical sonographer
9. dietitian/nutritionist
10. clinical laboratory technician

B

1. home health aide
2. medical laboratory technician
3. health information management professional
4. ECG technician
5. nuclear medicine technologist
6. emergency medical technician/paramedic
7. medical assistant
8. licensed practical nurse
9. occupational therapist
10. nursing aide

C

1. respiratory therapist
2. phlebotomist
3. registered nurse
4. radiation therapist
5. ophthalmic medical technician
6. physician assistant
7. surgical technologist
8. physical therapist
9. radiographer/radiologic technologist

10. speech-language pathologist

Review

Test your understanding of the combining forms and suffixes used in this chapter by completing this review. Remember to check your responses with the Answers to Review on [page 212](#).

Combining Forms

Combining Form	Meaning
1. aden/o	_____
2. cardi/o	_____
3. col/o	_____
4. dermat/o	_____
5. endocrin/o	_____
6. enter/o	_____
7. esthesi/o	_____
8. gastr/o	_____
9. ger/o	_____
10. gynec/o	_____
11. hemat/o	_____
12. iatr/o	_____
13. laryng/o	_____
14. lymph/o	_____
15. nephr/o	_____
16. neur/o	_____
17. nos/o	_____
18. obstetr/o	_____
19. onc/o	_____
20. ophthalm/o	_____
21. opt/o, optic/o	_____
22. orth/o	_____
23. ot/o	_____
24. path/o	_____
25. ped/o	_____
26. physi/o	_____
27. psych/o	_____
28. pulmon/o	_____
29. radi/o	_____
30. rect/o	_____
31. rheumat/o	_____
32. rhin/o	_____
33. thorac/o	_____
34. ur/o	_____
35. vascul/o	_____

Suffixes

Suffix	Meaning
1. -algia	_____
2. -ary	_____
3. -cele	_____
4. -eal	_____
5. -genic	_____
6. -ist	_____
7. -itis	_____
8. -logy	_____
9. -megaly	_____
10. -oma	_____
11. -osis	_____
12. -pathy	_____
13. -rrhea	_____
14. -scopy	_____
15. -stomy	_____
16. -therapy	_____
17. -tomy	_____

Answers to Review

Combining Forms

1. gland
2. heart
3. colon
4. skin
5. endocrine glands
6. intestines
7. sensation
8. stomach
9. old age
10. woman
11. blood
12. treatment
13. voice box
14. lymph
15. kidney
16. nerve
17. disease
18. midwife
19. tumor
20. eye
21. eye
22. straight
23. ear
24. disease
25. child
26. function
27. mind
28. lung
29. x-rays

30. rectum
31. flow, fluid
32. nose
33. chest
34. urinary tract
35. blood vessels

Suffixes

1. pain
2. pertaining to
3. hernia, protrusion
4. pertaining to
5. pertaining to producing
6. specialist
7. inflammation
8. study of
9. enlargement
10. mass, tumor
11. abnormal condition
12. disease, emotion
13. flow
14. process of visual examination
15. opening
16. treatment
17. incision

Terminology Checkup

Give the difference between the following pairs of medical specialists. Write the answers on the lines provided. Confirm your answers and check the box next to each item when you know you've "got" it!

- 1. **orthopedist** _____
rheumatologist _____
- 2. **nephrologist** _____
urologist _____
- 3. **cardiologist** _____
cardiovascular surgeon _____
- 4. **pulmonologist** _____
otolaryngologist _____
thoracic surgeon _____
- 5. **neurologist** _____
neurosurgeon _____
- 6. **pathologist** _____
oncologist _____
hematologist _____
- 7. **radiologist** _____
radiation oncologist _____
- 8. **gynecologist** _____
obstetrician _____
- 9. **physiatrist** _____
psychiatrist _____

Answers to Terminology Checkup

1. An **orthopedist** is a surgeon who diagnoses and treats bone, muscle, and joint conditions, whereas a **rheumatologist** is an internal medicine specialist who primarily diagnoses and treats disorders of joints.
2. A **nephrologist** is an internal medicine specialist who diagnoses and treats disorders of the kidneys, whereas a **urologist** is a surgeon who operates on the kidneys, urinary tract, and male reproductive organs.
3. A **cardiologist** is an internal medicine specialist who diagnoses and treats disorders of the heart, whereas a **cardiovascular surgeon** operates on the heart and blood vessels.
4. A **pulmonologist** is an internal medicine specialist who diagnoses and treats diseases of the lungs, whereas an **otolaryngologist** is a surgeon who operates on the ear, nose, throat, head, and neck. A **thoracic surgeon**, however, operates on organs in the chest, such as the heart, lungs, and esophagus.
5. A **neurologist** is an internal medicine specialist who diagnoses and treats disorders of the brain, spinal cord, and nerves, whereas a **neurosurgeon** operates on the brain, nerves, and spinal cord.
6. A **pathologist** is an internal medicine specialist who examines dead bodies (performs autopsies) and specimens of living cells (biopsies) to determine the correct diagnosis. An **oncologist**, also a specialist in internal medicine, diagnoses and treats malignant tumors. A **hematologist** is a specialist in internal medicine who diagnoses and treats disorders of the blood.
7. A **radiologist** is primarily a diagnostic physician who examines images from x-ray, CT, ultrasound, and MRI studies, whereas a **radiation oncologist** treats malignancies with high-energy radiation (photons and protons).

8. A **gynecologist** is a surgical specialist who treats diseases of the female reproductive system. An **obstetrician** specializes in the treatment of pregnant women and delivery of infants.

9. A **physiatrist** restores function after injury or illness and is also known as a physical medicine and rehabilitation specialist. A **psychiatrist** treats mental disorders.

APPENDIX 1

Body Systems

This appendix contains full-color diagrams of body systems. For each system, the material presented is divided into seven sections. **Anatomy** shows major organs and structures with labels and combining forms (in parentheses) for each body part. The parts of the body are defined and explained in the *Mini-Dictionary* (beginning on [page 349](#)). **Terminology** reviews combining forms and their meanings and gives examples of medical terminology using each combining form. **Pathology** explains terms related to common pathological conditions. **Laboratory Tests and Diagnostic Procedures** presents common tests and procedures, which can be cross-referenced for additional information in [Appendix 2, Diagnostic Tests and Procedures](#). **Treatment Procedures** explains therapies that treat abnormal conditions in each system. **Abbreviations** lists selected abbreviations for easy reference. **Matching Exercises** review the terminology to reinforce your understanding; answers to all exercises are provided, beginning on [page 291](#).

Use this appendix both as a study guide for classroom work and as a reference for your work in the medical field.

Cardiovascular System [216](#)

Digestive System [224](#)

Endocrine System [232](#)

Female Reproductive System [238](#)

Lymphatic System [244](#)

Male Reproductive System [248](#)

Musculoskeletal System [253](#)

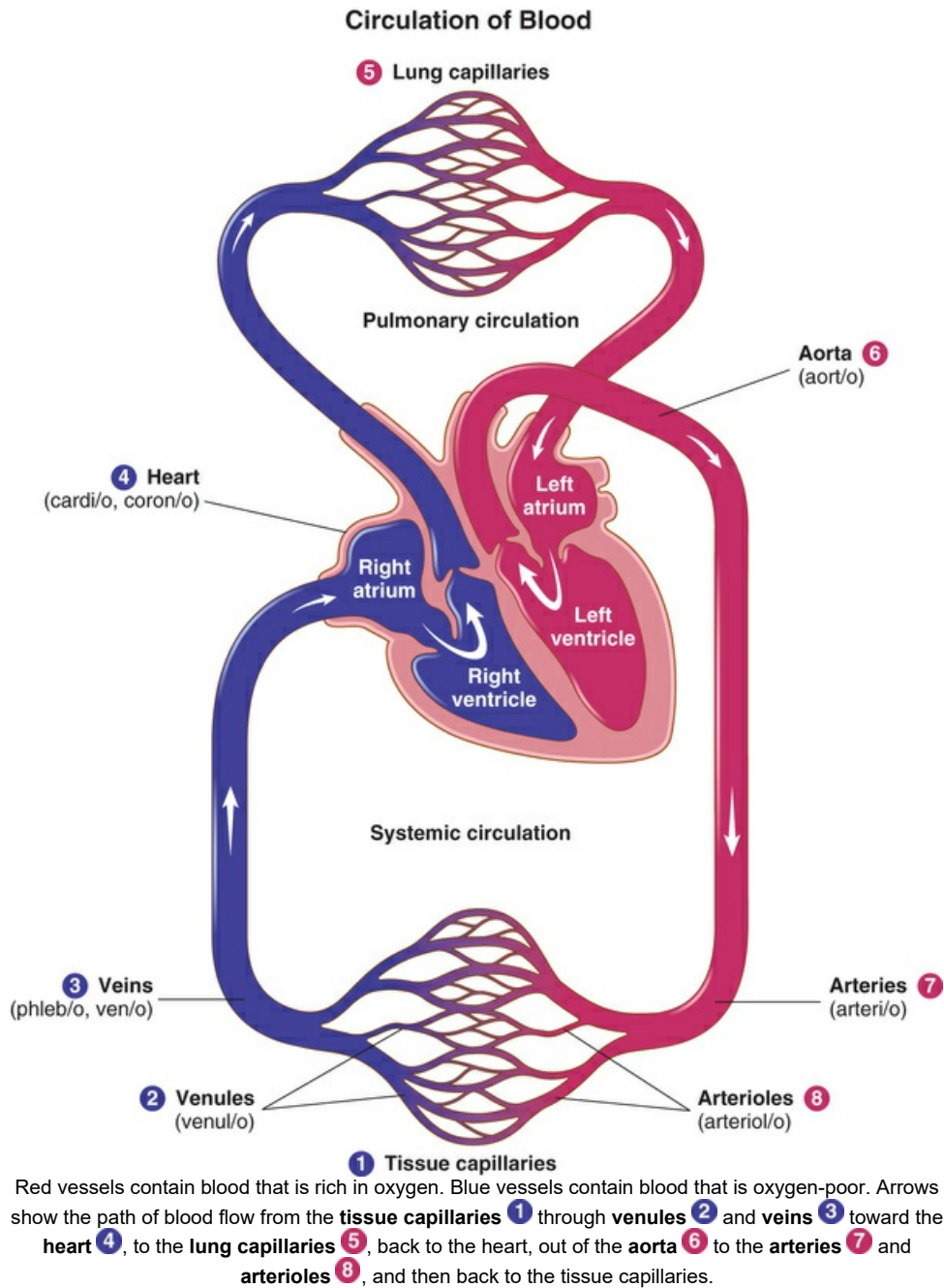
Nervous System [263](#)

Respiratory System [269](#)

Skin and Sense Organs [277](#)

Urinary System [285](#)

Cardiovascular System Anatomy



Terminology

Meanings for terminology are found in the *Mini-Dictionary*, beginning on [page 349](#).

Combining Form	Meaning	Terminology	Meaning
angi/o	vessel	<u>angioplasty</u>	
aort/o	aorta	<u>aortic stenosis</u>	
arteri/o	artery	<u>arteriosclerosis</u>	
arteriol/o	arteriole	<u>arteriolitis</u>	

cardi/o	heart	cardiomyopathy _____ pericardium _____
coron/o	heart	coronary arteries _____
phleb/o	vein	phlebotomy _____
ven/o	vein	intravenous _____
venul/o	venule	venulitis _____

Pathology

Definitions for additional terms in **boldface** are found in the *Mini-Dictionary*.

Aneurysm: Local widening of an artery caused by weakness in the arterial wall or breakdown of the wall from **atherosclerosis**.

Angina: Chest pain caused by decreased blood flow to heart muscle. Also called angina pectoris (PECT/O means chest).

Arrhythmia: Abnormal heartbeat (rhythm); **fibrillation** and **flutter** are examples.

Atherosclerosis: Hardening of arteries with a collection of cholesterol-like plaque.

Congestive heart failure: Inability of the heart to pump its required amount of blood. Blood accumulates in the lungs, causing **pulmonary edema**.

Hypertension: High blood pressure. Essential hypertension is high blood pressure with no apparent cause. In secondary hypertension, another illness (kidney disease or an adrenal gland disorder) is the cause of the high blood pressure.

Myocardial infarction: Heart attack. An **infarct** is an area of dead (**necrotic**) tissue.

Shock: A group of signs and symptoms (paleness of skin, weak and rapid pulse, shallow breathing) indicating poor oxygen supply to tissues and insufficient return of blood to the heart.

Laboratory Tests and Diagnostic Procedures

Consult [Appendix 2](#), beginning on [page 295](#), for pronunciation of terms and additional information.

Angiography: Recording (via x-ray images) blood vessels after the injection of contrast into the bloodstream.

Cardiac catheterization: Introducing a catheter (flexible, tubular instrument) into a coronary blood vessels to measure pressure and flow patterns of blood.

Cardiac enzyme tests: Measurements of enzymes released into the bloodstream after a heart attack (myocardial infarction).

Doppler ultrasound: Measuring blood flow in vessels via sound waves.

Echocardiography: Images of the heart are produced using sound waves.

Electrocardiography: Recording electricity flowing through the heart.

Holter monitoring: Detection of abnormal heart rhythms (**arrhythmias**) that involves having a patient wear a compact version of an electrocardiograph for 24 hours.

Lipid tests: Measurements of cholesterol and triglyceride levels in the blood.

Lipoprotein tests: Measurements of **high-density lipoprotein (HDL)** and **low-density lipoprotein (LDL)** in the blood.

Magnetic resonance imaging (MRI): Producing an image, by beaming magnetic waves at the heart,

that gives detailed information about congenital heart disease, cardiac masses, and disease within large blood vessels.

MUGA scan: Imaging the motion of heart wall muscles and assessing the function of the heart via a multiple-gated acquisition scan, which uses radioactive chemicals.

Positron emission tomography (PET) scan: Radioactive chemicals, which release radioactive particles, are injected into the bloodstream and travel to the heart. Cross-sectional images show the flow of blood and the functional activity of the heart muscle.

Stress test: An electrocardiogram plus blood pressure and heart rate measurements shows the heart's response to physical exertion (treadmill test).

Technetium Tc 99m sestamibi scan: A radioactive pharmaceutical (sestamibi “tagged” with technetium-99m) is injected intravenously to show perfusion (flow) of blood in heart muscle. It is taken up in the area of a myocardial infarction, producing “hot spots.” In an ETT-MIBI exercise tolerance test, an intravenous radioactive substance is given before the patient reaches maximal heart rate on a treadmill.

Thallium-201 scan: A radioactive test that shows where injected thallium-201 (a radioactive substance) localizes in heart muscle.

Treatment Procedures

Cardiac catheter ablation: Flexible tube is threaded through blood vessels into the heart to destroy (ablate) abnormal tissue that causes arrhythmias.

Cardioversion: Brief discharges of electricity passing across the chest to stop a cardiac **arrhythmia**. Also called **defibrillation**.

Coronary artery bypass grafting (CABG): Vessels taken from the patient's legs or chest are connected to coronary arteries to make detours around blockages.

Endarterectomy: Surgical removal of the innermost lining of an artery to remove fatty deposits and clots.

Heart transplantation: A donor heart is transferred to a recipient.

Percutaneous coronary intervention (PCI): A balloon-tipped catheter (a flexible, tubular instrument) is threaded into a coronary artery to compress fatty deposits and open the artery. **Stents** (expandable slotted tubes) create wider openings that make the recurrence of blockages less likely. Also called **balloon angioplasty**.

Thrombolytic therapy: Drugs such as tPA (tissue plasminogen activator) and streptokinase are injected into a patient's bloodstream to dissolve clots that may cause a heart attack.

Abbreviations

See [Appendix 3](#), beginning on [page 317](#), for a more complete list of medical abbreviations.

ACS	Acute coronary syndrome (disease changes in coronary arteries leading to plaque/clot formation and heart attack or other heart problems)
AED	Automated external defibrillator (electronic device that can diagnose and treat serious arrhythmias)
AMI	Acute myocardial infarction (heart attack)
BP	Blood pressure
CABG	Coronary artery bypass grafting (surgical placement of vessels, either vein or artery, to detour blocked coronary arteries)
CAD	Coronary artery disease
CCU	Coronary care unit
CHF	Congestive heart failure (heart is unable to pump its required amount of blood)
CPR	Cardiopulmonary resuscitation
ECG	Electrocardiography
ECHO or	Echocardiography

Echo	
HDL	High-density lipoprotein
HTN	Hypertension (high blood pressure)
ICD	Implantable cardioverter-defibrillator
LDL	Low-density lipoprotein (combination of fat and protein; high cholesterol content and associated with formation of plaque in arteries)
PCI	Percutaneous coronary intervention (placement of a catheter and stent in a coronary artery to open the artery; balloon angioplasty)

Matching Exercises

The following exercises will help you review terminology related to the cardiovascular system. Answers begin on [page 291](#).

A Match the term in Column I with its meaning in Column II. These terms are illustrated in the diagram on [page 216](#) and are defined in the *Mini-Dictionary*, beginning on [page 349](#).

Column I	Column II
1. aorta	A. Blood vessels that carry blood to the heart from the body tissues
2. lung capillaries	B. Largest artery in the body
3. arteries	C. Tiny blood vessels that lie near cells and through whose walls gases, food, and wastes can pass
4. arterioles	D. Small veins
5. venules	E. Small arteries
6. veins	F. Blood vessels that carry blood away from the heart
7. pulmonary circulation	G. Passage of blood from the heart to the body tissues and back
8. systemic circulation	H. Hollow muscular organ that pumps blood all over the body
9. tissue capillaries	I. Tiny blood vessels surrounding lung tissue through which gases pass into and out of the blood
10. heart	J. Passage of blood from the heart to the lungs and back to the heart

B Match the combining form in Column I with its meaning in Column II.

Column I	Column II
1. phleb/o	A. Artery
2. arteriol/o	B. Vessel
3. angi/o	C. Heart
4. venul/o	D. Vein
5. arteri/o	E. Small artery
6. coron/o	F. Small vein

C Match the medical term in Column I with its meaning in Column II.

Column I	Column II
1. intravenous	A. Inflammation of small veins
2. arteriosclerosis	B. Narrowing of the largest artery
3. phlebotomy	C. Disease of heart muscle
4. cardiomyopathy	D. Pertaining to within a vein
5. angioplasty	E. Inflammation of small arteries
6. arteriolitis	F. Hardening of arteries
7. venulitis	G. Incision of a vein
8. aortic stenosis	H. Surgical repair of blood vessels
9. pericardium	I. Pertaining to the heart
10. coronary	J. Membrane surrounding the heart

D Match the pathologic condition in Column I with its meaning in Column II.

Column I	Column II
1. hypertension	A. Abnormal heartbeat
2. atherosclerosis	B. Local widening of an artery
3. angina	C. Heart attack
4. shock	D. Chest pain
5. myocardial infarction	E. High blood pressure
6. arrhythmia	F. Inability of the heart to pump its required amount of blood
7. congestive heart failure	G. Group of signs and symptoms: pale skin, weak rapid pulse, and shallow respirations
8. aneurysm	H. Hardening of arteries with cholesterol-like plaque

E Match the test or procedure in Column I with its description in Column II.

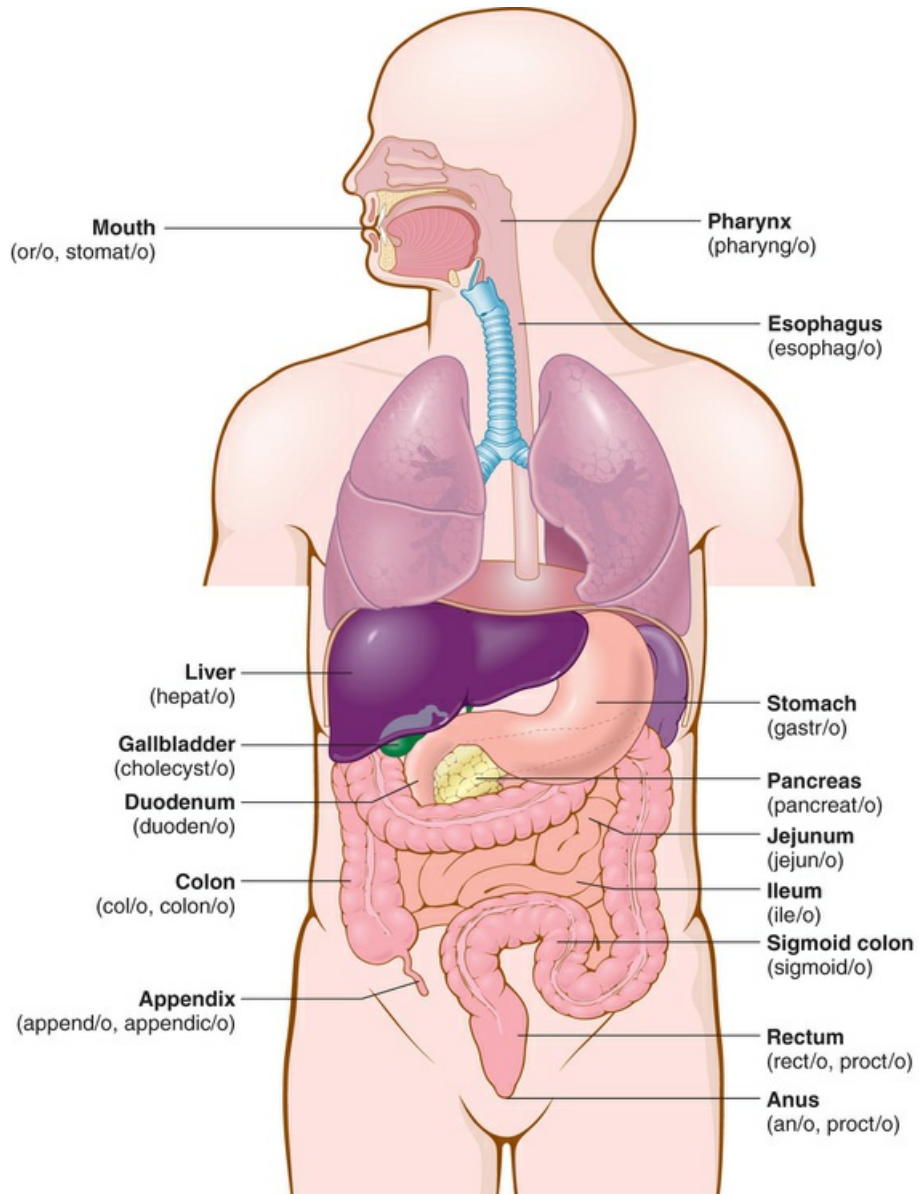
Column I	Column II
1. lipid tests	A. Sound waves produce images of the heart

2. MUGA scan	_____	B. X-ray images of blood vessels after contrast is injected into the bloodstream
3. lipoprotein tests	_____	C. Measurement of HDL and LDL in blood
4. Holter monitoring	_____	D. Recording electricity through the heart
5. angiography	_____	E. Measurement of substances in the blood that indicate a heart attack
6. cardiac enzyme test	_____	F. Sound waves measure blood flow in vessels
7. electrocardiography	_____	G. Abnormal heart rhythms are detected with a compact ECG over a 24-hour period
8. echocardiography	_____	H. Radioactive test to detect blood perfusion in heart muscle
9. sestamibi scan	_____	I. Measurement of triglyceride and cholesterol levels in the blood
10. Doppler ultrasound	_____	J. Radioactive chemicals and a scanner produce images of the motion of the heart wall

F Match the treatment procedure in Column I with its description in Column II.

Column I		Column II
1. cardioversion	_____	A. Surgery to detour around blockages in coronary arteries
2. thrombolytic therapy	_____	B. Drugs such as tPA dissolve clots that may cause a heart attack
3. heart transplantation	_____	C. Balloon-tipped catheter with stent opens coronary arteries
4. endarterectomy	_____	D. Flexible tube is threaded into the heart; abnormal tissue is destroyed
5. CABG	_____	E. Brief discharges of electricity stop a cardiac arrhythmia
6. PCI	_____	F. Removal of innermost lining of an artery to eliminate fatty deposits
7. cardiac catheter ablation	_____	G. Donor heart is transferred to a recipient

Digestive System Anatomy



Food enters the body via the mouth and travels through the **pharynx**, **esophagus**, and **stomach** to the small intestine (**duodenum**). The **liver**, **gallbladder**, and **pancreas** make and store chemicals that aid in the digestion of foods. Digested (broken-down) food is absorbed into the bloodstream through the walls of the small intestine (**jejunum** and **ileum**). Any substance that cannot be absorbed continues into the **colon** (large intestine) and leaves the body through the **rectum** and **anus**. (Modified from Chabner D-E: *The Language of Medicine*, ed 11, St. Louis, 2017, Elsevier.)

Terminology

Meanings for terminology are found in the *Mini-Dictionary*.

Combining Form	Meaning	Terminology	Meaning
an/o	anus	anal _____	
append/o	appendix	appendectomy _____	
appendic/o	appendix	appendicitis _____	
cholecyst/o	gallbladder	cholecystectomy _____	

col/o	colon	colostomy _____
colon/o	colon	colonoscopy _____
duoden/o	duodenum	duodenal _____
esophag/o	esophagus	esophageal _____
gastr/o	stomach	gastralgia _____
hepat/o	liver	hepatomegaly _____
ile/o	ileum	ileostomy _____
jejun/o	jejunum	gastrojejunostomy _____
or/o	mouth	oral _____
pancreat/o	pancreas	pancreatitis _____
pharyng/o	pharynx	pharyngeal _____
proct/o	anus and rectum	proctoscopy _____
rect/o	rectum	rectocele _____
sigmoid/o	sigmoid colon	sigmoidoscopy _____
stomat/o	mouth	stomatitis _____

Pathology

Definitions for additional terms in **boldface** are found in the *Mini-Dictionary*.

Cholelithiasis: Abnormal condition of gallstones.

Cirrhosis: Chronic disease of the liver with degeneration of liver cells.

Colonic polyposis: Condition in which **polyps** protrude from the mucous membrane lining the colon.

Diverticulosis: Abnormal condition of small pouches or sacs (**diverticula**) in the wall of the intestine (often the colon). **Diverticulitis** is inflammation and infection within diverticula.

Gastroesophageal reflux disease (GERD): A condition in which contents of the stomach flow back into the esophagus.

Hepatitis: Inflammation of the liver.

Inflammatory bowel disease (IBD): Inflammation of the terminal (last) portion of the ileum (**Crohn disease**) or inflammation of the colon (**ulcerative colitis**).

Irritable bowel syndrome (IBS): Signs and symptoms are cramping, abdominal bloating, constipation, and diarrhea. Although IBS causes distressing symptoms, it does not permanently harm the intestine. Its cause is unknown.

Hepatocellular carcinoma: Cancer (primary) of the liver.

Jaundice: Yellow-orange coloration of the skin and other tissues, from high levels of **bilirubin** in the bloodstream (**hyperbilirubinemia**).

Laboratory Tests and Diagnostic Procedures

Consult [Appendix 2](#) for pronunciation of terms and additional information.

Abdominal computed tomography (CT) scan: A series of cross-sectional x-ray images that show abdominal organs.

Abdominal magnetic resonance imaging (MRI): Magnetic and radio waves create images of abdominal organs and tissues in all three planes of the body.

Abdominal ultrasonography: Process of beaming sound waves into the abdomen to produce images of organs, such as the gallbladder. **Endoscopic ultrasonography** is useful to detect enlarged lymph nodes and tumors in the upper abdomen.

Barium tests: X-ray examinations using a liquid barium mixture to locate disorders of the

gastrointestinal tract. In a **barium enema (lower GI series)**, barium is injected into the anus and rectum, and x-ray images are taken of the colon. In an **upper GI series (barium swallow)**, barium is taken in through the mouth, and x-ray images reveal the esophagus, stomach, and small intestine.

Cholangiography: X-ray examination of the bile ducts (CHOLANGI/O-) after the injection of contrast material through the liver (**percutaneous transhepatic cholangiography**) or through a catheter (a flexible, tubular instrument) from the mouth, esophagus, and stomach into the bile ducts (**endoscopic retrograde cholangiopancreatography**, or **ERCP**).

Gastrointestinal endoscopy: Visual examination of the gastrointestinal tract with an endoscope. Examples are **esophagoscopy**, **gastrosocopy**, **colonoscopy**, and **sigmoidoscopy**.

Hemocult test: Feces are placed on paper containing the chemical guaiac, which reacts with hidden (occult) blood. This is an important screening test for colon cancer.

Laparoscopy: Visual examination of the abdominal cavity through an endoscope inserted in the abdomen.

Liver function tests (LFTs): Measurements of liver enzymes and other substances in the blood. Enzyme levels increase when the liver is damaged (as in hepatitis). Examples of liver enzymes are **ALT**, **AST**, and **alkaline phosphatase (alk phos)**. High **bilirubin** (blood pigment) levels indicate **jaundice** caused by liver disease or other problems affecting the liver.

Stool culture: Feces (stools) are placed in a growth medium (culture) to test for microorganisms (such as bacteria).

Virtual colonoscopy: CT scans, MRI, and computers are used to produce two- and three-dimensional images of the colon. Also called **CT colonography**.

Treatment Procedures

Anastomosis: Surgical creation of an opening between two gastrointestinal organs. Examples are gastrojejunostomy, cholecystojejunostomy, and choledochoduodenostomy (**CHOLEDOCH/O** means common bile duct).

Colostomy: Surgical creation of a new opening of the colon to the outside of the body.

Ileostomy: Surgical creation of a new opening of the ileum to the outside of the body.

Laparoscopic surgery: Removal of organs or tissues via a laparoscope (instrument inserted into the abdomen through a small incision). Examples are **laparoscopic cholecystectomy** and **laparoscopic appendectomy**, which are types of **minimally invasive surgery or keyhole surgery**.

Abbreviations

ALT, AST	Alanine transaminase and aspartate transaminase (liver enzymes measured as part of LFTs)
BE	Barium enema (barium, a contrast agent, is introduced through the rectum, and x-ray pictures of the colon are taken)
ERCP	Endoscopic retrograde cholangiopancreatography
GB	Gallbladder
GERD	Gastroesophageal reflux disease
GI	Gastrointestinal
IBD	Inflammatory bowel disease (Crohn disease and ulcerative colitis)
IBS	Irritable bowel syndrome
LFTs	Liver function tests (ALT, AST, bilirubin)
NPO	Nothing by mouth (Latin, <i>nil per os</i>)
TPN	Total parenteral nutrition (intravenous solutions are given to maintain nutrition)

Matching Exercises

The following exercises will help you review terminology related to the digestive system. Answers begin on [page 291](#).

A Match the term in Column I with its description in Column II.

Column I	Column II
1. mouth	A. Organ that receives food from the esophagus and sends it to the intestine
2. pharynx	B. Third part of the small intestine
3. esophagus	C. Throat
4. stomach	D. Second part of the small intestine
5. duodenum	E. Large intestine
6. jejunum	F. First part of the small intestine
7. ileum	G. Opening that is the beginning of the digestive system
8. colon	H. Tube that carries food to the stomach

B Match the term in Column I with its description in Column II.

Column I	Column II
1. sigmoid colon	A. Opening of the colon to the outside of the body
2. rectum	B. Sac that stores bile
3. anus	C. S-shaped lower portion of the large intestine
4. appendix	D. Organ that makes bile, stores sugar, and produces proteins to clot blood
5. liver	E. Gland that makes both digestive juices and insulin (hormone)
6. gallbladder	F. Small sac that hangs from the beginning of the large intestine
7. common bile duct	G. Tube that carries bile from the liver and gallbladder to the intestine
8. pancreas	H. Final section of the colon

C Match the combining form in Column I with its meaning in Column II.

Column I	Column II
1. gastr/o	A. Mouth
2. col/o	B. Endocrine and exocrine gland near the stomach
3. proct/o	C. Third part of the small intestine
4. cholecyst/o	D. Stomach
5. pharyng/o	E. Liver
6. or/o	F. First part of the small intestine
7. hepat/o	G. Large intestine
8. duoden/o	H. Anus and rectum
9. ile/o	I. Gallbladder
10. pancreat/o	J. Throat

D Match the term in Column I with its meaning in Column II.

Column I	Column II
1. hepatomegaly	A. Pertaining to the tube leading from the throat to the stomach
2. cholecystectomy	B. Pain of the stomach
3. proctoscopy	C. Enlargement of the liver
4. ileostomy	D. Inflammation of the mouth
5. stomatitis	E. Pertaining to the first part of the small intestine
6. gastrojejunostomy	F. Removal of the gallbladder
7. pancreatitis	G. Visual examination of the anus and rectum
8. duodenal	H. New opening of the third part of the small intestine to the outside of the body
9. esophageal	I. New opening between the stomach and second part of the small intestine
10. gastralgia	J. Inflammation of a gland adjacent to the stomach

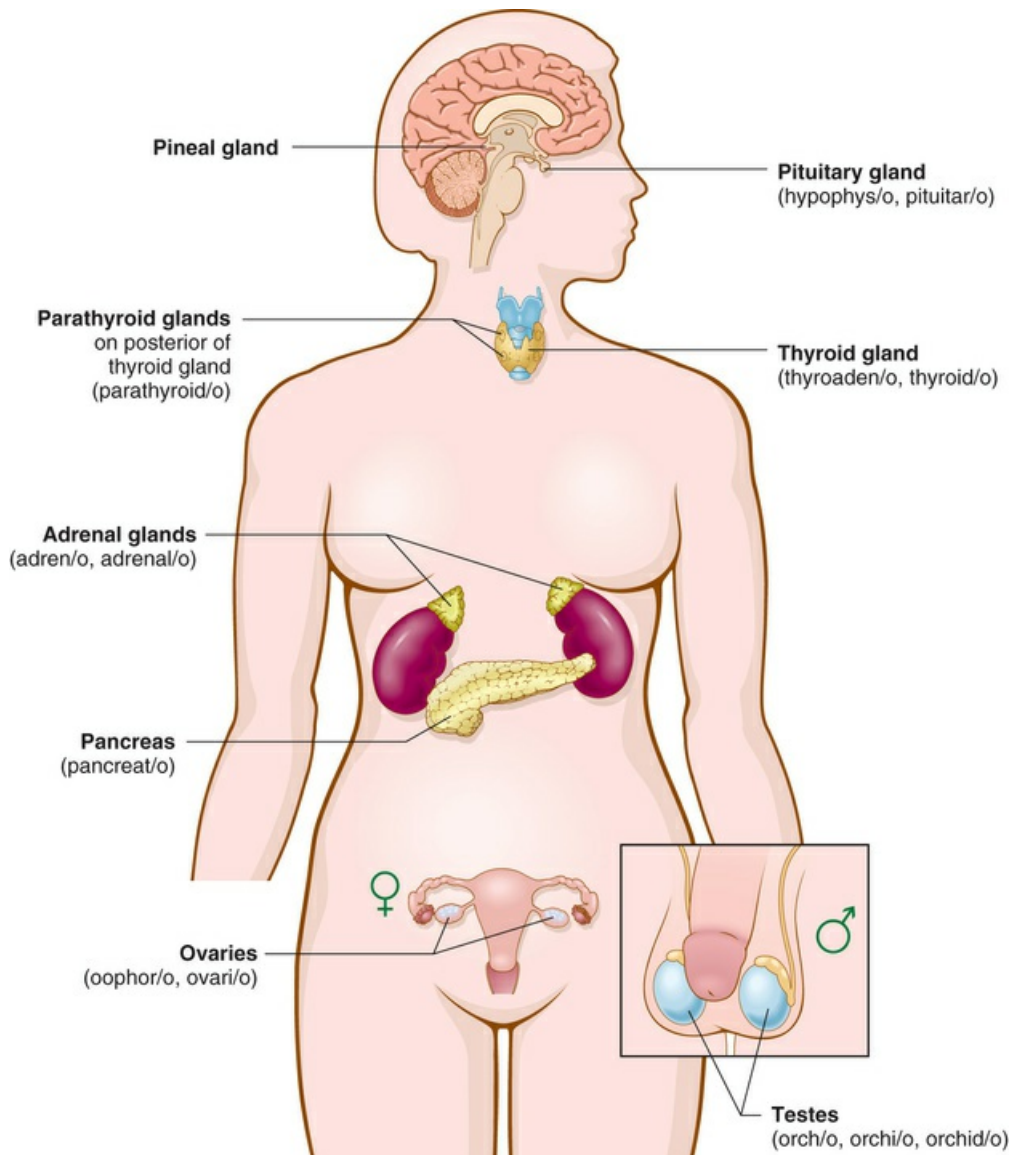
E Match the pathologic condition in Column I with its meaning in Column II.

Column I	Column II
1. hepatitis	A. Yellow-orange coloration of the skin and other tissues
2. cirrhosis	B. Abnormal condition of small pouches or sacs in the wall of the intestine
3. cholelithiasis	C. Ulcerative colitis and Crohn disease
4. colonic polyposis	D. Inflammation of the liver
5. jaundice	E. Abnormal condition of gallstones
6. inflammatory bowel disease	F. Chronic disease of the liver with degeneration of liver cells
7. diverticulosis	G. Small growths protrude from the mucous membrane lining the intestine
8. irritable bowel syndrome	H. Contents of the stomach flow backwards into the esophagus
9. hepatocellular carcinoma	I. Signs and symptoms of GI distress, but no lesions found in the GI tract
10. gastroesophageal reflux disease	J. Primary cancer of the liver

F Match the test or procedure in Column I with its description in Column II.

Column I	Column II
1. LFTs	A. X-ray examination of bile ducts
2. abdominal CT	B. Minimally invasive surgery of the abdomen
3. cholangiography	C. Visual examination of the gastrointestinal tract (colonoscopy)
4. stool culture	D. Feces are placed in a growth medium and tested for microorganisms
5. GI endoscopy	E. Cholecystojejunostomy
6. hemoccult test	F. Magnetic waves create images of abdominal organs in three planes of the body
7. barium tests	G. Measurements of liver enzymes (ALT, AST, alk phos) and other substances
8. abdominal MRI	H. Feces are tested for blood; stool guaiac test
9. anastomosis	I. Series of cross-sectional x-ray images show abdominal organs
10. laparoscopic surgery	J. X-ray images of the GI tract obtained after introduction of a radiopaque liquid into the rectum or mouth

Endocrine System Anatomy



Endocrine glands secrete (form and give off) hormones into the bloodstream. The hormones travel throughout the body, affecting organs (including other endocrine glands) and controlling their actions.
(Modified from Chabner D-E: *The Language of Medicine*, ed 11, St. Louis, 2017, Elsevier.)

Terminology

Meanings for terminology are found in the *Mini-Dictionary*.

Combining Form	Meaning	Terminology
adren/o	adrenal gland	adrenopathy
adrenal/o	adrenal gland	adrenalectomy
hypophys/o	pituitary gland	hypophyseal
oophor/o	ovary	oophoritis
ovari/o	ovary	ovarian cyst
orch/o	testis	orchitis
orchi/o	testis; testicle	orchiopexy
orchid/o	testis; testicle	orchidectomy
pancreat/o	pancreas	pancreatectomy

parathyroid/o	parathyroid gland	hyperparathyroidism
pituitary/o	pituitary gland	hypopituitarism
thyroaden/o	thyroid gland	thyroadenitis
thyroid/o	thyroid gland	thyroidectomy

Pathology

Definitions for additional terms in **boldface** are found in the *Mini-Dictionary*.

Acromegaly: Enlargement of extremities caused by hypersecretion from the anterior portion of the pituitary gland after puberty.

Cushing syndrome: Group of clinical features produced by excess secretion of **cortisol** from the adrenal cortex. These signs and symptoms include obesity, moon-like facies (fullness of the face), **hyperglycemia**, and **osteoporosis**.

Diabetes mellitus: Disorder of the pancreas that causes an increase in blood glucose levels (hyperglycemia). **Type 1 diabetes**, with onset usually in childhood, involves complete deficiency of **insulin** in the body. **Type 2 diabetes**, with onset usually in adulthood, involves some insulin deficiency and resistance of tissues to the action of insulin.

Goiter: Enlargement of the thyroid gland.

Hyperthyroidism: Overactivity of the thyroid gland; also called **Graves disease** or **exophthalmic** (eyeballs bulge outward) **goiter**.

Laboratory Tests and Diagnostic Procedures

Consult [Appendix 2](#) for pronunciation of terms and additional information.

Computed tomography (CT scan): Cross-sectional x-ray images of the pituitary gland and other endocrine organs.

Exophthalmometry: Measurement of eyeball protrusion (**exophthalmos**) as an indicator of **Graves disease** (**hyperthyroidism**).

Fasting blood sugar (glucose) test: Measurement of glucose levels in a blood sample taken from a fasting patient and in specimens taken 30 minutes, 1 hour, 2 hours, and 3 hours after the ingestion of 75 g of glucose. Delayed return of blood glucose to normal levels indicates **diabetes mellitus**.

Magnetic resonance imaging (MRI): Magnetic waves produce images of the **hypothalamus**, pituitary gland, and other endocrine organs in all three planes of the body.

Radioactive iodine uptake: Measurement of how much of a radioactive element (iodine) is absorbed by the thyroid gland. The radioactive iodine is given by mouth and measured as evidence of thyroid function.

Serum and urine tests: Measurement of hormones, **electrolytes** (such as sodium and potassium), and glucose levels in blood (serum) and urine as indicators of endocrine function.

Thyroid function tests: Measurement of levels of T4 (thyroxine), T3 (triiodothyronine), and TSH (thyroid-stimulating hormone) in the bloodstream.

Thyroid scan: Procedure in which a radioactive compound, injected intravenously, localizes in the thyroid gland. A scanning device produces an image showing the presence of tumors or nodules in the gland.

Abbreviations

ACTH	Adrenocorticotropic hormone (from the pituitary gland)
------	--

DM	Diabetes mellitus
GH	Growth hormone (secreted by the pituitary gland)
GTT	Glucose tolerance test (measures the ability to respond to a glucose load; test for diabetes mellitus)
HbA1c	Hemoglobin A1c measures the average amount of glucose in red blood cells. Useful to follow control of glucose in diabetic patients.
K⁺	Potassium (an electrolyte)
Na⁺	Sodium (an electrolyte)
RAIU	Radioactive iodine uptake (test for thyroid function)
T3	Triiodothyronine (hormone from the thyroid gland)
T4	Thyroxine (hormone from the thyroid gland)
TSH	Thyroid-stimulating hormone (from the pituitary gland)

Matching Exercises

The following exercises will help you review terminology related to the endocrine system. Answers begin on [page 291](#).

A Match the term in Column I with its location in Column II.

Column I	Column II
1. thyroid gland	A. Two paired male glands located in the scrotal sac
2. ovaries	B. Organ at the base of the brain in the sella turcica (round depression at the base of the skull)
3. testes	C. Gland in the neck on either side of the trachea
4. parathyroid glands	D. Two glands, one above each kidney
5. pituitary gland	E. Gland adjacent to the stomach
6. pancreas	F. Four glands behind the thyroid gland
7. adrenal glands	G. Two paired organs in the female abdomen

B Match the combining form in Column I with the secretion or function in Column II.

Column I	Column II
1. hypophys/o	A. Regulates calcium in the blood and bones
2. orchid/o	B. Secretes epinephrine (adrenaline) and cortisol
3. oophor/o	C. Secretes insulin, which allows sugar to enter cells
4. thyroaden/o	D. Secretes testosterone
5. pancreat/o	E. Secretes growth hormone and hormones that control the thyroid gland, ovaries, and testes
6. adren/o	F. Secretes estrogen and progesterone
7. parathyroid/o	G. Secretes thyroxine (T4), which increases metabolism of body cells

C Match the medical term in Column I with its meaning in Column II.

Column I	Column II
1. thyroidenitis	A. Disease of the adrenal glands
2. oophoritis	B. Pertaining to the pituitary gland
3. orchiopexy	C. Inflammation of the thyroid gland
4. hyperparathyroidism	D. Removal of the thyroid gland
5. thyroidectomy	E. Surgical fixation of an undescended testicle
6. adrenopathy	F. Increased secretion of parathyroid hormone
7. hypophyseal	G. Inflammation of an ovary

D Match the pathologic condition in Column I with its description in Column II.

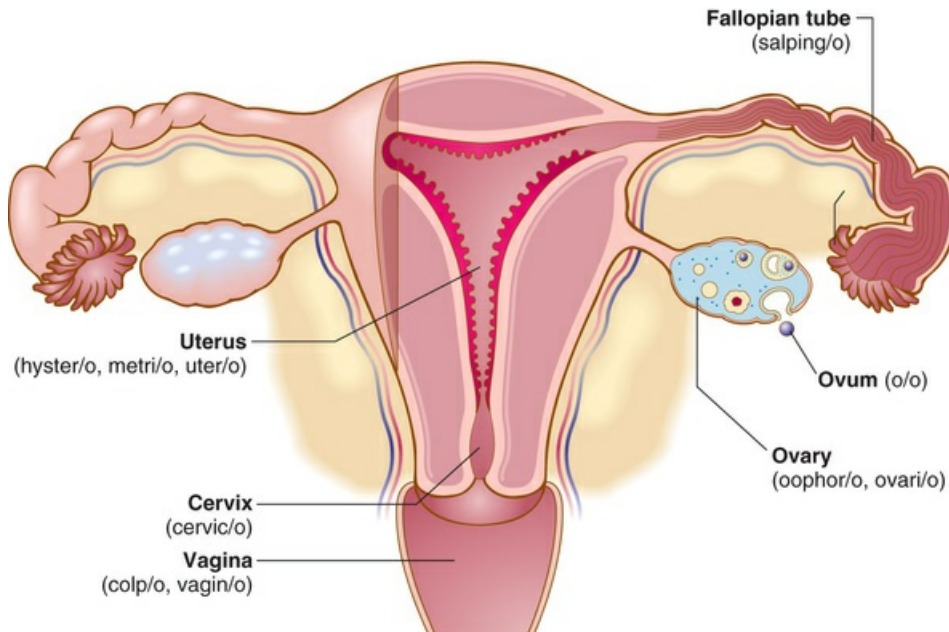
Column I	Column II
1. diabetes mellitus	A. Enlargement of the thyroid gland
2. acromegaly	B. Hypersecretion of cortisone from the adrenal glands
3. goiter	C. Deficiency of insulin leading to high blood sugar levels
4. Cushing syndrome	D. Enlargement of extremities caused by increased growth hormone from the pituitary gland
5. hyperthyroidism	E. Overactivity of the thyroid gland

E Match the test or procedure in Column I with its description in Column II.

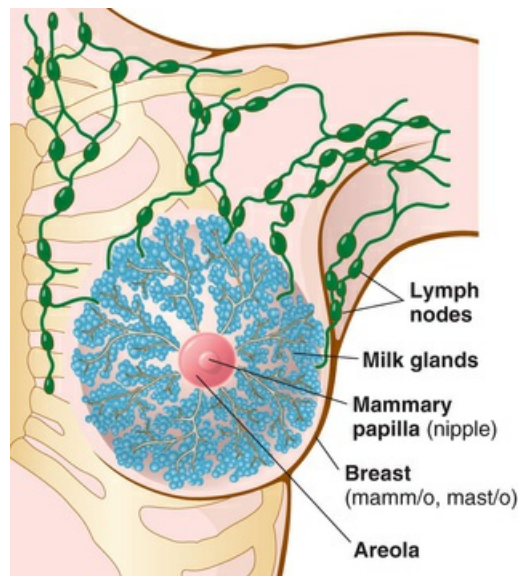
Column I	Column II
1. thyroid scan	A. Measures blood glucose levels
2. exophthalmometry	B. Radioactive compound, injected intravenously, localizes in the thyroid gland; images are produced
3. fasting blood sugar	C. Measures hormones, electrolytes, and sugar in blood and urine
4. thyroid function testing	D. Measures localization of an element necessary for making thyroid hormone
5. CT scan	E. Measures eyeball protrusion
6. serum and urine testing	F. Cross-sectional x-ray images of endocrine organs
	G. Measures T3, T4, and TSH levels in the blood

7. radioactive iodine uptake

Female Reproductive System Anatomy



An egg cell (**ovum**) is produced in the **ovary** and travels through the **fallopian tube**. If a sperm cell is present and fertilization (the union of the egg and sperm cell) takes place, the resulting cell (embryo) may implant in the lining of the **uterus**. The embryo (later called the fetus) develops in the uterus for nine months and is delivered from the body through the **cervix** and **vagina**. (Modified from Chabner D-E: *The Language of Medicine*, ed 11, St. Louis, 2017, Elsevier.)



The **breast** contains glandular tissue that produces milk after delivery of an infant. The **areola** is the dark-pigmented area surrounding the **mammary papilla** (breast nipple). There are numerous **lymph nodes** around the breast and in the underarm (axilla). (Modified from Chabner D-E: *The Language of Medicine*, ed 11, St. Louis, 2017, Elsevier.)

Terminology

Meanings for terminology are found in the *Mini-Dictionary*.

Combining Form	Meaning	Terminology	Meaning
cervic/o	cervix	cervical	
colp/o	vagina	colposcopy	
vagin/o	vagina	vaginitis	
hyster/o	uterus	hysterectomy	
mamm/o	breast	mammogram	
mast/o	breast	mastectomy	
metri/o	uterus	endometrium	
uter/o	uterus	uterine	
o/o	egg	oocyte	
oophor/o	ovary	oophorectomy	
ovari/o	ovary	ovarian cancer	
salping/o	fallopian tube	salpingectomy	

Pathology

Definitions for additional terms in **boldface** are found in the *Mini-Dictionary*.

Amenorrhea: Absence of menstrual flow.

Dysmenorrhea: Painful menstrual flow.

Ectopic pregnancy: Pregnancy (gestation) that is not in the uterus; usually occurs in a fallopian tube.

Endometriosis: Tissue from the inner lining of the uterus (**endometrium**) is found abnormally in other pelvic or abdominal locations (**fallopian tubes, ovaries, or peritoneum**).

Fibroids: Benign tumors in the uterus. Also called a **leiomyoma**; LEI/O means smooth (referring to **visceral muscle** within an internal organ).

Menorrhagia: Excessive discharge of blood (-RRHAGIA) from the uterus during menstruation.

Pelvic inflammatory disease: Inflammation (often caused by bacterial infection) in the region of the pelvis. Because the condition primarily affects the fallopian tubes, it is also called **salpingitis**.

Laboratory Tests and Diagnostic Procedures

Consult [Appendix 2](#) for pronunciation of terms and additional information.

Amniocentesis: Surgical puncture of the amnion (sac surrounding the developing fetus).

Aspiration: Withdrawal of fluid from a cavity or sac. In breast aspiration, a needle is used to remove fluid from cystic lesions in the breast. The fluid is analyzed for the presence of malignant cells.

Colposcopy: Visual examination of the vagina and cervix with a colposcope (a small, magnifying instrument resembling a mounted pair of binoculars).

Conization: Removal of a wedged-shaped section (cone) of the cervix for **biopsy**.

Hysterosalpingography: X-ray imaging of the uterus and fallopian tubes after injection of a contrast agent into the uterus.

Mammography: X-ray imaging (recording) of the breast.

Pap smear: Insertion of an instrument (spatula) into the vagina to obtain a sample of cells from the cervix (neck of the uterus). Microscopic analysis of the smear indicates the presence of cervical cancer.

Pelvic ultrasonography: Recording (imaging) of sound waves as they impact organs in the region

of the hip. In transvaginal ultrasound, a sound probe is placed in the vagina.

Pregnancy test: Measurement of human chorionic gonadotropin (HCG), a hormone in blood and urine that indicates pregnancy.

Treatment Procedures

Cauterization: Heat is used to destroy abnormal tissue, for example, in the lining of the **cervix** (lower neck-like region of the uterus).

Cryosurgery: Use of cold temperatures (often liquid nitrogen) to freeze and destroy tissue (such as the lining of the cervix).

Dilation and curettage (D&C): Widening (dilation or dilatation) of the opening of the cervix and scraping (curettage) of the lining of the uterus to remove tissue and stop prolonged or heavy uterine bleeding.

Hysterectomy: Excision of the uterus either through the abdominal wall (abdominal hysterectomy) or through the vagina (vaginal hysterectomy)

Myomectomy: The surgical removal of **fibroid (myoma)** tissue from the uterus. **Uterine artery embolization** may be used instead to shrink the fibroids. Tiny pellets are injected into the uterine artery. The pellets act as emboli to block blood flow to fibrous tissue.

Tubal ligation: Fallopian tubes are tied off (ligated) and cut to prevent pregnancy.

Abbreviations

CS	Cesarean section (fetus is removed through an abdominal incision)
D&C	Dilation and curettage
DUB	Dysfunctional uterine bleeding (not associated with menstruation)
GYN	Gynecology
HRT	Hormone replacement therapy (estrogen and progesterone)
IVF	In vitro fertilization (egg and sperm are combined outside the body in a laboratory container; fertilized eggs are injected into the uterus for pregnancy)
OB	Obstetrics (labor and delivery of a fetus)
PID	Pelvic inflammatory disease (salpingitis, oophoritis, endometritis; leading causes are sexually transmitted infections)
STI	Sexually transmitted infection; also called STD (sexually transmitted disease)
TAH-BSO	Total abdominal hysterectomy with bilateral salpingo-oophorectomy (entire uterus and both fallopian tubes and ovaries are removed)

Matching Exercises

The following exercises will help you review terminology related to the female reproductive system. Answers begin on [page 292](#).

A Match the term in Column I with its meaning in Column II.

Column I	Column II
1. ovary	A. Muscular passageway from the uterus to the outside of the body
2. cervix	B. Neck (lower portion) of the uterus
3. fallopian tube	C. One of two paired organs in the female abdomen that produce egg cells and hormones
4. vagina	D. One of two paired tubes that lead from the ovaries to the uterus
5. uterus	E. One of two paired organs containing glands that produce milk after childbirth
6. breast	F. Muscular organ that holds and provides nourishment for the developing fetus

B Match the combining form in Column I with its meaning in Column II.

Column I	Column II
1. oophor/o	A. Uterus
2. colp/o	B. Fallopian tube
3. salping/o	C. Neck of the uterus
4. hyster/o	D. Ovary

5. cervic/o	_____	E. Vagina
6. mast/o	_____	F. Breast

C Match the medical term in Column I with its meaning in Column II.

Column I	Column II	
1. salpingectomy	_____	A. Visual examination of the vagina
2. mammography	_____	B. Pertaining to the lower, neck-like region of the uterus
3. vaginitis	_____	C. Inflammation of the breast
4. colposcopy	_____	D. Removal of a fallopian tube
5. hysterectomy	_____	E. Inner lining of the uterus
6. cervical	_____	F. X-ray imaging of the breast
7. endometrium	_____	G. Resection of the uterus
8. mastitis	_____	H. Inflammation of the vagina

D Match the pathologic condition in Column I with its meaning in Column II.

Column I	Column II	
1. fibroids	_____	A. Absence of menstrual flow
2. dysmenorrhea	_____	B. Excessive discharge of blood from the uterus between menstrual periods
3. endometriosis	_____	C. Leiomyomas (benign muscle growths) in the uterus
4. ectopic pregnancy	_____	D. Uterine tissue found in sites (ovary, fallopian tubes) other than in the uterus
5. amenorrhea	_____	E. Painful menstrual flow
6. pelvic inflammatory disease	_____	F. Salpingitis
7. menorrhagia	_____	G. Embryo develops outside the uterus

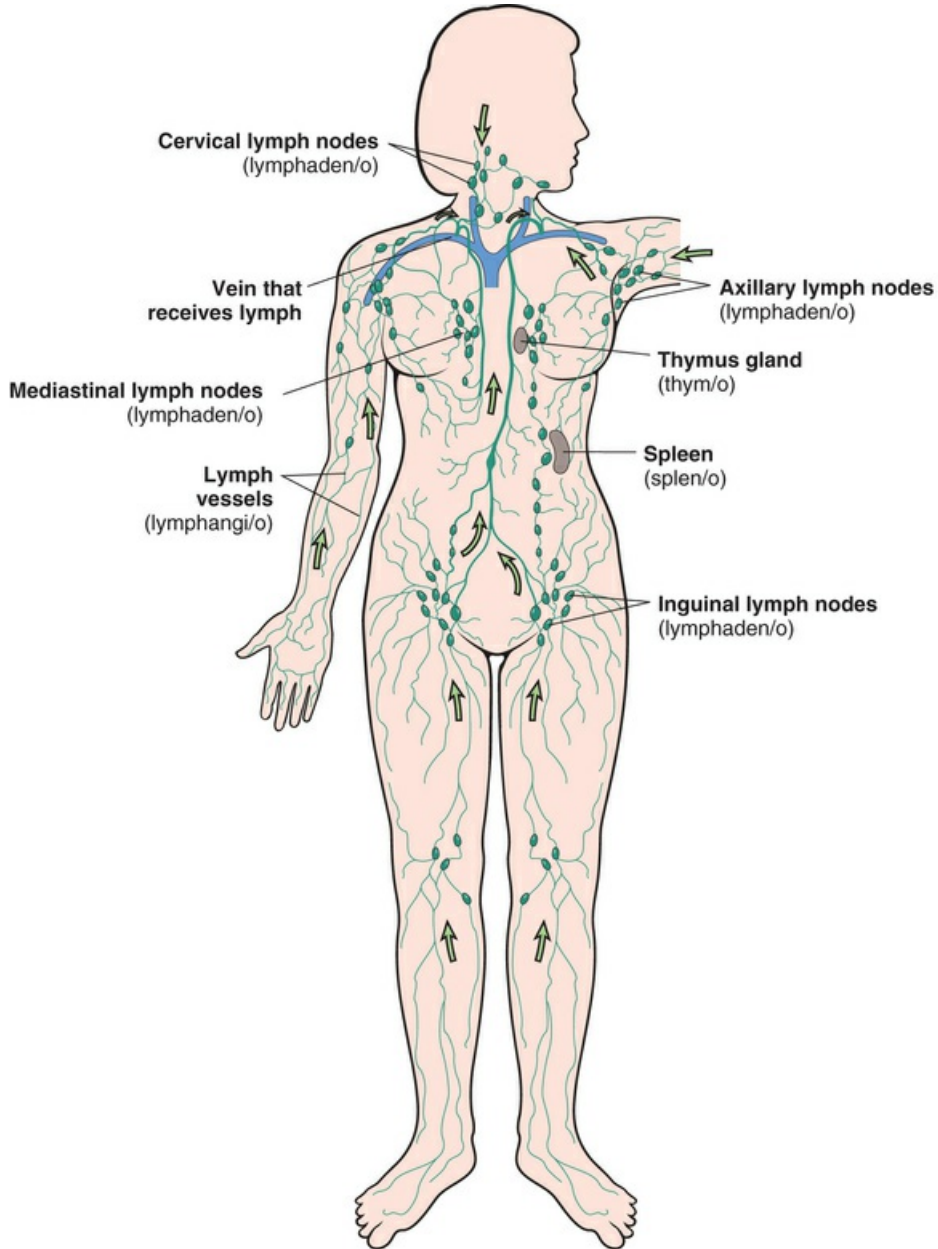
E Match the test or procedure in Column I with its description in Column II.

Column I	Column II	
1. pregnancy test	_____	A. Endoscopic visual examination of the vagina
2. pelvic ultrasonography	_____	B. Withdrawal of fluid from a cavity or sac
3. conization	_____	C. Removal of a section of the cervix for biopsy
4. colposcopy	_____	D. X-ray imaging of the breast
5. mammography	_____	E. X-ray examination of the uterus and fallopian tubes
6. Pap smear	_____	F. Sound wave image of organs in the hip region
7. hysterosalpingography	_____	G. Secretions from the vagina and cervix are examined microscopically
8. aspiration	_____	H. Measurement of HCG levels
9. amniocentesis	_____	I. Surgical puncture to remove fluid from the sac surrounding the fetus

F Match the treatment procedure in Column I with its description in Column II.

Column I	Column II	
1. myomectomy	_____	A. Use of cold temperatures to freeze and destroy tissue
2. cryosurgery	_____	B. Fallopian tubes are tied to prevent pregnancy
3. cauterization	_____	C. Removal of fibroids from the uterus
4. tubal ligation	_____	D. Widening the cervix and scraping the lining of the uterus
5. D&C	_____	E. Use of heat to destroy abnormal tissue

Lymphatic System Anatomy



Lymph originates in the tissue spaces around cells and travels in **lymph vessels** and through **lymph nodes** to a large vein in the neck, where it enters the bloodstream. Arrows in the figure indicate the direction of lymph flow. Lymph contains white blood cells (lymphocytes), which help the body fight disease. The **spleen** produces lymphocytes and disposes of dying blood cells. The **thymus gland** stimulates the production of lymphocytes. (Modified from Chabner D-E: *The Language of Medicine*, ed 11, St. Louis, 2017, Elsevier.)

Terminology

Meanings for terminology are found in the *Mini-Dictionary*.

Combining Form	Meaning	Terminology	Meaning
lymph/o	lymph fluid	lymphoma	
lymphaden/o	lymph node ("gland")	lymphadenectomy	

		lymphadenopathy
lymphangi/o	lymph vessel	lymphangiectasis
splen/o	spleen	splenomegaly
thym/o	thymus gland	thymoma

Pathology

Definitions for additional terms in **boldface** are found in the *Mini-Dictionary*.

Acquired immunodeficiency syndrome (AIDS): Suppression or deficiency of the immune response (destruction of **lymphocytes**) caused by exposure to **human immunodeficiency virus (HIV)**.

Lymphoma: Malignant tumor of lymph nodes and lymphatic tissue. **Hodgkin lymphoma** is an example of a lymphoma.

Mononucleosis: Acute infectious disease with enlargement of lymph nodes and increased numbers of **lymphocytes** and **monocytes** in the bloodstream.

Sarcoidosis: Inflammatory disease in which small nodules, or tubercles, form in lymph nodes and other organs. SARC/O means flesh, and -OID means resembling.

Laboratory Tests and Diagnostic Procedures

Consult [Appendix 2](#) for pronunciation of terms and additional information.

Computed tomography (CT) scan: X-ray views in the transverse plane for the diagnosis of abnormalities in lymphoid organs (lymph nodes, spleen, and thymus gland).

ELISA (enzyme-linked immunosorbent assay): Test to screen for antibodies to the **human immunodeficiency virus (HIV)**, which causes **acquired immunodeficiency syndrome (AIDS)**.

Western blot test: A blood test to detect the presence of antibodies to specific antigens, such as the **human immunodeficiency virus**. It is regarded as a more precise test than the ELISA.

Treatment Procedures

Chemotherapy: Treatment with powerful drugs to kill cancer cells (**Hodgkin lymphoma, non-Hodgkin lymphoma, and multiple myeloma**) and viruses such as the **human immunodeficiency virus**.

Radiotherapy (radiation therapy): Treatment with high-dose radiation to destroy malignant lesions in the body.

Abbreviations

AIDS	Acquired immunodeficiency syndrome
ELISA	Enzyme-linked immunosorbent assay (test to detect anti-HIV antibodies)
HAART	Highly active antiretroviral therapy (for AIDS)
HIV	Human immunodeficiency virus
IgA, IgD, IgE, IgG, IgM	Immunoglobulins (antibodies)
MAC	<i>Mycobacterium avium</i> complex (a group of pathogens that cause lung disease in patients with depressed immune systems)
PCP	<i>Pneumocystis pneumonia</i> (opportunistic infection seen in patients with AIDS)

Matching Exercises

The following exercises will help you review terminology related to the lymphatic system. Answers begin on [page 292](#).

A Match the term in Column I with its meaning in Column II.

Column I		Column II
1. lymph nodes	_____	A. Blood-forming organ in early life; later a storage organ for red blood cells and a source of lymphocytes
2. thymus	_____	B. Gland in the mediastinum; produces lymphocytes, which play an important role in immunity
3. lymph	_____	C. Stationary collections of lymph tissue throughout the body
4. spleen	_____	D. Clear fluid, present in tissue spaces, that circulates in lymph vessels
5. lymph vessels	_____	E. Small tubes that carry lymph fluid throughout the body

B Match the combining form in Column I with its meaning in Column II.

Column I		Column II
1. thym/o	_____	A. Spleen
2. lymphangi/o	_____	B. Lymph fluid
3. lymphaden/o	_____	C. Thymus gland
4. splen/o	_____	D. Lymph vessels
5. lymph/o	_____	E. Lymph nodes (glands)

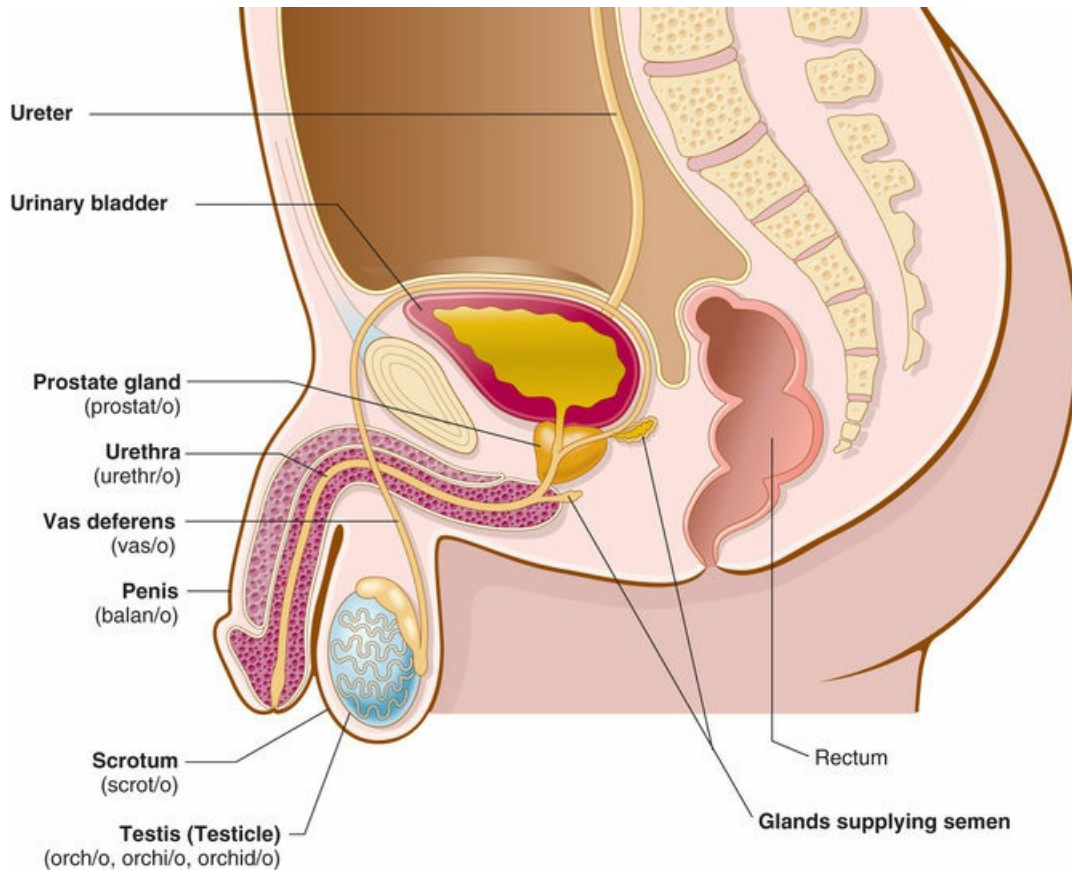
C Match the medical term in Column I with its meaning in Column II.

Column I		Column II
1. lymphadenopathy	_____	A. Malignant tumor of lymph nodes and lymphatic tissue
2. lymphangiectasis	_____	B. Acute infectious disease with enlargement of lymph nodes and increase in lymphocytes and monocytes
3. splenomegaly	_____	C. Malignant tumor of a mediastinal lymphocyte-producing gland
4. lymphoma	_____	D. Widening, dilation of lymph vessels
5. lymphadenectomy	_____	E. Enlargement of an abdominal organ that produces lymphocytes
6. mononucleosis	_____	F. Excision of lymph nodes
7. thymoma	_____	G. Disease of lymph nodes

D Match the procedure or test in Column I with its description in Column II.

Column I		Column II
1. ELISA	_____	A. Treatment with high-dose radiation to destroy malignant tissue
2. Western blot	_____	B. X-ray images in a cross-sectional plane for diagnosis of lymph node abnormalities
3. chemotherapy	_____	C. Precise blood test to detect antibodies to specific antigens, as in HIV infection
4. CT scan	_____	D. Screening test for antibodies to the AIDS virus
5. radiotherapy	_____	E. Treatment with powerful drugs to kill cancer cells

Male Reproductive System Anatomy



Sperm cells are produced in the testes (*singular: testis*) and travel up into the body, through the **vas deferens**, and around the urinary bladder. The vas deferens unites with the **urethra**, which opens to the outside of the body through the **penis**. The **prostate** and the other glands near the **urethra** produce a fluid (semen) that leaves the body with sperm cells. (Modified from Chabner D-E: *The Language of Medicine*, ed 11, St. Louis, 2017, Elsevier.)

Terminology

Meanings for terminology are found in the *Mini-Dictionary*.

Combining Form	Meaning	Terminology	Meaning
balan/o	penis	balanitis	
orch/o	testis	orchitis	
orchi/o	testis; pl. testes	orchiectomy	
orchid/o	testis	orchidectomy	
prostat/o	prostate gland	prostatectomy	
scrot/o	scrotum	scrotal	
urethr/o	urethra	urethritis	
vas/o	vas deferens	vasectomy	

Pathology

Definitions for additional terms in **boldface** are found in the *Mini-Dictionary*.

Benign prostatic hyperplasia: Noncancerous enlargement of the prostate gland.

Cryptorchism: Condition of undescended testis. The testis is not in the scrotal sac at birth.

CRYPT/O means hidden.

Hydrocele: Sac of clear fluid (swelling) in the scrotum. HYDR/O means water, and -CELE indicates a hernia (a bulging or swelling).

Prostatic carcinoma: Cancer of the prostate gland (prostate cancer).

Sexually transmitted infections: These affect both males and females and are spread by sexual or other genital contact. Examples are **chlamydial infection, gonorrhea, herpes genitalis,** and **syphilis.**

Testicular carcinoma: Malignant tumor of the testis. An example is a **seminoma.**

Varicocele: Enlarged, swollen veins near a testicle. VARIC/O means swollen veins.

Laboratory Tests and Diagnostic Procedures

Consult [Appendix 2](#) for pronunciation of terms and additional information.

Digital rectal examination (DRE): Examination of the prostate gland with finger palpation through the rectum.

Prostate-specific antigen (PSA): Measurement of the amount of PSA in the blood. Higher than normal levels are associated with prostate enlargement and cancer.

Semen analysis: Measurement of the number, shape, and motility of sperm cells.

Treatment Procedures

Orchiopexy: Surgical fixation (-PEXY) of an undescended testicle in a young male infant.

Transurethral resection of the prostate gland (TURP): The removal of portions of the prostate gland with an **endoscope** inserted into the urethra. **Photoselective vaporization of the prostate (GreenLight PVP)** is a newer technique that uses a laser to treat benign prostatic hyperplasia.

Vasectomy: Procedure in which the vas deferens on each side is cut, a piece is removed, and the free ends are folded and ligated (tied) with sutures. Vasectomy produces sterilization so that sperm are not released with semen.

Abbreviations

BPH	Benign prostatic hyperplasia
DRE	Digital rectal examination
GU	Genitourinary
PSA	Prostate-specific antigen
STI	Sexually transmitted infection; also called STD (sexually transmitted disease)
TURP	Transurethral resection of the prostate gland

Matching Exercises

The following exercises will help you review terminology related to the male reproductive system. Answers begin on [page 292](#).

A Match the term in Column I with its meaning in Column II.

Column I	Column II
1. scrotum	_____ A. One of two paired male organs in the scrotum that produces sperm cells and male hormones
2. penis	_____ B. External male organ, containing the urethra, through which both urine and semen (sperm cells and fluid) leave the body
3. vas deferens	_____ C. Sac on the outside of the body that contains the testes
4. testis	_____ D. One of two tubes that carry sperm cells from the testes to the outside of the body
5. prostate	_____ E. Male organ that surrounds the base of the urinary bladder and produces fluid that leaves the body with sperm

B Match the combining form in Column I with its meaning in Column II.

Column I	Column II
1. prostat/o	A. Tube leading from the urinary bladder to the outside of the body
2. vas/o	B. Gland that produces fluid portion of semen
3. orch/o	C. Penis
4. scrot/o	D. Testis
5. balan/o	E. Tube carrying sperm cells from the testis to the ejaculatory duct and urethra
6. urethr/o	F. Sac containing the testes

C Match the medical term in Column I with its meaning in Column II.

Column I	Column II
1. urethritis	A. Resection of the prostate gland
2. scrotal	B. Inflammation of the penis
3. vasectomy	C. Inflammation of a testis
4. orchitis	D. Inflammation of the urethra
5. prostatectomy	E. Pertaining to the sac containing the testes
6. orchidectomy	F. Resection of a piece of each vas deferens
7. balanitis	G. Excision of a testicle

D Match the pathologic condition in Column I with its meaning in Column II.

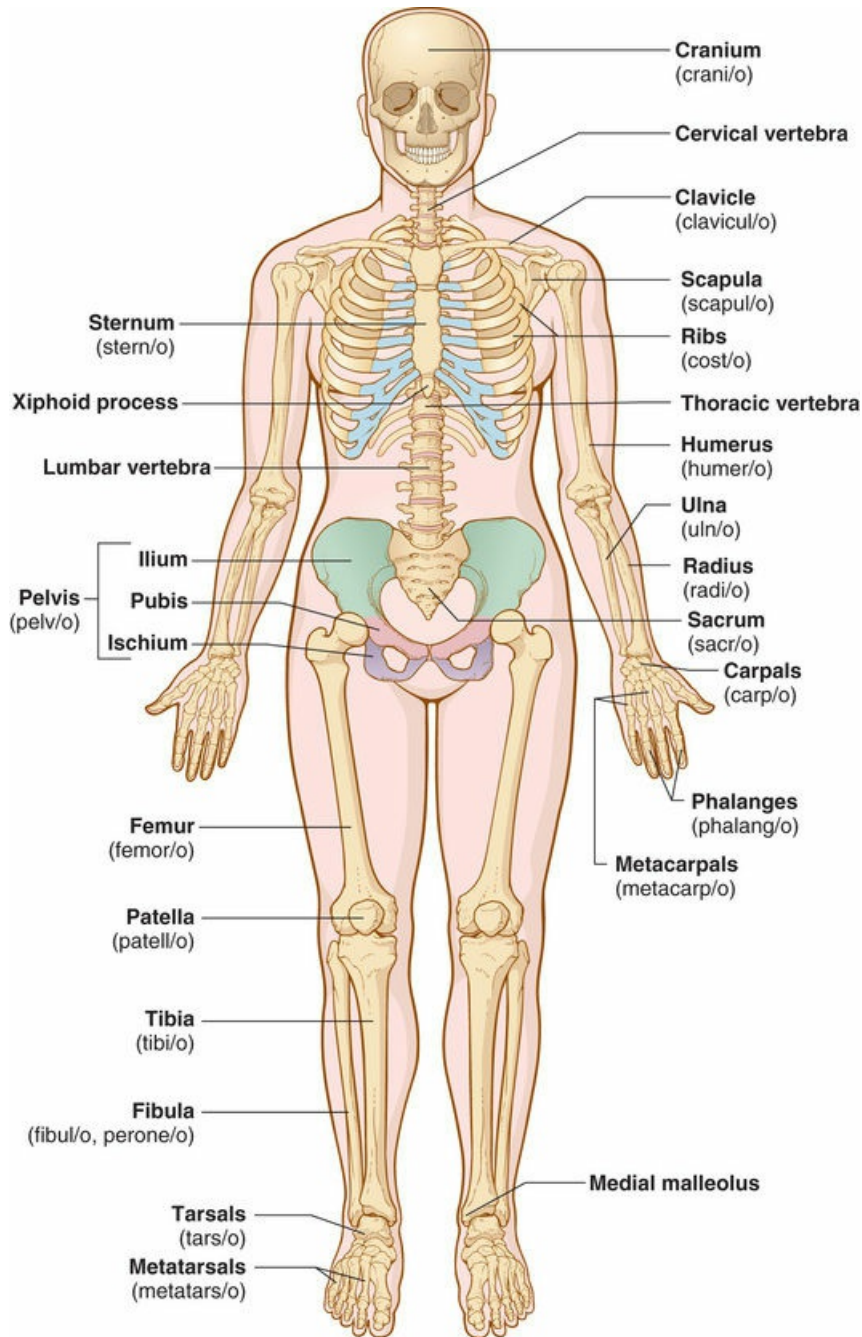
Column I	Column II
1. varicocele	A. Undescended testicle
2. benign prostatic hyperplasia	B. Malignant tumor of the prostate gland
3. hydrocele	C. Hernia (collection of fluid) in the scrotal sac
4. testicular carcinoma	D. Malignant tumor; one type is a seminoma
5. prostatic carcinoma	E. Swollen, twisted veins near the testis
6. cryptorchism	F. Nonmalignant enlargement of the prostate gland

E Match the test or procedure in Column I with its description in Column II.

Column I	Column II
1. orchiopexy	A. Measurement of the number, shape, and motility of sperm cells
2. vasectomy	B. Measures blood levels of prostate-specific antigen
3. TURP	C. Examination of the prostate gland with finger palpation through the rectum
4. DRE	D. Removal of portions of the prostate gland with an endoscope inserted into the urethra
5. semen analysis	E. Surgical fixation of an undescended testicle
6. PSA test	F. Two tubes that carry sperm from the testicles are cut and tied off

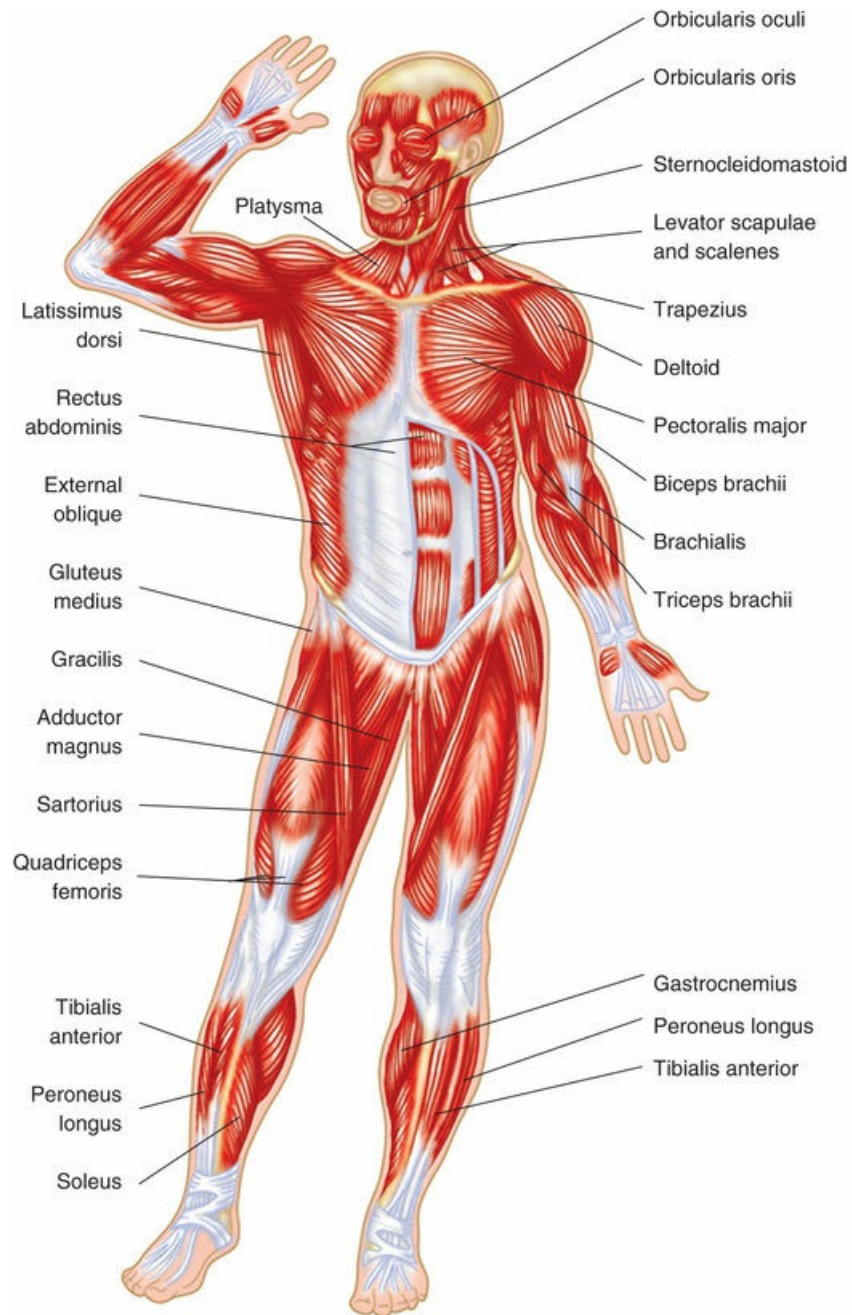
Musculoskeletal System

Anatomy

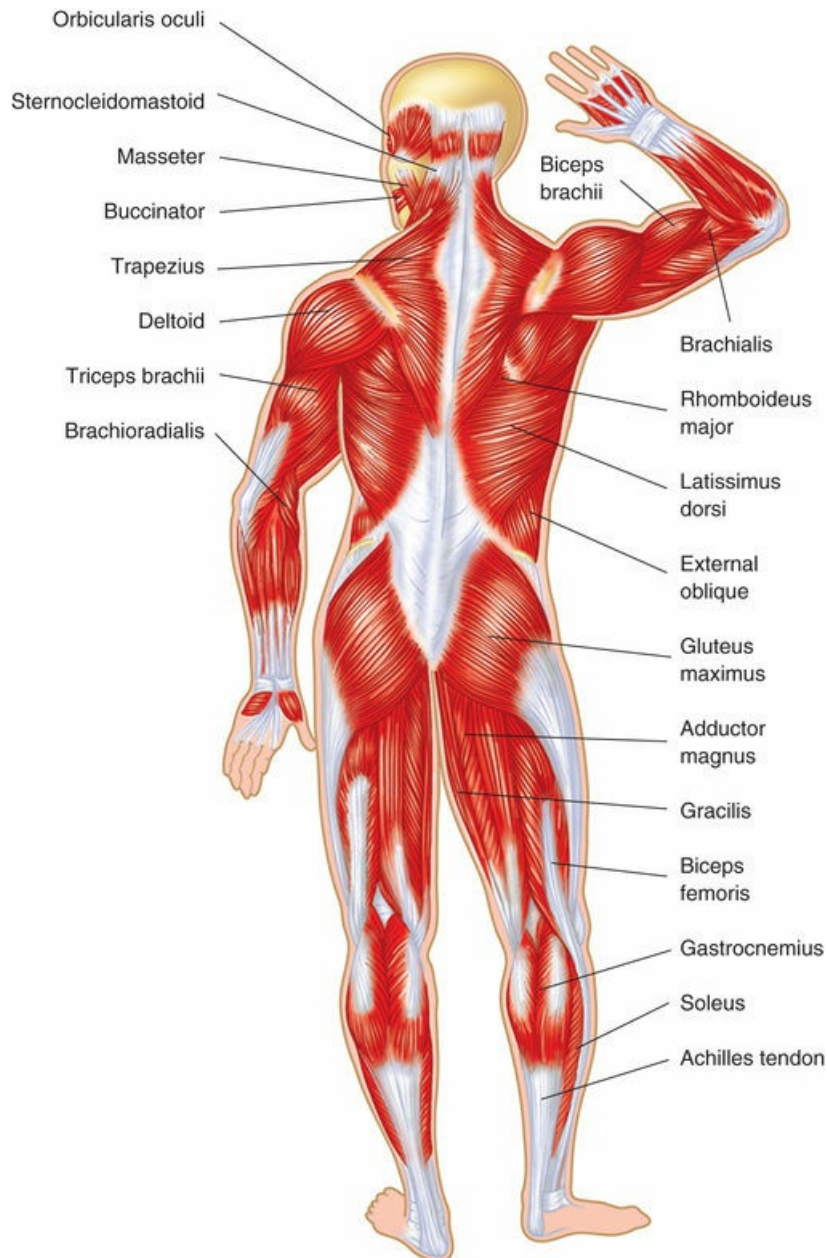


Bones are connected to muscles that contract to move the body. Joints are the spaces between bones. Near the joints are ligaments that connect bones to other bones and tendons that connect bones to muscles. (Modified from Chabner D-E: *The Language of Medicine*, ed 11, St. Louis, 2017, Elsevier.)

For your reference, included here are anterior and posterior views of superficial muscles in the body.



The anterior superficial muscles. (Modified from *Miller-Keane Encyclopedia & Dictionary of Medicine, Nursing, & Allied Health*, ed 7, Philadelphia, 2003, Saunders.)



The posterior superficial muscles. (Modified from *Miller-Keane Encyclopedia & Dictionary of Medicine, Nursing, & Allied Health*, ed 7, Philadelphia, 2003, Saunders.)

Terminology

Meanings for terminology are found in the *Mini-Dictionary*.

Combining Form	Meaning	Terminology	Meaning
arthr/o	joint	arthroscopy	
chondr/o	cartilage	chondroma	
cost/o	rib	costochondritis	
crani/o	skull	craniotomy	
ligament/o	ligament	ligamentous	
muscul/o	muscle	muscular	
my/o	muscle	myosarcoma	
myos/o	muscle	myositis	
myel/o	bone marrow	myelodysplasia	
oste/o	bone	osteomyelitis	
pelv/o	pelvis, hipbone	pelvic	
spondyl/o	vertebra	spondylosis	
vertebr/o	vertebra	intervertebral	

ten/o	tendon	tenorrhaphy _____
tendin/o	tendon	tendinitis _____

Pathology

Definitions for additional terms in **boldface** are found in the *Mini-Dictionary*.

Ankylosing spondylitis: Chronic, progressive **arthritis** with stiffening (**ankylosis**) of joints, primarily of the spine and hip.

Carpal tunnel syndrome: Compression of the median nerve as it passes between the ligament and the bones and tendons of the wrist.

Gouty arthritis: Inflammation of joints caused by excessive uric acid. Also called **gout**.

Muscular dystrophy: An inherited disorder characterized by progressive weakness and degeneration of muscle fibers.

Osteoporosis: Decrease in bone density with thinning and weakening of bone. -POROSIS means condition of containing passages or spaces.

Rheumatoid arthritis: Chronic inflammation of joints; pain, swelling, and stiffening, especially in the small joints of the hands and feet. RHEUMAT/O means flowing, descriptive of the swelling in joints.

Laboratory Tests and Diagnostic Procedures

Consult [Appendix 2](#) for pronunciation of terms and additional information.

Antinuclear antibody (ANA) test: Test in which a sample of plasma is tested for the presence of antibodies found in patients with systemic lupus erythematosus.

Arthrocentesis: Surgical puncture to remove fluid from a joint.

Arthrography: X-ray imaging of a joint.

Arthroscopy: Visual examination of a joint with an arthroscope.

Bone density test: Low-energy x-rays are used to image bones in the spinal column, pelvis, and wrist to detect areas of bone deficiency. Also called bone density scanning, dual-energy x-ray absorptiometry (DEXA), or bone densitometry.

Bone scan: Procedure in which a radioactive substance is injected intravenously and its uptake in bones is measured with a special scanning device.

Calcium level: Measurement of the amount of calcium in a sample of blood (serum). This test is important in evaluating diseases of bone.

Electromyography (EMG): Recording of the electrical activity of muscle tissue. This test reveals the strength of muscles.

Erythrocyte sedimentation rate (ESR): Measurement of the rate at which red blood cells fall to the bottom of a test tube. High sedimentation rates are associated with inflammatory diseases such as **rheumatoid arthritis**.

Muscle biopsy: The removal of muscle tissue for microscopic examination.

Uric acid test: Measurement of the amount of uric acid (nitrogenous waste) in a sample of blood. High uric acid levels are associated with gouty arthritis.

Treatment Procedures

Arthroplasty: Surgical repair of a joint. Total hip arthroplasty is the replacement of the head of the femur (thigh bone) and acetabulum (cup-shaped portion of the hip socket) with artificial parts (**prostheses**) that are cemented into the bone.

Laminectomy: Removal of a piece of backbone (lamina) to relieve pressure on nerves from a herniated disc.

Microscopic discectomy: Surgical removal of a herniated intervertebral disc with an incision that is 1 to 2 inches long and visualization of the surgical field with an operating microscope.

Vertebroplasty: Surgical repair of vertebrae. Special cement is injected into backbones to strengthen them and to relieve pain caused by compression fractures.

Abbreviations

ACL	Anterior cruciate ligament (of the knee)
ANA	Antinuclear antibody
C1-C7	Cervical vertebrae
Ca	Calcium
DEXA	Dual-energy x-ray absorptiometry
DJD	Degenerative joint disease
DOMS	Delayed-onset muscle soreness
EMG	Electromyography
ESR	Erythrocyte sedimentation rate
IM	Intramuscular
L1-L5	Lumbar vertebrae
NSAID	Nonsteroidal anti-inflammatory drug (prescribed to treat joint and muscle pain)
Ortho	Orthopedics (<i>or</i> orthopaedics)
PT	Physical therapy
ROM	Range of motion
T1-T12	Thoracic vertebrae

Matching Exercises

The following exercises will help you review terminology related to the musculoskeletal system. Answers begin on [page 293](#).

A Match the term in Column I with its description in Column II.

Column I	Column II
1. cranium	A. Finger bones
2. clavicle	B. Thigh bone
3. humerus	C. Kneecap
4. radius	D. Lower arm bone on the thumb side
5. ulna	E. Collarbone
6. carpals	F. Tailbone
7. metacarpals	G. Breastbone
8. phalanges	H. Skull
9. scapula	I. Ankle bones
10. sternum	J. Lower arm bone (little finger side)
11. tarsals	K. Upper arm bone
12. metatarsals	L. Smaller of the lower leg bones
13. fibula	M. Hip bone
14. tibia	N. Lower part of the backbone near the hip
15. patella	O. Bones surrounding the chest cavity
16. sacrum	P. Larger of the lower leg bones
17. coccyx	Q. Hand bones
18. pelvis	R. Wrist bones
19. femur	S. Foot bones
20. ribs	T. Shoulder bone

B Match the combining form in Column I with its meaning in Column II.

--	--

Column I	Column II
1. crani/o	A. Backbone
2. arthr/o	B. Cartilage
3. oste/o	C. Joint
4. cost/o	D. Skull
5. pelv/o	E. Rib
6. my/o	F. Muscle
7. ten/o	G. Hip bone
8. chondr/o	H. Bone
9. spondyl/o	I. Connects muscles to bones
10. ligament/o	J. Connects bones to other bones

C Match the medical term in Column I with its meaning in Column II.

Column I	Column II
1. myelodysplasia	A. Incision of the skull
2. intervertebral	B. Inflammation of cartilage attached to ribs
3. osteomyelitis	C. Suture of a tendon
4. arthroscopy	D. Inflammation of bone and bone marrow
5. costochondritis	E. Pertaining to between the backbones
6. chondroma	F. Benign tumor of cartilage tissue
7. tenorrhaphy	G. Abnormal growth of bone marrow cells
8. myosarcoma	H. Malignant tumor of muscle tissue
9. craniotomy	I. Visual examination of a joint

D Match the pathologic condition in Column I with its meaning in Column II.

Column I	Column II
1. gouty arthritis	A. Chronic, progressive arthritis with stiffening of joints between the backbones
2. carpal tunnel syndrome	B. Compression of the median nerve in the wrist
3. rheumatoid arthritis	C. High levels of uric acid with inflammation of joints
4. osteoporosis	D. Weakness and degeneration of muscle fibers; congenital condition
5. ankylosing spondylitis	E. Chronic inflammation of joints, especially small bones in the hands and feet
6. muscular dystrophy	F. Decrease in bone density with thinning and weakening of bone

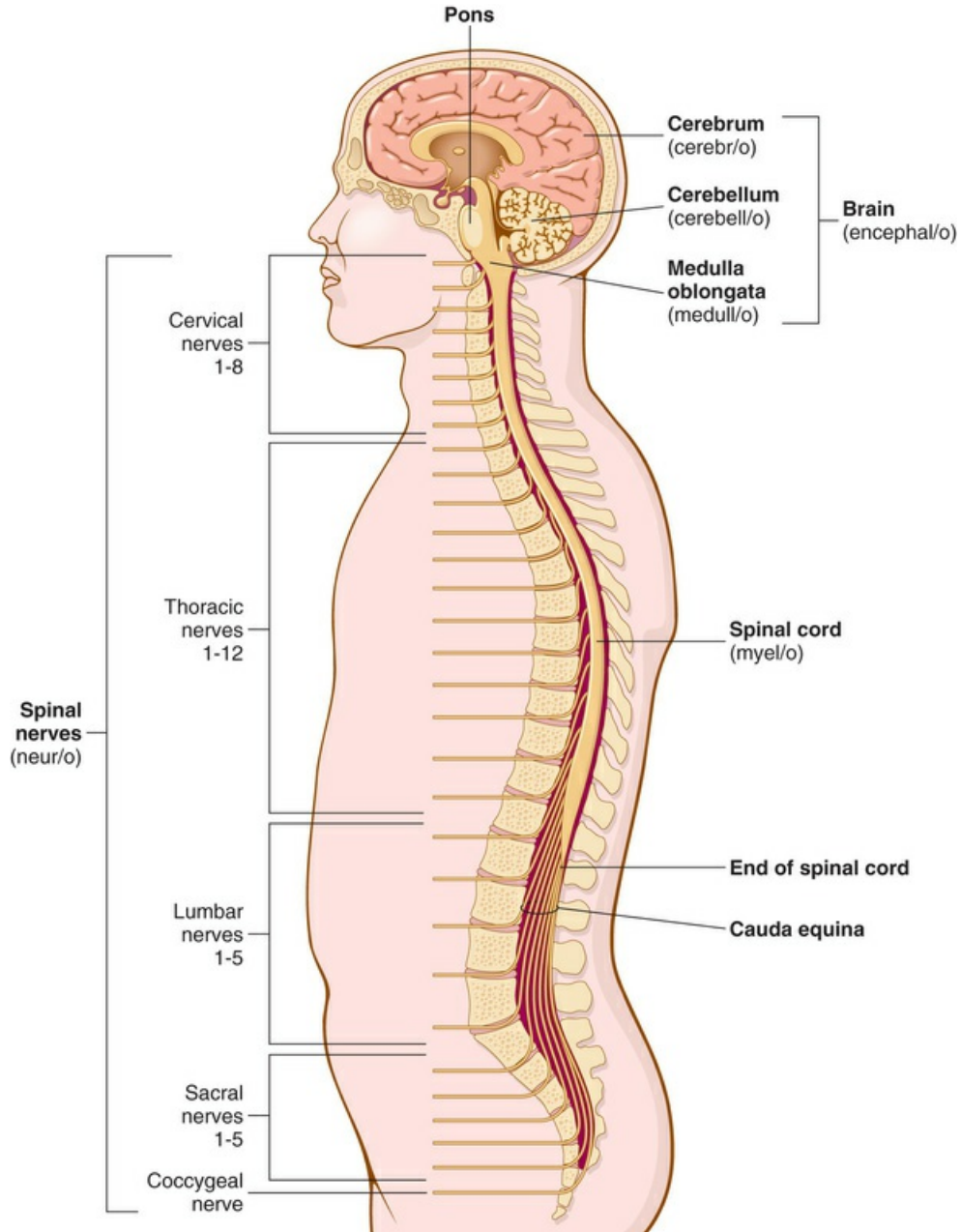
E Match the test or procedure in Column I with its description in Column II.

Column I	Column II
1. arthrocentesis	A. Recording the strength of muscle contraction
2. serum calcium	B. Measures sedimentation rate of red blood cells; indicates inflammation
3. electromyography	C. Plasma is tested for antibodies that are present in patients with systemic lupus erythematosus
4. bone scan	D. Removal of muscle tissue for microscopic analysis
5. ESR	E. Surgical puncture to remove fluid from a joint
6. ANA test	F. Radioactive substance is injected intravenously and uptake is measured in bone tissue
7. muscle biopsy	G. Measurement of an element in the blood that is necessary for normal bone formation
8. uric acid test	H. X-ray imaging of a joint
9. arthroscopy	I. Measurement of the amount of a substance in blood that is associated with gouty arthritis
10. arthrography	J. Visual examination of a joint using an endoscope

F Match the treatment procedure in Column I with its description in Column II.

Column I	Column II
1. laminectomy	A. Surgical repair of a joint
2. microscopic discectomy	B. Surgical repair of a backbone
3. arthroplasty	C. Removal of a herniated disc using a tiny incision and an operating microscope
4. vertebroplasty	D. Surgical removal of a portion of a vertebra to allow visualization and removal of a portion of a disk

Nervous System Anatomy



The central nervous system consists of the brain and the spinal cord. The peripheral nervous system includes the nerves that carry messages to and from the brain and spinal cord. Spinal nerves carry messages to and from the spinal cord, and the cranial nerves (not pictured) carry messages to and from the brain.

Terminology

Meanings for terminology are found in the *Mini-Dictionary*.

Combining Form	Meaning	Terminology	Meaning
cerebell/o	cerebellum	cerebellar	
cerebr/o	cerebrum	cerebral	
encephal/o	brain	encephalitis	

medull/o	medulla oblongata	medullary _____
myel/o	spinal cord	myelitis _____
neur/o	nerve	neuropathy _____

Pathology

Definitions for additional terms in **boldface** are found in the *Mini-Dictionary*.

Alzheimer disease: Brain disorder marked by deterioration of mental capacity (**irreversible dementia**).

Cerebrovascular accident: Damage to the blood vessels of the cerebrum, leading to loss of blood supply to brain tissue; a **stroke**.

Concussion: Traumatic brain injury that can cause bruising, damage to blood vessels, and injury to nerves. Loss of consciousness may occur.

Epilepsy: Chronic brain disorder characterized by recurrent **seizures**.

Glioblastoma: Malignant brain tumor arising from **glial cells**. BLAST means immature.

Hemiplegia: Paralysis (-PLEGIA) that affects the right or the left half of the body.

Meningitis: Inflammation of the **meninges** (membranes surrounding the brain and spinal cord).

Multiple sclerosis: Destruction of the **myelin sheath** on nerve cells in the central nervous system (brain and spinal cord), with replacement by plaques of sclerotic (hard) tissue.

Paraplegia: Paralysis that affects the lower portion of the body. From a Greek word meaning “to strike” (-PLEGIA) on one side (PARA-). This term was previously used to describe **hemiplegia**.

Syncope: Fainting; sudden and temporary loss of consciousness as a result of inadequate flow of blood to the brain.

Laboratory Tests and Diagnostic Procedures

Consult [Appendix 2](#) for pronunciation of terms and additional information.

Cerebral angiography: X-ray imaging of the blood vessels in the brain after the injection of contrast material into an artery.

Cerebrospinal fluid (CSF) analysis: Chemical tests (for sodium, chloride, protein, and glucose), cell counts, cultures, and bacterial smears on samples of CSF to detect diseases of the brain or meninges. A lumbar puncture is used to remove CSF for analysis.

Computed tomography (CT) scan: Cross-sectional x-ray images of the brain and spinal cord (with and without contrast).

Electroencephalography (EEG): Recording of the electrical activity within the brain.

Lumbar puncture (LP): Introduction of hollow needle into a space surrounding the spinal cord to withdraw cerebrospinal fluid (CSF) for analysis. Pressure of CSF is measured and contrast may be injected for imaging (myelography). Also known as a “spinal tap.”

Magnetic resonance imaging (MRI): Magnetic waves and radiofrequency waves are used to create images of the brain and spinal cord.

Positron emission tomography (PET) scan: Uptake of radioactive material into the brain shows how the brain uses glucose and gives information about brain function.

Treatment Procedures

Stereotactic radiosurgery: This is a nonsurgical type of radiation therapy used to treat abnormalities and small tumors of the brain. Also called Cyberknife® or stereotactic radiotherapy, this treatment can deliver precisely targeted radiation in fewer high-dose treatments than traditional therapy.

Transcutaneous electrical nerve stimulation (TENS): A battery-powered device delivers stimulation to nerves to relieve acute and chronic pain.

Abbreviations

AD	Alzheimer disease
CNS	Central nervous system
CSF	Cerebrospinal fluid
CVA	Cerebrovascular accident (stroke)
EEG	Electroencephalography
LP	Lumbar puncture
MS	Multiple sclerosis
TENS	Transcutaneous electrical nerve stimulation
TIA	Transient ischemic attack (temporary interference with blood supply to the brain); "mini-stroke."

Matching Exercises

The following exercises will help you review terminology related to the nervous system. Answers begin on [page 293](#).

A Match the term in Column I with its description in Column II.

Column I	Column II
1. cerebrum	A. Lower part of the brain, nearest to the spinal cord; it controls breathing and heart beat
2. spinal cord	B. Collection of nerves that are within the spinal cavity, surrounded by backbones
3. cerebellum	C. Largest part of the brain; controls body movements, thought, reasoning, vision, hearing, speech
4. medulla oblongata	D. Nerves that transmit messages to and from the spinal cord
5. spinal nerves	E. Lower back part of the brain that controls muscular coordination and balance

B Match the combining form in Column I with its meaning in Column II.

Column I	Column II
1. cerebell/o	A. Nerve
2. medull/o	B. Cerebellum
3. myel/o	C. Brain
4. cerebr/o	D. Spinal cord
5. encephal/o	E. Medulla oblongata
6. neur/o	F. Cerebrum

C Match the medical term in Column I with its meaning in Column II.

Column I	Column II
1. myelitis	A. Disease of nerves
2. cerebral	B. Pertaining to the largest part of the brain
3. medullary	C. Pertaining to the posterior portion of the brain that controls equilibrium
4. encephalitis	D. Inflammation of the spinal cord
5. neuropathy	E. Inflammation of the brain
6. cerebellar	F. Pertaining to the lower part of the brain closest to the spinal cord

D Match the pathologic condition in Column I with its meaning in Column II.

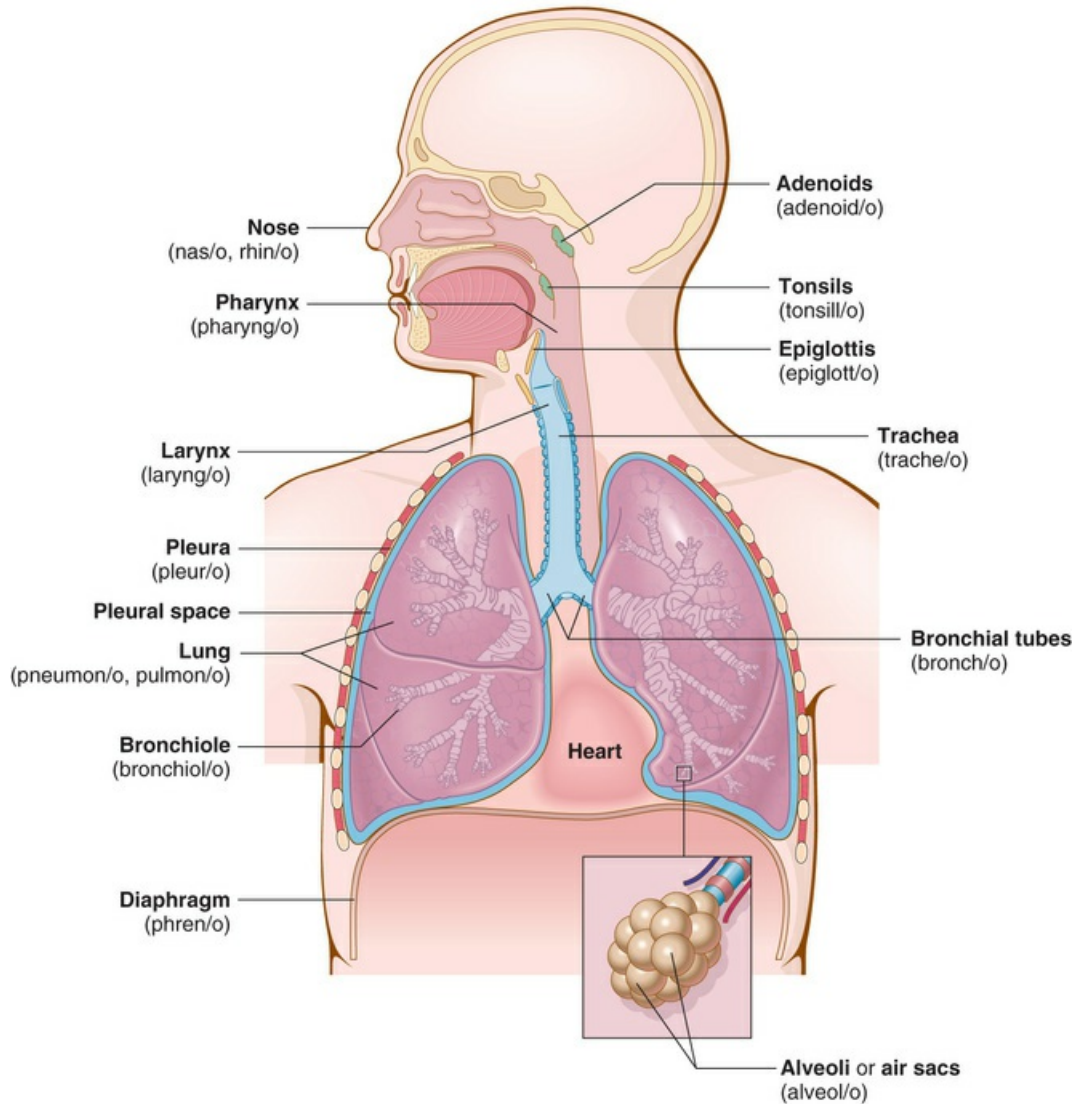
Column I	Column II
1. cerebrovascular accident	A. Inflammation of the membrane surrounding the brain and spinal cord.
2. multiple sclerosis	B. Brain disorder marked by deterioration in mental activity (dementia)
3. concussion	C. Fainting
4. syncope	D. Paralysis on one side of the body
5. epilepsy	E. Damage to blood vessels in the brain; a stroke
	F. Destruction of myelin sheath around nerve cells in the CNS

6. meningitis	_____	G. Blunt injury to the brain severe enough to cause loss of consciousness
7. glioblastoma	_____	H. Paralysis of the lower portion of the body
8. paraplegia	_____	I. Malignant tumor of the brain
9. hemiplegia	_____	J. Chronic brain disorder with seizure activity
10. Alzheimer disease	_____	

E Match the test or procedure in Column I with its description in Column II.

Column I		Column II
1. lumbar puncture	_____	A. Uptake of radioactive material in the brain shows how the brain uses glucose
2. CSF analysis	_____	B. Chemical tests, cell counts, cultures, and smears of fluid surrounding the brain and spinal cord
3. cerebral angiography	_____	C. Record of the electrical activity in the brain
4. electroencephalogram	_____	D. Procedure to remove cerebrospinal fluid; measurement of pressure and injection of contrast
5. PET scan	_____	E. X-ray image of blood vessels in the brain after injection of contrast
6. MRI	_____	F. A battery-powered device delivers stimulation to nerves to relieve acute and chronic pain
7. stereotactic radiosurgery	_____	G. Cross-sectional x-ray images of the brain and spinal cord
8. CT scan	_____	H. Magnetic and radiofrequency waves create images of the brain and spinal cord tissue
9. TENS	_____	I. Nonsurgical type of radiation therapy used to treat abnormalities and small tumors of the brain; also called Cyberknife®

Respiratory System Anatomy



Air enters the **nose** and travels to the **pharynx** (throat). From the pharynx, air passes through the **epiglottis** and **larynx** (voice box) into the **trachea** (windpipe). The trachea splits into two tubes, the **bronchial tubes** that carry air into the lungs. The bronchial tubes divide into smaller tubes, called **bronchioles**, that end in **small alveoli**, or **air sacs**. The thin walls of these sacs allow oxygen to pass through them into tiny capillaries containing red blood cells. Red blood cells transport the oxygen to all parts of the body. In a similar manner, gaseous waste (carbon dioxide) leaves the blood by entering the alveoli and traveling out of the body through bronchioles, bronchial tubes, trachea, larynx, pharynx, and the nose. (Modified from Chabner D-E: *The Language of Medicine*, ed 11, St. Louis, 2017, Elsevier.)

Terminology

Meanings for terminology are found in the *Mini-Dictionary*.

Combining Form	Meaning	Terminology	Meaning
adenoid/o	adenoid	adenoidectomy	
alveol/o	alveoli (air sacs)	alveolar	
bronch/o	bronchial tube	bronchoscopy	

		bronchitis _____
bronchiol/o	bronchiole	bronchiolitis _____
cyan/o	blue	cyanosis _____
epiglott/o	epiglottis	epiglottitis _____
laryng/o	larynx	laryngeal _____
nas/o	nose	nasal _____
rhin/o	nose	rhinorrhea _____
pharyng/o	pharynx	pharyngitis _____
phren/o	diaphragm	phrenic _____
pneumon/o	lung	pneumonectomy _____
pulmon/o	lung	pulmonary _____
tonsill/o	tonsils	tonsillitis _____
trache/o	trachea	tracheitis _____
		tracheostomy _____

Pathology

Definitions for additional terms in **boldface** are found in the *Mini-Dictionary*.

Asphyxia: Deficiency of oxygen in the blood and increase in carbon dioxide in blood and tissues. Major sign is a complete absence of breathing, leading to loss of consciousness or death.

Asthma: Spasm and narrowing of bronchi, leading to bronchial airway obstruction.

Atelectasis: Collapsed lung (ATEL/O means incomplete, and -ECTASIS indicates dilation or expansion).

Emphysema: Hyperinflation of air sacs with destruction of alveolar walls. Along with **chronic bronchitis**, emphysema is a type of **chronic obstructive pulmonary disease (COPD)**.

Hemoptysis: Spitting up of blood.

Hemothorax: Blood from the respiratory tract in the pleural cavity (space between the **pleural membranes**).

Pneumoconiosis: Abnormal condition of dust (CONI/O) in the lungs.

Pneumonia: Abnormal condition of the lungs marked by inflammation and collection of infected material in air sacs (pus or products of the inflammatory reaction).

Tuberculosis: Infectious and inflammatory disease caused by bacteria (bacilli). The lungs and other organs are affected. Signs and symptoms are cough, weight loss, night sweats, **hemoptysis**, and pleuritic pain.

Laboratory Tests and Diagnostic Procedures

Consult [Appendix 2](#) reference for pronunciation of terms and additional information.

Bronchoscopy: Visual examination of the bronchial tubes with an endoscope.

Chest x-ray film: X-ray image of the chest in an AP (anteroposterior), PA (posteroanterior), or lateral (side) view.

Computed tomography (CT) scan: Cross-sectional x-ray images of the chest.

Laryngoscopy: Visual examination of the larynx via the placement of a flexible tube (laryngoscope) through the nose or mouth and into the larynx.

Magnetic resonance imaging (MRI): Magnetic waves and radiofrequency waves create images of the chest in three planes of the body.

Pulmonary angiography: X-ray images are taken of the blood vessels in the lung after injection of

contrast into a blood vessel. This procedure has been largely replaced by computed tomography (CT of the lungs).

Pulmonary function test (PFT): Measurement of the ventilation (breathing capability) of the lungs. A **spirometer** measures the air taken into and breathed out of the lungs.

Sputum test: Examination of mucus coughed up from a patient's lungs to detect infection.

Tuberculin test: Agents are applied to the skin with punctures or injection and the reaction is noted. Redness and swelling result in people sensitive to the test substance and indicate previous or current infection with **tuberculosis**.

Ventilation-perfusion scan: A nuclear medicine test that uses radioactive material (radiopharmaceutical) to examine airflow (ventilation) and blood flow (perfusion) in the lungs.

Treatment Procedures

Endotracheal intubation: Tube is placed through the nose or mouth into the trachea to establish an airway during surgery and for placement on a respirator (a machine that moves air into and out of the lungs).

Thoracentesis: Needle is inserted through the skin between the ribs and into the pleural space to drain a **pleural effusion**.

Thoracotomy: Incision of the chest to remove a lung (**pneumonectomy**) or a portion of a lung (**lobectomy**).

Tracheostomy: Creation of an opening into the trachea through the neck and the insertion of a tube to create an airway.

Abbreviations

ABG	Arterial blood gas
ARDS	Acute respiratory distress syndrome
CO₂	Carbon dioxide (gas expelled from the lungs)
COPD	Chronic obstructive pulmonary disease (chronic bronchitis and emphysema)
CPAP	Continuous positive airway pressure (machine used to keep airway open)
CPR	Cardiopulmonary resuscitation (technique to restore breathing and heart rate)
CXR	Chest x-ray (film or image)
O₂	Oxygen (gas entering the bloodstream through the lungs)
MDI	Metered-dose inhaler (that delivers specific amount of medication to the lungs)
PE	Pulmonary embolism (blockage of vessels in the lung by a blood clot)
PEEP	Positive end-expiratory pressure (method of mechanical ventilation)
PFT	Pulmonary function test (measurement of the breathing capability of the lung)
SOB	Shortness of breath
URI	Upper respiratory infection
VATS	Video-assisted thoracic surgery (using small incisions and an endoscope)
VQ	Ventilation-perfusion scan (also called VQ scan)

Matching Exercises

The following exercises will help you review terminology related to the respiratory system. Answers begin on [page 293](#).

A Match the term in Column I with its description in Column II.

Column I	Column II
1. nose	_____ A. Throat
2. epiglottis	_____ B. Windpipe
3. larynx	_____ C. Muscle that separates the chest from the abdomen
4. pharynx	_____ D. Flap of cartilage over the "mouth" of the trachea
5. lung	_____ E. Small bronchial tube

6. diaphragm	_____	F. Structure on the face that filters/warms air entering the body
7. trachea	_____	G. Thin-walled sac through which gases can pass into and out of the bloodstream
8. bronchial tube	_____	H. One of two tubes that carry air from the windpipe to the lungs
9. bronchiole	_____	I. Voice box
10. air sac	_____	J. One of two paired organs in the chest through which oxygen enters and carbon dioxide leaves the bloodstream

B Match the combining form in Column I with its meaning in Column II.

Column I	Column II	
1. pharyng/o	_____	A. Diaphragm
2. bronch/o	_____	B. Air sac
3. bronchiol/o	_____	C. Windpipe
4. nas/o or rhin/o	_____	D. Nose
5. laryng/o	_____	E. Throat
6. phren/o	_____	F. Voice box
7. trache/o	_____	G. Tube that carries air from the windpipe to the lung
8. epiglott/o	_____	H. Lung
9. alveol/o	_____	I. Small bronchus
10. pneumon/o	_____	J. Epiglottis

C Match the medical term in Column I with its meaning in Column II.

Column I	Column II	
1. pulmonary	_____	A. Discharge from the nose
2. rhinorrhea	_____	B. Pertaining to an air sac
3. pneumonectomy	_____	C. Inflammation of the throat
4. bronchoscopy	_____	D. Pertaining to a lung
5. laryngeal	_____	E. New opening of the windpipe to the outside of the body
6. pharyngitis	_____	F. Pertaining to the nose
7. phrenic	_____	G. Visual examination of the bronchus
8. tracheostomy	_____	H. Resection of a lung
9. alveolar	_____	I. Pertaining to the voice box
10. nasal	_____	J. Pertaining to the diaphragm

D Match the pathologic condition in Column I with its meaning in Column II.

Column I	Column II	
1. atelectasis	_____	A. Collapsed lung
2. hemothorax	_____	B. Condition of dust particles in the lung
3. asphyxia	_____	C. Spitting up blood
4. emphysema	_____	D. Infectious disease caused by bacilli; lungs and other organs are affected
5. asthma	_____	E. Inflammation and infection of alveoli
6. hemoptysis	_____	F. Blood in the pleural space
7. tuberculosis	_____	G. Extreme decrease in oxygen and increase in carbon dioxide in the blood
8. pneumonia	_____	H. Hyperinflation of air sacs and destruction of alveolar walls
9. pneumoconiosis	_____	I. Spasm and narrowing of bronchial tubes leading to airway obstruction

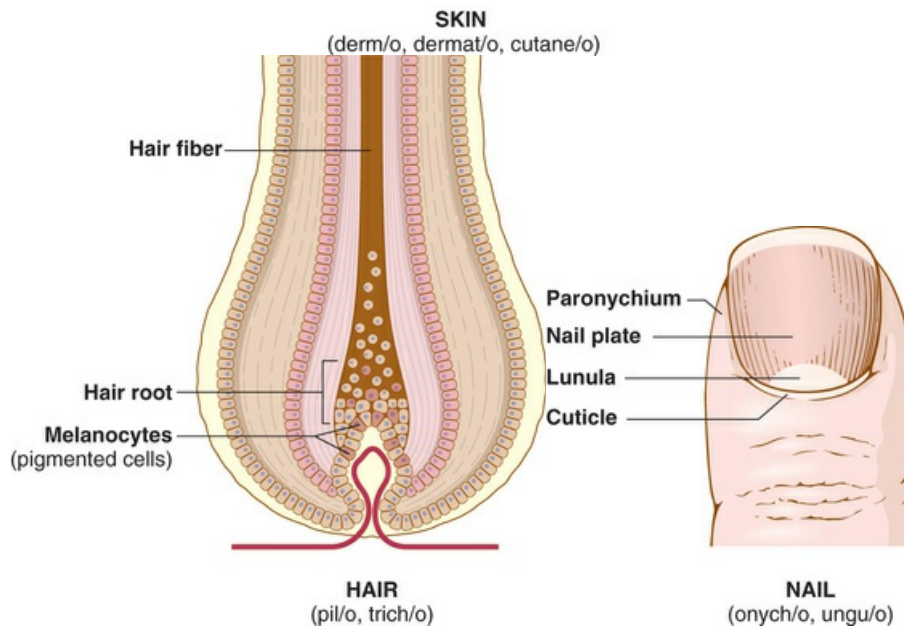
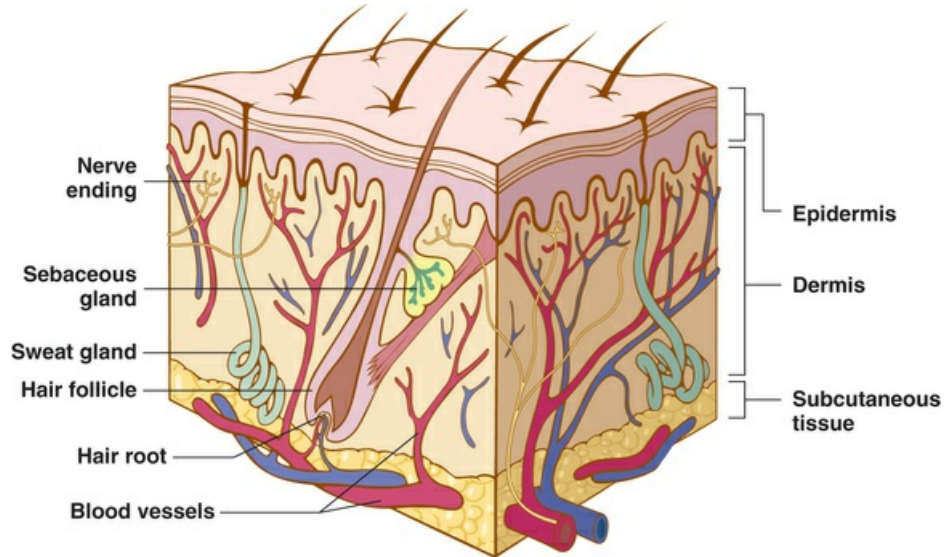
E Match the test or procedure in Column I with its description in Column II.

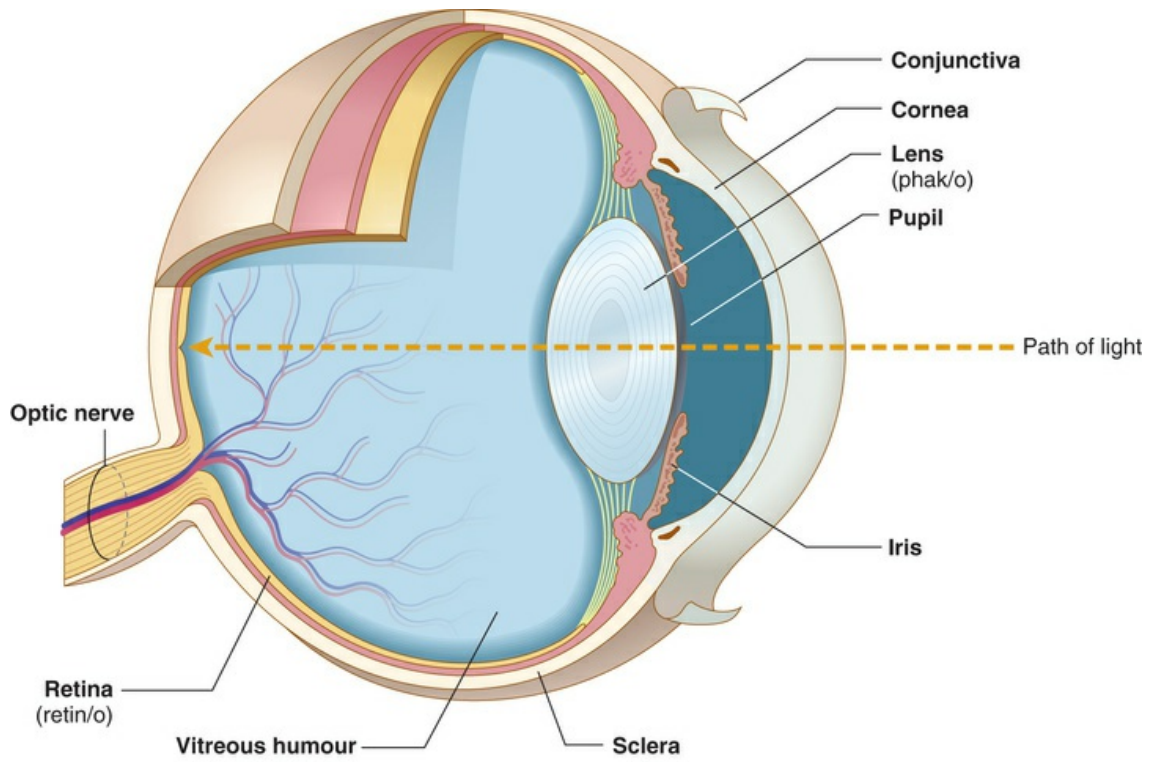
Column I	Column II	
1. pulmonary angiography	_____	A. Radiographic image in AP, PA, or lateral view
2. laryngoscopy	_____	B. Material expelled by coughing is analyzed
3. ventilation-perfusion scans	_____	C. Visual examination of bronchial tubes
4. PFTs	_____	D. After administration of radioactive material (by injection or inhalation), images reveal distribution in lung tissue
5. chest x-ray	_____	E. Magnetic waves produce images of the chest in three planes
6. bronchoscopy	_____	F. Measurements of the ventilation capability of the lung using a spirometer
7. sputum test	_____	G. X-ray images of blood vessels in the lung
8. MRI	_____	H. Visual examination of the voice box
9. tuberculin test	_____	I. Cross-sectional x-ray images of the chest
10. chest CT scan	_____	J. Agents are applied to the skin with punctures, and reaction is noted

F Match the treatment procedure in Column I with its description in Column II.

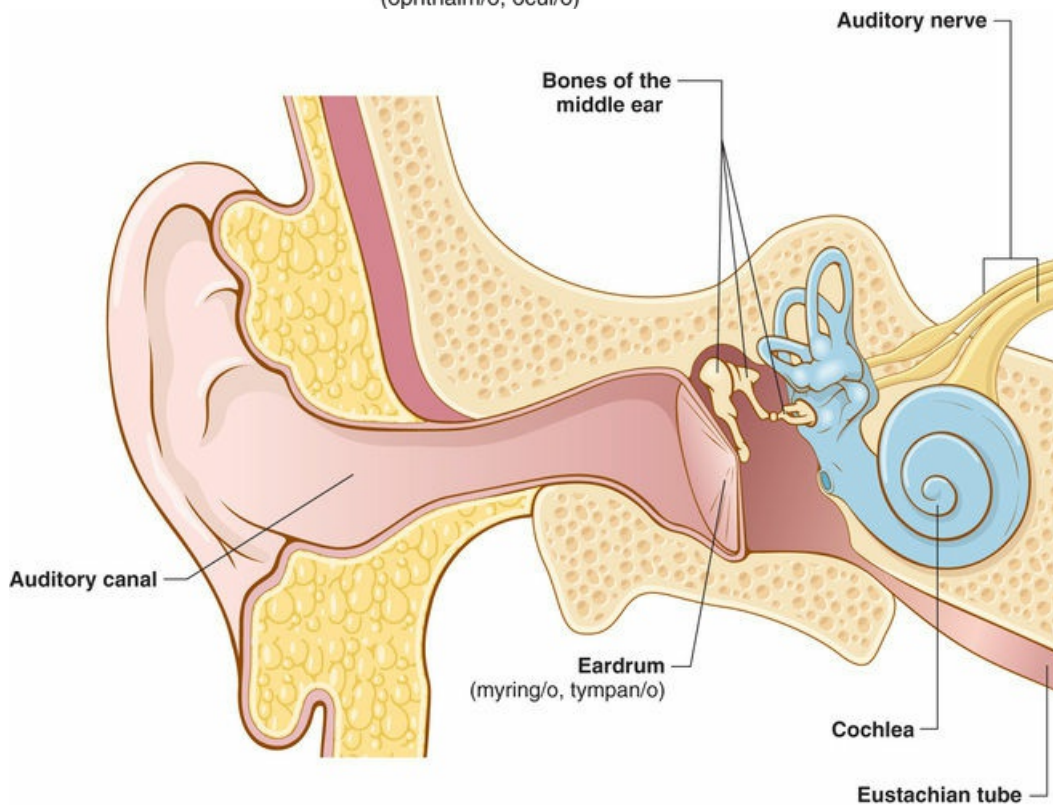
Column I	Column II	
1. tracheostomy	_____	A. A tube is placed through the nose or mouth into the windpipe to establish an airway
2. thoracentesis	_____	B. Creation of an opening into the windpipe through the neck and insertion of a tube to create an airway
3. endotracheal intubation	_____	C. Incision of the chest to remove a lung or a portion of a lung
4. thoracotomy	_____	D. Insertion of a needle through the skin between the ribs and into the pleural space to drain a pleural effusion

Skin and Sense Organs Anatomy






EYE
(ophthalm/o, ocul/o)



EAR
(aur/o, ot/o)



The skin and sense organs receive messages (touch sensations, light waves, sound waves) from the environment and send them to the brain via nerves. These messages are interpreted in the brain, making sight, hearing, and tactile (touch) perception of the environment possible. (Modified from Chabner D-E: *The*

Terminology

Meanings for terminology are found in the *Mini-Dictionary*.

Combining Form	Meaning	Terminology	Meaning
cutane/o	skin	subcutaneous	
derm/o	skin	epidermis	
dermat/o	skin	dermatology	
onych/o	nail	onycholysis	
ungu/o	nail	subungual	
pil/o	hair	pilosebaceous	
trich/o	hair	trichotillomania	
ocul/o	eye	ocular	
ophthalm/o	eye	ophthalmoscope	
phak/o	lens of the eye	aphakia	
retin/o	retina	retinopathy	
aur/o	ear	aural discharge	
ot/o	ear	otitis	
myring/o	eardrum	myringotomy	
tympan/o	eardrum	tympanoplasty	

Pathology

Definitions for additional terms in **boldface** are found in the *Mini-Dictionary*.

Alopecia: Absence of hair from areas where it normally grows; baldness.

Cataract: Clouding (opacity) of the lens of the eye, causing impairment of vision or blindness.

Conjunctivitis: Inflammation of the **conjunctiva**.

Glaucoma: Increase in pressure (fluid accumulation) within the chamber at the front of the eye.

Melanoma: Malignant tumor of pigmented cells (MELAN/O means black) that arises from a nevus (benign mole) in the skin.

Nevus: Pigmented lesion in or on the skin; a mole.

Stye or sty: Pus-filled (purulent) infection of glands near the eyelid (most often caused by bacteria). Also called **hordeolum**.

Tinnitus: Abnormal noise (ringing, buzzing, roaring) sound in the ears.

Laboratory Tests and Diagnostic Procedures

Consult [Appendix 2](#) for pronunciation of terms and additional information.

Allergy test: Procedure in which allergy-causing substances are placed on the skin and a reaction is noted. In the patch test, a patch with a suspected allergen is placed on the skin. The scratch test involves making several scratches and inserting a small amount of allergen in the scratches.

Bacterial and fungal tests: Procedures in which samples from skin lesions are taken to determine the presence of bacterial infection or fungal growth.

Fluorescein angiography: Fluorescein (a contrast substance) is injected intravenously and the movement of blood in the back of the eye is observed by ophthalmoscopy. It is used to detect diabetic or hypertensive retinopathy and also degeneration of the macular (central) area of the retina.

Ophthalmoscopy: Visual examination of the interior of the eye.

Otoscopy: Visual examination of the interior of the ear (to the eardrum).

Skin biopsy: Procedure in which samples of skin lesions are removed and sent to the pathology laboratory for microscopic examination.

Slit-lamp microscopy: Examination of the anterior eye structures (such as the cornea) using an instrument that projects intense light through a narrow opening for optimal visualization.

Tuning fork test: Procedure in which a vibration source (tuning fork) is placed in front of the opening to the ear to test air conduction of sound waves. The tuning fork is also placed on the mastoid bone behind the ear to test bone conduction of sound waves.

Abbreviations

ENT	Ears, nose, throat
HEENT	Head, eyes, ears, nose, throat
PERRLA	Pupils equal, round, reactive to light and accommodation
VA	Visual acuity (clarity of vision)
VF	Visual field

Matching Exercises

The following exercises will help you review terminology related to the skin and sense organs. Answers begin on [page 294](#).

A Match the term in Column I with its description in Column II.

Column I	Column II	
1. epidermis	_____	A. Oil-producing gland in the skin
2. sebaceous gland	_____	B. Gland in the skin that produces a watery, salt-containing fluid
3. dermis	_____	C. Innermost layer of the skin, composed of fatty tissue
4. subcutaneous tissue	_____	D. Middle layer of the skin, containing hair follicles, connective tissue, blood vessels, and glands
5. sweat gland	_____	E. Outer layer of the skin

B Match the term in Column I with its description in Column II.

Column I	Column II	
1. retina	_____	A. White, outer coat of the eyeball
2. conjunctiva	_____	B. Membrane that separates the outer and middle parts of the ear
3. pupil	_____	C. Transparent structure behind the pupil that bends light rays so that they focus on the back of the eye
4. lens	_____	D. Nerve that carries messages from the inner ear to the brain
5. cornea	_____	E. Transparent layer over the front of the eye that bends light so that it is focused on the back of the eye
6. sclera	_____	F. Black center of the eye through which light enters
7. iris	_____	G. Layer of sensitive cells (rods and cones) at the back of the eye
8. eardrum	_____	H. Nerve at the back of the eye that transmits light waves to the brain
9. auditory canal	_____	I. Colored, pigmented portion of the eye
10. auditory nerve	_____	J. Passageway leading into the ear from the outside of the body
11. optic nerve	_____	K. Thin, protective membrane over the front of the eye

C Match the combining form in Column I with its meaning in Column II.

Column I	Column II	
1. derm/o	_____	A. Eye
2. phak/o	_____	B. Hair
3. retin/o	_____	C. Skin
4. myring/o	_____	D. Posterior, sensitive cell layer of the eye
5. aur/o	_____	E. Nail
6. ophthalm/o	_____	F. Eardrum
7. ungu/o	_____	G. Lens of the eye
8. pil/o	_____	H. Ear

D Match the medical term in Column I with its meaning in Column II.

Column I	Column II

1. ocular	_____	A. Disease of the rod and cone layer of eye (sensitive cells at the back of the eye)
2. otitis	_____	B. Pertaining to under the nail
3. subcutaneous	_____	C. Absence of the lens of the eye
4. myringotomy	_____	D. Inflammation of the ear
5. aphakia	_____	E. Pertaining to the eye
6. epidermis	_____	F. Pertaining to under the skin
7. retinopathy	_____	G. Incision of the eardrum
8. ophthalmoscope	_____	H. Outer layer of the skin
9. tympanoplasty	_____	I. Instrument to visually examine the eye
10. subungual	_____	J. Surgical repair of the eardrum

E Match the pathologic condition in Column I with its meaning in Column II.

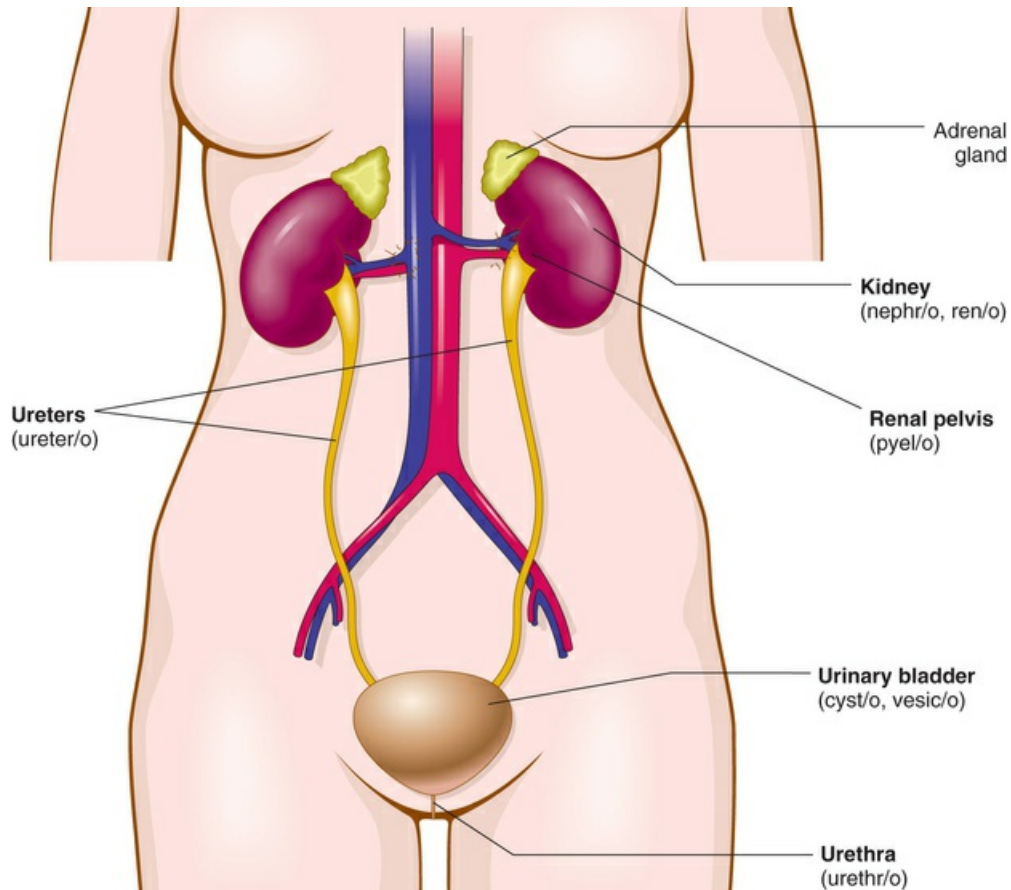
Column I		Column II
1. melanoma	_____	A. Clouding of the lens of the eye, causing impairment of vision
2. glaucoma	_____	B. Absence of hair from areas where it normally grows
3. conjunctivitis	_____	C. Pigmented lesion on the skin; mole
4. tinnitus	_____	D. Increase in pressure within the chamber at the front of the eye
5. cataract	_____	E. Abnormal noise (ringing, buzzing) or sound in the ears
6. nevus	_____	F. Malignant tumor of pigmented cells in the skin
7. alopecia	_____	G. Inflammation of the mucous membrane lining the inner surface of the eyelid

F Match the test or procedure in Column I with its description in Column II.

Column I		Column II
1. skin biopsy	_____	A. Samples from skin lesions are examined to detect presence of microorganisms
2. slit-lamp microscopy	_____	B. Visual examination of the interior of the eye
3. tuning fork tests	_____	C. Patch test; scratch test
4. fluorescein angiography	_____	D. Skin lesions are removed and sent to pathology laboratory for microscopic examination
5. otoscopy	_____	E. Dye is injected intravenously, and movement of blood through blood vessels in the back of the eye is observed with an ophthalmoscope
6. allergy test	_____	F. Visual examination of the ear to the eardrum
7. bacterial and fungal tests	_____	G. Microscopic examination of the anterior eye structures, such as the cornea, under intense light
8. ophthalmoscopy	_____	H. A vibration source is placed in front of the opening of the ear to test air conduction of sound waves

Urinary System

Anatomy (Female Urinary Tract)



Urine is formed as waste materials, such as urea, are filtered from the blood into the tubules of the **kidney**. Urea is a nitrogenous waste product formed as proteins are used in cells. Urine passes from the kidney tubules into the central collecting section of the kidney, the **renal pelvis**. Each renal pelvis leads directly to a **ureter**, which takes the urine to the **urinary bladder**. The bladder releases urine to the **urethra**, and urine leaves the body. (Modified from Chabner D-E: *The Language of Medicine*, ed 11, St. Louis, 2017, Elsevier.)

Terminology

Meanings for terminology are found in the *Mini-Dictionary*.

Combining Form	Meaning	Terminology	Meaning
cyst/o	urinary bladder	cystoscopy	
vesic/o	urinary bladder	intravesical	
nephro/o	kidney	nephritis	
ren/o	kidney	renal	
pyelo/o	renal pelvis	pyelogram	
uretero/o	ureter	ureterectomy	
urethro/o	urethra	urethritis	

Pathology

Definitions for additional terms in **boldface** are found in the *Mini-Dictionary*.

Albuminuria: Abnormal condition of protein (albumin) in the urine.

Anuria: Abnormal condition of no urine production.

Dysuria: Painful urination.

Glycosuria: Abnormal condition of glucose in the urine.

Hematuria: Abnormal condition of blood in the urine.

Nephrolithiasis: Abnormal condition of stones in the kidney.

Renal failure: Condition in which the kidneys stop functioning and do not produce urine.

Uremia: Condition of high levels of **urea** (nitrogenous waste material) in the blood.

Laboratory Tests and Diagnostic Procedures

Consult [Appendix 2](#) for pronunciation of terms and additional information.

Blood urea nitrogen (BUN): Measures the amount of urea (nitrogenous waste) in the blood.

Cystoscopy: Visual examination of the urinary bladder with a cystoscope (endoscope).

Kidneys, ureters, bladder (KUB): X-ray images of the kidneys and urinary tract made without the use of contrast material.

Retrograde pyelogram (RP): Contrast material is injected through a catheter (a flexible, tubular instrument) into the urethra and bladder, and x-ray images are taken of the urethra, bladder, and ureters.

Voiding cystourethrogram (VCUG): X-ray films of the bladder and urethra taken after the bladder is filled with a contrast material and while the patient is expelling urine. Also called **cystogram**.

Urography: X-ray imaging of the urinary tract after injection of contrast material; pyelography.

Treatment Procedures

Dialysis: Waste materials (**urea**, **creatinine**, and **uric acid**) are separated from the blood by a machine (**hemodialysis**). Alternatively, in peritoneal dialysis, an intra-abdominal catheter (a flexible tubular instrument), delivers a special fluid into the abdominal cavity. After several hours, the fluid containing waste materials that have seeped into it from the blood is drained.

Lithotripsy: Shock waves are beamed into a patient to crush urinary tract stones. The stone fragments then pass out of the body with urine. Also called **extracorporeal shock wave lithotripsy (ESWL)**.

Renal transplantation: A donor kidney is transferred to a recipient, whose kidneys have both failed.

Urinary catheterization: A catheter (a flexible tubular instrument) is passed through the urethra and into the urinary bladder for short-term or long-term drainage of urine.

Abbreviations

ARF	Acute renal failure
BUN	Blood urea nitrogen (measures kidney function)
CAPD	Continuous ambulatory peritoneal dialysis
CKD	Chronic kidney disease (rising BUN and serum creatinine levels affect many body systems)
GFR	Glomerular filtration rate (measured to document stages of kidney disease)
HD	Hemodialysis
KUB	Kidneys, ureters, bladder (series of x-ray images made without contrast)
RP	Retrograde pyelogram

UA	Urinalysis
UTI	Urinary tract infection
VCUG	Voiding cystourethrogram

Matching Exercises

The following exercises will help you review terminology related to the urinary system. Answers begin on [page 294](#).

A Match the term in Column I with its description in Column II.

Column I	Column II
1. urinary bladder	A. Tube that leads from the bladder to the outside of the body
2. kidney	B. Central section of the kidney
3. renal pelvis	C. Organ behind the abdomen that makes urine by filtering wastes from the blood
4. ureter	D. One of two tubes that carry urine from the kidney to the urinary bladder
5. urethra	E. Muscular sac that holds urine and releases it to leave the body through the urethra

B Match the combining form in Column I with its meaning in Column II.

Column I	Column II
1. ureter/o	A. Urinary bladder
2. urethr/o	B. Tube leading from the urinary bladder to the outside of the body
3. pyel/o	C. Kidney
4. cyst/o, vesic/o	D. Tube leading from the kidney to the urinary bladder
5. nephr/o, ren/o	E. Renal pelvis (central collecting basin of the kidney)

C Match the medical term in Column I with its meaning in Column II.

Column I	Column II
1. pyelogram	A. X-ray record of the renal pelvis
2. urethritis	B. Visual examination of the urinary bladder
3. nephritis	C. Resection of a ureter
4. intravesical	D. Pertaining to within the urinary bladder
5. cystoscopy	E. Inflammation of the kidney
6. ureterectomy	F. Pertaining to the kidney
7. renal	G. Inflammation of the urethra

D Match the pathologic condition in Column I with its meaning in Column II.

Column I	Column II
1. dysuria	A. Kidneys stop functioning and fail to produce urine
2. hematuria	B. Abnormal condition of protein in urine
3. uremia	C. Blood in the urine
4. renal failure	D. No urine production
5. nephrolithiasis	E. High levels of urea in the bloodstream
6. albuminuria	F. Sugar in the urine
7. glycosuria	G. Painful urination
8. anuria	H. Abnormal condition of kidney stones

E Match the test or procedure in Column I with its description in Column II.

Column I	Column II
1. KUB	A. Measurement of amount of nitrogenous wastes in the blood
2. dialysis	B. Visual examination of the urinary bladder
3. VCUG	C. X-ray images of the kidneys and urinary tract without contrast
4. lithotripsy	D. Tube is passed through the urethra into the urinary bladder for short- or long-term drainage of urine
5. renal transplantation	E. Shock waves are beamed into the patient to crush stones in the kidney or ureter
6. cystoscopy	F. Nitrogenous waste materials are separated from the blood by a machine
7. BUN	G. After the bladder is filled with contrast, x-ray images are taken of the bladder as the patient is expelling urine
8. retrograde pyelogram	H. Contrast material is injected via a catheter into the bladder, and x-ray images are taken of the ureters, bladder, and urethra
9. urinary catheterization	I. A kidney from a donor is surgically implanted in a patient whose kidneys have failed

Answers to Matching Exercises

Cardiovascular System

A

1. B
2. I
3. F
4. E
5. D
6. A
7. J
8. G
9. C
10. H

B

1. D
2. E
3. B
4. F
5. A
6. C

C

1. D
2. F
3. G
4. C
5. H
6. E
7. A
9. J
8. B
10. I

D

1. E

2. H

3. D

4. G

5. C

6. A

7. F

8. B

E

1. I

2. J

3. C

4. G

5. B

6. E

7. D

8. A

9. H

10. F

F

1. E

2. B

3. G

4. F

5. A

6. C

7. D

Digestive System

A

1. G

2. C

3. H

4. A

5. F

6. D

7. B

8. E

B

1. C

2. H

3. A

4. F

5. D

6. B

7. G

8. E

C

1. D

2. G

3. H

4. I

5. J

6. A

7. E

8. F

9. C

10. B

D

1. C

2. F

3. G

4. H

5. D

6. I

7. J

8. E

9. A

10. B

E

1. D

2. F

3. E

4. G

5. A

6. C

7. B

8. I

9. J

10. H

F

1. G

2. I

3. A

4. D

5. C

6. H

7. J

8. F

9. E

10. B

Endocrine System

A

1. C

2. G

3. A

4. F

5. B

6. E

7. D

B

1. E

2. D

3. F

4. G

5. C

6. B

7. A

C

1. C

2. G

3. E

4. F

5. D

6. A

7. B

D

1. C

2. D

3. A

4. B

5. E

E

1. B

2. E

3. A

4. G

5. F

6. C

7. D

Female Reproductive System

A

1. C

2. B

3. D

4. A

5. F

6. E

B

1. D

2. E

3. B

4. A

5. C

6. F

C

1. D

2. F

3. H

4. A

5. G

6. B

7. E

8. C

D

1. C

2. E

3. D

4. G

5. A

6. F

7. B

E

1. H

2. F

3. C

4. A

5. D

6. G

7. E

8. B

9. I

F

1. C

2. A

3. E

4. B

5. D

Lymphatic System

A

1. C

2. B

3. D

4. A

5. E

B

1. C

2. D

3. E

4. A

5. B

C

1. G

2. D

3. E

4. A

5. F

6. B

7. C

D

1. D

2. C

3. E

4. B

5. A

Male Reproductive System

A

1. C

2. B

3. D

4. A

5. E

B

1. B

2. E

3. D

4. F

5. C

6. A

C

1. D

2. E

3. F

4. C

5. A

6. G

7. B

D

1. E

2. F

3. C

4. D

5. B

6. A

E

1. E

2. F

3. D

4. C

5. A

6. B

Musculoskeletal System

A

1. H

2. E

3. K

4. D

5. J

6. R

- 7. Q
- 8. A
- 9. T
- 10. G
- 11. I
- 12. S
- 13. L
- 14. P
- 15. C
- 16. N
- 17. F
- 18. M
- 19. B
- 20. O

B

- 1. D
- 2. C
- 3. H
- 4. E
- 5. G
- 6. F
- 7. I
- 8. B
- 9. A
- 10. J

C

- 1. G
- 2. E
- 3. D
- 4. I
- 5. B

6. F

7. C

8. H

9. A

D

1. C

2. B

3. E

4. F

5. A

6. D

E

1. E

2. G

3. A

4. F

5. B

6. C

7. D

8. I

9. J

10. H

F

1. D

2. C

3. A

4. B

Nervous System

A

1. C

2. B

3. E

4. A

5. D

B

1. B

2. E

3. D

4. F

5. C

6. A

C

1. D

2. B

3. F

4. E

5. A

6. C

D

1. E

2. F

3. G

4. C

5. J

6. A

7. I

8. H

9. D

10. B

E

1. D

2. B

3. E

4. C

5. A

6. H

7. I

8. G

9. F

Respiratory System

A

1. F

2. D

3. I

4. A

5. J

6. C

7. B

8. H

9. E

10. G

B

1. E

2. G

3. I

4. D

5. F

6. A

7. C

8. J

9. B

10. H

C

1. D

2. A

3. H

4. G

5. I

6. C

7. J

8. E

9. B

10. F

D

1. A

2. F

3. G

4. H

5. I

6. C

7. D

8. E

9. B

E

1. G

2. H

3. D

4. F

5. A

6. C

7. B

8. E

9. J

10. I

F

1. B
2. D
3. A
4. C

Skin and Sense Organs

A

1. E
2. A
3. D
4. C
5. B

B

1. G
2. K
3. F
4. C
5. E
6. A
7. I
8. B
9. J
10. D
11. H

C

1. C
2. G
3. D
4. F
5. H
6. A

7. E

8. B

D

1. E

2. D

3. F

4. G

5. C

6. H

7. A

8. I

9. J

10. B

E

1. F

2. D

3. G

4. E

5. A

6. C

7. B

F

1. D

2. G

3. H

4. E

5. F

6. C

7. A

8. B

Urinary System

A

- 1. E
- 2. C
- 3. B
- 4. D
- 5. A

B

- 1. D
- 2. B
- 3. E
- 4. A
- 5. C

C

- 1. A
- 2. G
- 3. E
- 4. D
- 5. B
- 6. C
- 7. F

D

- 1. G
- 2. C
- 3. E
- 4. A
- 5. H
- 6. B
- 7. F
- 8. D

E

- 1. C

2. F

3. G

4. E

5. I

6. B

7. A

8. H

9. D



APPENDIX 2

Diagnostic Tests and Procedures

This resource contains a color-coded list of common diagnostic tests and procedures. Below is information related to the types of tests/procedures.

- **Radiology, Ultrasound, and Imaging Procedures**

In many procedures, a *contrast* substance (sometimes referred to as a *dye*) is introduced into the bloodstream, the gastrointestinal tract, or spinal cord so that a body part can be viewed while x-ray pictures are taken. The contrast substance (often containing barium or iodine) blocks the transmission of the x-ray and appears dense on the x-ray image. It outlines the body part that it fills.

The suffix -GRAPHY, meaning process of recording, is used in many terms describing imaging procedures. The suffix -GRAM, meaning a record, also is used and describes the actual image that is produced by this procedure.

- **Nuclear Medicine: Radionuclide Scans**

In these diagnostic tests, radioactive material (*radionuclide* or *radioisotope*) is injected intravenously or inhaled and then detected with a scanning device in the organ in which it accumulates. X-rays, ultrasound waves, or magnetic waves are not used.

- **Clinical Procedures**

These procedures are performed on patients to establish a correct diagnosis of an abnormal condition. In some instances, the procedure also may be used to treat the condition.

- **Laboratory Tests**

These tests are performed on samples of a patient's blood, *plasma* (fluid portion of the blood), *serum* (plasma minus clotting proteins and produced after blood has clotted), urine, feces, *sputum* (mucus coughed up from the lungs), *cerebrospinal fluid* (fluid within the spaces around the spinal cord and brain), and skin.

In the pronunciation of each term, the syllable that gets the accent is in CAPITAL LETTERS.

Italicized terms indicate important additional terminology.

Terms in SMALL CAPITAL LETTERS are defined elsewhere in this section.

Definitions of medical terms in this section are also on the Student Evolve Resource.

A

Abdominocentesis (ab-dom-in-o-sen-TE-sis): See PARACENTESIS.

Acid phosphatase test (AH-sid FOS-fah-tays): Measurement of the amount of an enzyme called *acid phosphatase* in serum. Enzyme levels are elevated in metastatic prostate cancer. Moderate elevations occur in bone disease and metastatic breast cancer.

Alanine transaminase (ALT) test (AL-ah-noon tranz-AM-ih-nays): Measurement of the amount of the enzyme called *alanine transaminase* in serum. The enzyme is normally present in blood but accumulates in blood with damage to liver cells. Formerly called SGPT.

Albumin test (al-BU-min): Measurement of the amount of albumin (a large protein found in blood and tissues) in both serum and urine. A decreased albumin level in serum indicates malnutrition or liver disease or may occur with extensive loss of protein in the urine or intestines, or from the skin, as in a burn. The presence of albumin in the urine (*albuminuria*) indicates malfunction of the kidney.

Alkaline phosphatase test (AL-kah-lin FOS-fah-tase): Measurement of the amount of *alkaline phosphatase* (an enzyme found in cells) in serum. Levels are elevated in liver diseases (such as hepatitis and hepatoma) and in bone disease and cancer metastatic to bone or liver. On laboratory reports, usually abbreviated as *alk phos* or *ALK PHOS*.

Allergy test (AL-er-je test): A small quantity of suspected allergic substance is applied to the skin or injected under the skin, and any reaction is noted.

Alpha-fetoprotein test (al-fah-fe-to-PRO-teen): Determination of the presence of a protein called alpha-fetoprotein in serum. The protein normally is present in the serum of the fetus, infant, and pregnant woman. In fetuses with abnormalities of the brain and spinal cord, the protein leaks into the amniotic fluid surrounding the fetus, so it is an indicator of a spinal tube defect (spina bifida) or anencephaly (lack of brain development). High levels are found in patients with cancer of the liver and other malignant diseases (testicular and ovarian cancers). Serum levels monitor the effectiveness of cancer treatment. Elevated levels are also seen in benign liver diseases such as cirrhosis and viral hepatitis. On laboratory reports, usually abbreviated *AFP*.

Amniocentesis (am-ne-o-sen-TE-sis): Surgical puncture to remove fluid from the sac (amnion) that surrounds the fetus in the uterus. The fluid contains cells from the fetus that can be examined with a microscope for chromosomal analysis. Levels of chemicals in amniotic fluid also can detect defects in the fetus.

ANA test: See ANTINUCLEAR ANTIBODY TEST.

Angiography (an-je-OG-rah-fe) or **angiogram** (AN-je-o-gram): X-ray imaging of blood vessels. A contrast substance is injected into a blood vessel (vein or artery), and x-ray images are taken of the vessel. In *cerebral angiography*, x-ray images show blood vessels in the brain. In *coronary angiography*, x-rays detect abnormalities in vessels that bring blood to the heart. Angiograms can detect blockage by clots, cholesterol plaques, tumors, or aneurysms (ballooning or dilating of the vessel wall). Angiography is performed frequently to view arteries and is often used interchangeably with *arteriography*. It is also used to view veins (*venography*), to detect blood clots or pulmonary emboli.

Antinuclear antibody test (an-tih-NU-kle-ar AN-tih-bod-e test): A sample of plasma is tested for the presence of antibodies that are found in patients with systemic lupus erythematosus. On laboratory reports, usually abbreviated *ANA*.

Arteriography (ar-teer-e-OG-rah-fe) or **arteriogram** (ar-TEER-e-oh-gram): X-ray recording of an artery and its branches after injection of a contrast substance into an artery. *Coronary arteriography* is the visualization of arteries that travel across the outer surface of the heart and bring blood to the heart muscle.

Arthrocentesis (ar-thro-sen-TE-sis): Puncture to remove fluid from a joint. This usually is done through the skin with a *percutaneous* needle.

Arthrography (arth-ROG-rah-fe): X-ray examination of the inside of a joint with a contrast medium.

Aspartate transaminase (AST) test: Measurement of the enzyme *aspartate transaminase* in serum. The enzyme normally is present in blood but accumulates when there is damage to the heart or to liver cells. Formerly called *SGOT*.

Aspiration (as-pih-RA-shun): Withdrawal of fluid from a cavity or sac by suction through a needle or tube. The term *aspiration pneumonia* refers to an infection caused by inhalation of food or an object into the lungs.

Audiometry (aw-de-OM-eh-tre): Test using sound waves of various frequencies (e.g., 500 Hz), up to 8000 Hz, to quantify the extent and type of hearing loss. An *audiogram* is the record produced by this test.

Auscultation (aw-skul-TA-shun): Process of listening for sounds produced within the body. This is most often performed with the aid of a stethoscope to determine the condition of the heart and lungs and blood vessels or to detect the fetal heartbeat.

B

Bacterial and fungal tests (bak-TER-e-al and FUNG-al tests): Samples from skin lesions or other sites (e.g., blood, bone marrow, sputum) are cultured in a laboratory or analyzed microscopically to diagnose bacterial or fungal conditions.

Barium enema: See LOWER GASTROINTESTINAL EXAMINATION and BARIUM TESTS.

Barium swallow: See ESOPHAGOGRAPHY, BARIUM TESTS, and UPPER GASTROINTESTINAL EXAMINATION.

■ Radiology, Ultrasound, and Imaging Procedures
■ Nuclear Medicine—Radionuclide Scans

■ Clinical Procedures
■ Laboratory Tests

Barium tests (BAH-re-um tests): X-ray examinations with a liquid barium mixture that is swallowed or given by enema to outline the surface of the gastrointestinal tract. These studies may locate disorders in the esophagus (*esophagogram*), duodenum, small intestine (*small bowel follow-through*), or colon (*barium enema*). Taken before or during the examination, barium causes the intestinal tract to stand out in silhouette when viewed through a *fluoroscope* (see FLUOROSCOPY) or seen on an x-ray image. The *barium swallow* is used to examine the upper gastrointestinal tract, and the *barium enema* is for examination of the lower gastrointestinal tract. These tests are complemented by ENDOSCOPY (see page 304).

Bence Jones protein test (bens jonz PRO-teen): Measurement of the Bence Jones protein in serum or urine. Bence Jones protein is a fragment of a normal serum protein, an immunoglobulin, produced in greatly excessive amounts by cancerous bone marrow cells (myeloma cells). Normally it is not found in either blood or urine, but in *multiple myeloma* (a malignant condition of bone marrow), high levels of Bence Jones protein may be detected in urine.

Bilirubin test (bil-ih-RU-bin): Measurement of the amount of bilirubin, an orange-brown pigment, in serum and urine. Bilirubin is derived from breakdown of hemoglobin, the oxygen-carrying protein in red blood cells. Its presence in high concentration in serum and urine causes *jaundice* (yellow coloration of the skin) and may indicate disease of the liver, obstruction of bile ducts, or a type of anemia due to excessive destruction of red blood cells.

Biopsy (BI-op-se): Removal of a piece of tissue from the body for subsequent examination under a microscope. The procedure is performed with a surgical knife or by needle aspiration, or *core biopsy*, or via an endoscopic approach (using a special forceps-like instrument inserted through a hollow flexible tube.) *Excisional biopsy* means that the entire tissue to be examined is removed. An *incisional biopsy* is the removal of only a small amount of tissue, and a *needle or core biopsy* indicates that tissue is pierced with a hollow needle and fluid and/or cells are withdrawn by aspiration for microscopic examination.

Blood chemistry profile: A comprehensive blood test that is a biochemical examination of various substances in the blood using a computerized laboratory analyzer. Tests include measurements of albumin (liver and kidney), alkaline phosphatase (liver and bone), AST (liver and heart muscle) and ALT (liver), bilirubin (liver), calcium (bones), creatinine (kidney), electrolytes (acid-base balance), globulin (liver and immune disorders), lipids (such as cholesterol and triglycerides), phosphorus (bones), and urea (kidney). Also called *sequential multiple analysis* (SMA). SMA-6, SMA-12, and SMA-18 indicate the number of blood tests performed.

Blood culture (blud KUL-chur): Test to determine whether infection is present in the bloodstream. A sample of blood is added to a special medium (food) that promotes the growth of microorganisms. The medium is then examined by a medical technologist for evidence of bacteria or other microbes.

Blood Differential test (blud dih-fer-EN-shul): See WHITE BLOOD CELL (WBC) COUNT.

Blood urea nitrogen (BUN) test (blud u-RE-ah NI-tro-jen): Measurement of the amount of urea (nitrogen-containing waste material) in serum. A high level of serum urea indicates poor kidney function because it is the kidney's job to remove

urea from the bloodstream and filter it into urine. On laboratory reports, usually abbreviated *BUN*. Urea is a product of the breakdown of proteins.

Bone density test (bone DEN-sih-te test): Low-energy x-rays are used for this study, which measures bone thickness and reveals areas of bone deficiency (*osteopenia*) and *osteoporosis* (bones become thinner, more fragile, and likely to break). This study is most often performed on the lower spine or hips. Also called *bone densitometry* or *DEXA* (dual-energy x-ray absorptiometry).

Bone marrow biopsy (bone MAH-ro BI-op-se): Removal of a small amount of bone marrow via a needle biopsy. The cells are then examined with a microscope. The liquid content of the marrow cavity is withdrawn by *aspiration* and examined separately from the rest of the biopsy sample. Often the hip bone (iliac crest) is used, and the biopsy is helpful in determining the number and type of blood cells in the bone marrow.

Bone scan: A radioactive substance (usually a *TECHNETIUM* isotope) is injected intravenously, and its uptake in bones is detected with a scanning device. Tumors in bone can be detected by increased uptake of the radioactive material in the areas of the lesions.

Brain scan: A radioactive substance is injected intravenously. It collects in any lesion that disturbs the natural barrier that exists between blood vessels and normal brain tissue (blood–brain barrier), allowing the radioactive substance to enter the brain tissue. A scanning device detects the presence of the radioactive substance and thus can identify an area of tumor, abscess, or hematoma. This procedure has largely been replaced by *COMPUTED TOMOGRAPHY* or *MAGNETIC RESONANCE IMAGING*.

Bronchoscopy (brong-KOS-ko-pe): Visual examination of the bronchial passages through a flexible tube (endoscope) inserted into the airway. The lining of the bronchial tubes can be seen, and tissue may be removed for biopsy. The tube is usually inserted through the mouth or nose but can also be directly inserted into the airway during *mediastinoscopy*. Sedation is required for this procedure.

C

CA-125 test: Blood test measuring CA-125, a protein released into the bloodstream by ovarian cancer cells. Measurement of CA-125 determines response to treatment.

Calcium test (KAL-se-um): Measurement of the amount of calcium in serum, plasma, or whole blood. Low blood levels cause abnormal functioning of nerves and muscles, and high blood levels may be due to loss of calcium from bones, excessive intake of calcium, disease of the parathyroid glands, or cancer. On laboratory reports, usually given as the symbol *Ca*.

Carbon dioxide test (KAR-bon di-OK-side): Blood test that measures all forms of carbon dioxide (gas produced by cells and eliminated by the lungs) in blood. On laboratory reports, abbreviated *CO₂*.

■ Radiology, Ultrasound, and Imaging Procedures
■ Nuclear Medicine—Radionuclide Scans

■ Clinical Procedures
■ Laboratory Tests

- Carcinoembryonic antigen test** (kar-sih-no-em-bree-ON-ik AN-ti-jen): A plasma test for a protein normally found in the blood of human fetuses and produced in healthy adults in only a very small amount. High levels of this antigen may be a sign of one of a variety of cancers, especially colon or pancreatic cancer. This test monitors the response of patients to cancer treatment. On laboratory reports, usually abbreviated *CEA*.
- Cardiac catheterization** (KAR-de-ak kath-eh-ter-ih-ZA-shun): Procedure in which a catheter (tube) is passed via vein or artery into the chambers of the heart to measure the blood flow out of the heart and the pressures and oxygen content in the heart chambers. Contrast material is also introduced into heart chambers, and x-ray pictures are taken to show heart and heart valve structure.
- Cardiac enzyme tests** (CAR-dee-ak EN-zym tests): Measurements of enzymes released into the bloodstream after a heart attack. Examples are creatine kinase (CK) and troponin I and troponin T.
- Catheterization** (kath-eh-ter-ih-ZA-shun): Introduction of a hollow, flexible tube into a vessel or cavity of the body to withdraw or instill fluids. Catheterization also is used to measure pressure in vessels and to inject contrast material for outlining vessels or heart chambers. Male and female *Foley catheters* are used for urinary catheterization. *Cardiac catheterization* involves insertion of a catheter into a large vein or artery; from there, it is threaded through the circulation system to the heart. Contrast can be administered to visualize blood vessels for diagnosis and treatment procedures.
- Cerebral angiography**: See ANGIOGRAPHY.
- Cerebrospinal fluid (CSF) analysis** (seh-re-bro-SPI-nal FLU-id a-NAL-i-sis): Measurement of cerebrospinal fluid for pressure, protein and sugar content, blood cells, and malignant cells. The fluid also is cultured to detect microorganisms. Chemical tests are performed on specimens of the fluid removed by *lumbar puncture*. Abnormal conditions such as meningitis, tumor involving the spinal canal, and encephalitis are detected by analysis of the spinal fluid. On laboratory reports, usually abbreviated *CSF*.
- Chest x-ray**: An x-ray image of the chest wall, lungs, and heart. It may show infection (as in pneumonia or tuberculosis), emphysema, damage due to occupational exposure (asbestosis), lung tumors, fluid accumulation (PLEURAL EFFUSION), or heart enlargement. Also called *chest film* (or *chest x-ray film*) and *chest radiograph*.
- Cholangiography** (ko-lan-je-OG-rah-fe) or **cholangiogram** (ko-LAN-je-o-gram): X-ray recording or record of bile ducts. Contrast material is given by intravenous injection (*IV cholangiogram*) and collects in the gallbladder and bile ducts. Also, contrast can be introduced (through the skin) using a percutaneously placed needle inserted into an intrahepatic duct (*percutaneous transhepatic cholangiography*). X-ray images of bile ducts are obtained to identify obstructions caused by tumors or stones. This procedure has largely been replaced by COMPUTED TOMOGRAPHY and MAGNETIC RESONANCE IMAGING, and by ULTRASONOGRAPHY for stones.
- Cholesterol tests** (ko-LES-ter-ol): Measurement of the amount of cholesterol (substance found in animal fats and oils, egg yolks, and milk and produced by the

liver) in serum. Normal values for adults are 120 to 200 mg/dL. Levels above 200 mg/dL indicate a need for further testing and efforts to reduce cholesterol level, because high levels are associated with blockage of arteries and heart disease. Blood also is tested for the presence of a lipoprotein substance that is a combination of cholesterol and protein. High levels (optimal level is 60 to 100 mg/dL) of high-density lipoprotein (*HDL*) cholesterol in the blood are beneficial because HDL cholesterol promotes the removal and excretion of excess cholesterol from the blood serum, whereas high levels of low-density lipoprotein (*LDL*) are associated with the development of atherosclerosis (optimal level is 100 mg/dL or less). The ratio of HDL to LDL is most important.

Chorionic villus sampling (kor-e-ON-ik VIL-us SAM-pling): Removal of a small piece of placental tissue for microscopic or genetic analysis to detect fetal abnormalities.

Colonoscopy (ko-lon-OS-ko-pe): Visual examination of the colon using a flexible tube (endoscope) inserted through the rectum and passed into the large bowel. Biopsy samples may be taken and benign growths, such as polyps, removed through the endoscope. The removal of a polyp is a *polypectomy* (pol-ih-PEK-to-me).

Colposcopy (kol-POS-ko-pe): Visual examination of the vagina and cervix through a special microscope inserted into the vagina. The vaginal walls are held apart with a speculum so that all tissues can be viewed.

Complete blood count (CBC): Determination of the numbers of leukocytes (white blood cells), erythrocytes (red blood cells), and platelets (clotting cells). The CBC is useful in diagnosis of anemia, infection, and blood cell disorders, such as leukemia.

Computed tomography (kom-PU-ted to-MOG-rah-fe) or **CT** and **CT scan**: X-ray examination that shows images of the body in cross-section. Contrast material may be used (injected into the bloodstream) to highlight structures such as the liver, brain, or blood vessels, and barium can be swallowed to outline gastrointestinal organs. X-ray images, obtained as the x-ray tube rotates (helical CT) around the body, are processed by a computer to show “slices” of body tissues, most often within the head, chest, and abdomen.

Conization (ko-nih-ZA-shun): Removal of a cone-shaped sample of uterine cervix tissue. This sample is then examined with a microscope for evidence of cancerous growth. The special shape of the tissue sample allows the pathologist to examine the transitional zone of the cervix, where cancers are most likely to develop.

Coronary arteriography: See ARTERIOGRAPHY.

Creatine kinase test (KRE-ah-tin KI-nas): Measurement of levels of creatine kinase, a blood enzyme. Creatine kinase (*CK*) is normally found in heart muscle, brain tissue, and skeletal muscle. The presence of one form (*isoenzyme*) of creatine kinase (either CK-MB or CK2) in the blood is strongly indicative of recent myocardial infarction (heart attack) because the enzyme is released from heart muscle when the muscle is damaged or dying.

■ Radiology, Ultrasound, and Imaging Procedures
■ Nuclear Medicine—Radionuclide Scans

■ Clinical Procedures
■ Laboratory Tests

Creatinine test (kre-AT-tih-noon): Measurement of the amount of creatinine, a nitrogen-containing waste material, in serum or plasma. It is the most commonly used test for kidney function. Because creatinine normally is produced as a protein breakdown product in muscle and is excreted by the kidney in urine, an elevation in the creatinine level in the blood indicates abnormal kidney function. Elevations also are seen in patients on high-protein diets and with dehydration.

Creatinine clearance test (kre-AT-tih-noon KLEER-ans): Measurement of the rate at which creatinine is cleared (filtered) by the kidneys from the blood. A low creatinine clearance indicates that the kidneys are not functioning effectively to clear creatinine from the bloodstream and filter it into urine.

Culdocentesis (kul-do-sen-TE-sis): Surgical puncture to remove fluid from the cul-de-sac (the space between the rectum and the uterus) through a thin, hollow needle inserted through the vagina into this space. The fluid is then analyzed for evidence of cancerous cells, infection, or blood cells.

Culture (KUL-chur): Test in which a sample of body fluids (such as urine, blood, sputum) is mixed with or applied to a sterile growth medium, and if present, bacteria, fungi, or viruses are allowed to grow for several days. Microorganisms that grow out are then identified. In *sensitivity* testing, culture plates containing a specific microorganism are prepared and antibiotic-containing disks are applied to the culture surface. After overnight incubation, the area surrounding the disk (where growth was inhibited) is measured to determine whether the antibiotic is effective against the specific organism. Stool samples may also be cultured.

Cystography (sis-TOG-rah-fe) or **cystogram** (SIS-to-gram): X-ray recording of the urinary bladder with a contrast medium so that the outline of the urinary bladder can be seen clearly. A contrast substance is injected via catheter into the urethra and urinary bladder, and x-ray images are made. A *voiding cystourethrogram* is an x-ray image of the urinary tract made while the patient is urinating.

Cystoscopy (sis-TOS-ko-pe): Visual examination of the urinary bladder through a thin tube or cystoscope (endoscope) inserted into the urethra and then passed into the bladder. This procedure is used to visualize inflammation and tumors of the bladder, to remove stones, and to perform a biopsy of suspicious areas.

D

Digital rectal examination or **DRE** (DIJ-ih-tal REK-tal eks-am-ih-NA-shun): The physician inserts a gloved finger into the patient's rectum to detect rectal cancer and as a primary method to detect prostate cancer. Stool on the removed glove is tested for occult blood, a possible sign of disease.

Digital subtraction angiography (DIJ-ih-tal sub-TRAK-shun an-je-OG-rah-fe): A unique x-ray technique for viewing blood vessels by taking two images and subtracting one from the other. Images are first obtained without contrast material and then again after contrast is injected into blood vessels. The first image is then subtracted from the second so that the final image (sharp and precise) shows only contrast-filled blood vessels and not the surrounding tissue.

Dilation and curettage or **D&C** (di-LA-shun and kur-eh-TAJ): A series of probes of increasing size are systematically inserted through the vagina into the opening of

the cervix. The cervix is thus dilated (widened) so that a curette (spoon-shaped instrument) can be inserted to remove tissue from the lining of the uterus. The tissue is then examined with a microscope.

Doppler ultrasound (DOP-ler UL-trah-sownd): Technique that focuses sound waves on blood vessels and measures blood flow as echoes bounce off red blood cells. Arteries or veins in the arms, neck, legs, or abdomen are examined to detect vessels that are occluded (blocked) by clots or atherosclerosis.

E

Echocardiography (eh-ko-kar-de-OG-rah-fe) or **echocardiogram** (eh-ko-KAR-de-ogram): Imaging of the heart by introducing high-frequency sound waves through the chest into the heart. The sound waves are reflected back from the heart, and echoes showing heart structure are displayed on a recording machine. It is a highly useful diagnostic tool in the evaluation of diseases of the valves that separate the heart chambers and diseases of the heart muscle.

Electrocardiography or **ECG/EKG** (e-lek-tro-kar-de-OG-rah-fe): Connection of electrodes (wires or “leads”) to the body to record electrical impulses from the heart. The *electrocardiogram* is the actual record produced. This test is useful in discovering abnormalities in heart rhythms and for diagnosing heart disorders.

Electroencephalography or **EEG** (e-lek-tro-en-sef-ah-LOG-rah-fe): Connection of electrodes (wires or “leads”) to the scalp to record electricity coming from within the brain. The *electroencephalogram* is the actual record produced. This test is useful in the diagnosis and monitoring of epilepsy and in the investigation of neurologic disorders. It also is used to evaluate patients in coma (brain inactivity) and in the study of sleep disorders.

Electrolyte panel (e-LEK-tro-lyt PAH-nul): Determination of the concentrations of *electrolytes* (chemical substances capable of conducting an electric current) in serum or whole blood. When dissolved in water, salts, such as sodium chloride, break apart into charged particles (*ions*). The common positively charged electrolytes are *sodium* (Na^+), *potassium* (K^+), *calcium* (Ca^{2+}), and *magnesium* (Mg^{2+}). The common negatively charged electrolytes are *chloride* (Cl^-) and *bicarbonate* (HCO_3^-). These charged particles should be present at all times for proper functioning of cells. An electrolyte imbalance occurs when serum concentration is either too high or too low. Calcium imbalance can affect the bones, kidneys, gastrointestinal tract, and neuromuscular activity, and sodium imbalance will affect blood pressure, nerve functioning, and fluid levels surrounding cells. Potassium ion imbalance impairs heart and muscular activity.

Electromyography or **EMG** (e-lek-tro-mi-OG-rah-fe): Recording of the electrical activity of muscle tissue using electrodes attached to the skin or inserted into the muscle. This procedure detects neuromuscular abnormalities.

Electrophoresis: See SERUM PROTEIN ELECTROPHORESIS.

■ Radiology, Ultrasound, and Imaging Procedures
■ Nuclear Medicine—Radionuclide Scans

■ Clinical Procedures
■ Laboratory Tests

- ELISA** (eh-LI-zah): A laboratory assay (test) for the presence of antibodies to abnormal proteins such as tumor antigens or viruses, such as HIV. ELISA is an acronym for *enzyme-linked immunosorbent assay*. It also is known as *EIA* or *enzyme immunoassay*.
- Endoscopic retrograde cholangiopancreatography** or **ERCP** (en-do-SKOP-ik REH-tro-grayd kol-an-je-o-pan-kre-ah-TOG-rah-fe): X-ray recording of the bile ducts, pancreas, and pancreatic duct using radiopaque contrast injected through an endoscope, passed through the mouth, esophagus, and duodenum into the bile and pancreatic ducts, and x-ray images are then obtained.
- Endoscopic ultrasonography** or **E-US** (en-do-SKOP-ik ul-trah-so-NOG-rah-fe): Sound waves are generated from a tube inserted through the mouth and into the esophagus. The sound waves bounce off internal structures and are detected by surface coils. This study can detect enlarged cancerous lymph nodes and tumors in the chest and upper abdomen. This procedure is used for *staging* (evaluation of size and spread) of gastric and esophageal tumors.
- Endoscopy** (en-DOS-ko-pe): Inspection of an organ or body cavity through a narrow, tube-like instrument (endoscope) inserted into the organ or cavity. The endoscope is placed through a natural opening (the mouth or anus) or into a surgical incision, such as through the abdominal wall. Endoscopes contain bundles of glass fibers that carry light (fiberoptic); some instruments are equipped with a small forceps-like device that withdraws a sample of tissue for microscopic study (biopsy). Examples of endoscopy are bronchoscopy, colonoscopy, esophagoscopy, gastroscopy, and laparoscopy.
- Erythrocyte sedimentation rate** (eh-RITH-ro-site sed-ih-men-TA-shun rate): Measurement of the rate at which red blood cells (erythrocytes) in well-mixed venous blood settle to the bottom (sediment) of a test tube. If the rate of sedimentation is markedly rapid (elevated rate), it may indicate inflammatory conditions, such as rheumatoid arthritis, or conditions that produce excessive proteins in the blood. On laboratory reports, usually abbreviated *ESR* or *sed rate*.
- Esophagogastroduodenoscopy** or **EGD** (eh-SOF-ah-go-GAS-tro-du-o-den-NOS-ko-pe): Visual examination of the esophagus, stomach, and first part of the small intestine using an endoscope inserted through the mouth and down the throat.
- Esophagography** (eh-sof-ah-GOG-rah-fe) or **esophagogram** (eh-SOF-ah-go-gram): X-ray recording or record of the esophagus performed after barium sulfate is swallowed. This test is part of a BARIUM SWALLOW and UPPER GASTROINTESTINAL EXAMINATION.
- Esophagoscopy** (eh-sof-ah-GOS-ko-pe): Visual examination of the esophagus performed through an endoscope inserted into the mouth and down the throat. This procedure allows detection of ulcers, tumors, or other lesions.
- Estradiol assay** (es-trah-DI-ol AS-a): Test for the concentration of estradiol, which is the predominant form of estrogen (female hormone) in serum, plasma, or urine.
- Estrogen receptor assay** (ES-tro-jen re-SEP-tor AS-a): Test performed on a breast biopsy specimen to determine whether a sample of tumor contains an estrogen receptor protein. If the protein is present (positive result) on breast cancer cells, this indicates that estrogens can stimulate growth of the tumor. Then treatment with an anti-estrogen drug would retard tumor growth. If the assay result is

negative (the protein is not present), then the tumor cells would not be killed by anti-estrogen drug treatment.

Excisional biopsy (ek-SIH-zhin-al BI-op-se): See BIOPSY.

Exophthalmometry (eks-of-thal-MOM-eh-tre): Measurement of the extent of protrusion of the eyeball in *exophthalmos*. Exophthalmos may be caused by tumors behind the eye, or by an overactive thyroid gland.

F

Fluorescein angiography (flur-uh-seen an-je-OG-rah-fe): Fluorescein (a contrast substance) is injected intravenously and the movement of blood is observed by ophthalmoscopy. It is used to detect diabetes or hypertensive retinopathy and also degeneration of the macular (central) area of the retina.

Fluoroscopy (flur-OS-ko-pe): An x-ray examination that uses a fluorescent screen rather than a photographic plate to show images of the body in motion. X-rays that have passed through the body strike a screen covered with a fluorescent substance that emits yellow-green light. Internal organs are seen directly (still images are stored either on film or on a computer as digital images) and in motion. Fluoroscopy is used to guide the insertion of catheters and to direct organ biopsy, and may be enhanced with barium ingestion. CT-guided biopsy is used most often now.

Frozen section (fro-zen SEK-shun): Technique for (or method of) rapid preparation of a biopsy sample for examination during an actual surgical procedure. Tissue is taken from the operating room to the pathology laboratory and frozen. It is then thinly sliced, stained, and immediately examined with a microscope to determine whether the sample is benign or malignant and to determine the status of margins around a tumor.

G

Gallbladder ultrasound (GAWL-blah-der UL-trah-sownd): Sound waves are used to visualize gallstones. This procedure has replaced the x-ray test known as cholecystography.

Gallium scan (GAL-e-um scan): Radioactive gallium (gallium citrate) is injected into the bloodstream and is detected in the body with a scanning device that produces an image of the areas where gallium collects. Gallium accumulates in sites where cells are dividing, such as certain tumors and areas of inflammation.

Gastroscopy (gas-TROS-ko-pe): Visual examination of the stomach through an endoscope inserted down through the esophagus, for either diagnostic inspection or biopsy. When the upper portion of the small intestine is also visualized, the procedure is called *esophagogastroduodenoscopy (EGD)*.

Glucose test (GLU-kos test): Measurement of the amount of glucose (sugar) in serum and plasma. High levels of glucose (*hyperglycemia*) indicate the presence of diabetes mellitus. Glucose also is measured in urine, where its presence also usually indicates diabetes mellitus. The *fasting blood sugar test* is measurement of blood sugar after a patient has fasted.

■ Radiology, Ultrasound, and Imaging Procedures
■ Nuclear Medicine—Radionuclide Scans

■ Clinical Procedures
■ Laboratory Tests

Glucose tolerance test (GLU-kos TOL-er-ans test): Test to determine how the body responds to glucose. In the first part of this test, blood and urine samples are taken after the patient has fasted. Then a solution of 100 grams of glucose is given by mouth. Additional blood and urine samples are obtained a half hour after the glucose is taken and again at intervals of up to 2 hours to determine the rate of rise in and then the fall of glucose in the blood. This test will diagnose diabetes mellitus.

H

Hematocrit (he-MAT-o-krit): Measurement of the percentage blood volume occupied by red blood cells. The normal range is 40% to 50% in males and 37% to 47% in females. A low hematocrit indicates anemia. On laboratory reports, usually abbreviated *Hct* or *HCT*.

Hemoccult test (he-mo-KULT test): Examination of small sample of stool for otherwise in apparent occult (hidden) traces of blood. The sample is placed on the surface of a collection kit and reacts with a chemical (e.g., guaiac). A positive result may indicate bleeding from polyps, ulcers, or malignant tumors. This is an important screening test for colon cancer. Also called a STOOL GUAIAIC TEST.

Hemoglobin assay (HE-mo-glo-bin AS-a): Measurement of the concentration of hemoglobin (protein that carries oxygen in red blood cells) in blood. The normal blood hemoglobin ranges are 13.0 to 17.0 g/dL in adult males and 12.0 to 15.0 g/dL in adult females. On laboratory reports, usually abbreviated *Hb* (or *hgb* or *Hgb*).

Holter monitoring (HOL-ter MON-ih-ter-ing): Electrocardiographic recording of heart activity over an extended period of time. The Holter monitor device is worn by the patient as normal daily activities are performed. It detects heart rhythm abnormalities. Also called *ambulatory electrocardiography*.

Human chorionic gonadotropin assay (HU-man kor-e-ON-ik go-nad-o-TRO-pin AS-a): Measurement of the concentration of human chorionic gonadotropin (a hormone secreted by cells of the fetal placenta) in urine. It is detected in urine within days after fertilization of egg and sperm cells and provides the basis of the most commonly used pregnancy test. It also is elevated in patients with certain tumors. On laboratory reports, usually abbreviated *HCG* or *hCG*.

Hysterosalpingography (his-ter-o-sal-ping-OG-rah-fe) or **hysterosalpingogram** (his-ter-o-sal-PING-o-gram): X-ray recording (imaging) or record of the uterus and fallopian tubes. Contrast material is inserted through the vagina into the uterus and fallopian tubes, and x-ray images are obtained to detect blockage or tumor.

Hysteroscopy (his-ter-OS-ko-pe): Visual examination of the uterus using an endoscope passed through the uterine neck or cervix into the uterus.

I

Immunoassay (im-u-no-AS-a): A method of testing blood and urine for the concentration of various chemicals, such as hormones, drugs, or proteins. The technique makes use of the immunological reaction between antigens and antibodies. An *assay* is a determination of the amount of any particular substance in fluid or tissue.

Immunoglobulin test (im-u-no-GLOB-u-lin test): Measurement (in serum) of proteins (antibodies) that bind to and destroy foreign substances (antigens). Immunoglobulins are made by cells of the immune system.

Immunohistochemistry (im-u-no-his-to-KEM-is-tre): An antibody tagged with a fluorescent label or dye is spread over a tissue biopsy specimen and used to detect the presence of a particular antigen produced by the tissue or a tumor or infection.

Incisional biopsy (in-SIZH-un-al BI-op-se): See BIOPSY.

Intravenous pyelography: See UROGRAPHY.

K

Kidneys, ureters, bladder (KID-nee-z, UR-eh-terz, BLAH-der) or **KUB**: X-ray images of the kidney, ureters, and urinary bladder, made without contrast material.

L

Laparoscopy (lap-ah-ROS-ko-pe): Examination of the abdominal cavity through an endoscope inserted into the abdomen. After the patient receives a local anesthetic, a laparoscope is placed through an incision in the abdominal wall. This procedure gives the physician a view of the abdominal cavity, the surface of the liver and spleen, and the pelvic region. Laparoscopy can be used to remove some organs (such as the gallbladder, appendix, and ovary) and tumors and for fallopian tube ligation to prevent pregnancy.

Laryngoscopy (lah-rin-GOS-ko-pe): Visual examination of the voice box (larynx) through an endoscope inserted down the trachea (airway). The laryngoscope transmits a magnified image of the larynx through a system of lenses and mirrors. The procedure can reveal tumors and explain changes in the voice. Sputum samples and tissue biopsy specimens are obtained by using brushes or forceps attached to the laryngoscope.

Lipid tests (LIP-id tests): Lipids are fatty substances such as cholesterol and triglycerides. See CHOLESTEROL and TRIGLYCERIDE.

Lipoprotein tests (li-po-PRO-teen tests): See CHOLESTEROL.

Liver function tests (LIV-er FUNG-shun tests): See ALKALINE PHOSPHATASE, BILIRUBIN, ALT, and AST.

Lower gastrointestinal examination (LO-wer gas-tro-in-TES-tin-al ek-zam-ih-NA-shun): X-ray pictures of the colon taken after a liquid contrast substance called barium sulfate is inserted through a plastic tube (enema) into the rectum and large intestine (colon). If a tumor is present in the colon, it may appear as an obstruction or irregularity. Also known as a BARIUM ENEMA.

Lumbar puncture or **LP** (LUM-bar PUNK-shur): Introduction of a hollow needle into a space surrounding the spinal cord to withdraw fluid for analysis. Contrast material may be injected for imaging. Medicines may be introduced for treating disease involving the central nervous system.

- Radiology, Ultrasound, and Imaging Procedures
- Nuclear Medicine—Radionuclide Scans

- Clinical Procedures
- Laboratory Tests

M

Magnetic resonance imaging or **MRI** (mag-NET-ik REZ-o-nans IM-ah-jing): A powerful magnetic field is created surrounding the whole patient, or only the head, and water molecules are aligned and then relaxed, generating electromagnetic currents that provide a detailed picture of organs and blood vessels. A computer produces images of body structures at successive depths (as with CT slices). This procedure is particularly useful for imaging tumors of the brain and spinal cord and abnormalities of the lungs and abdominal and pelvic organs. No x-rays are used, and the study may be performed with intravenous contrast material (gadolinium), depending on the purpose of the evaluation. In *magnetic resonance angiography* (*MRA* or *MR angiography*), blood vessels are examined in key areas of the body such as the brain, kidneys, pelvis, legs, lungs, and heart.

Mammography (mah-MOG-rah-fe) or **mammogram** (MAM-o-gram): X-ray recording or record of the breast. X-rays of low voltage are beamed at the breast, and images are produced. Mammography detects abnormalities in breast tissue, such as breast cancer. In *stereotactic breast biopsy*, a hollow needle is passed through the skin into a suspicious lesion with the help of mammographic imaging. Breast tomosynthesis, also called 3D mammography, creates 3-dimensional images of the breast and aids in detection early breast disease.

Mediastinoscopy (me-de-ah-stih-NOS-ko-pe): Procedure for viewing structures in the mediastinum through an endoscope inserted into this space (in the chest between the lungs and in front of the heart). A *mediastinoscope* is introduced through a small incision in the neck while the patient is under anesthesia. This procedure is used to biopsy lymph nodes and suspected tumors within the mediastinum.

MUGA scan (MUH-gah scan): Test that uses radioactive technetium to measure the rate of cardiac output of blood by a *multiple-gated acquisition* (MUGA) technique. Also called *technetium-99m ventriculography*.

Muscle biopsy (MUH-sl BI-op-se): A sample of muscle tissue is removed and analyzed microscopically.

Myelography (mi-eh-LOG-rah-fe) or **myelogram** (MI-eh-lo-gram): X-ray recording of the spinal cord after injection of contrast. This procedure has been largely replaced by MRI for detecting tumors or ruptured “slipped” disks between vertebrae (backbones).

N

Nasogastric intubation (na-zo-GAS-trik in-tu-BA-shun): Insertion of a tube through the nose into the stomach to withdraw fluid for analysis or to give nutrition directly into the stomach.

Needle biopsy (NE-dl BI-op-se): See BIOPSY.

O

Occult blood test: See HEMOCCULT TEST.

Ophthalmoscopy (of-thal-MOS-ko-pe): Visual examination of the eye. A physician uses an *ophthalmoscope* to look directly into the eye, evaluating the optic nerve,

retina, and blood vessels in the back of the eye and the lens in the front of the eye for cataracts. In *fluorescein angiography*, a contrast substance is injected intravenously, and movement of the dye through blood vessels in the back of the eye is observed with ophthalmoscopy.

Otoscopy (o-TOS-ko-pe): Visual examination of the interior of the ear. A physician uses an *otoscope* inserted into the ear canal to check for obstructions (e.g., wax), infection, fluid, and eardrum perforation or scarring.

P

Palpation (pal-PA-shun): Examination by touch. This is a technique of manual physical examination by which a doctor feels underlying tissues and organs through the skin.

Pap smear (pap smear): Insertion of a cotton swab or wooden spatula into the vagina to obtain a sample of cells from the outer surface of the cervix (neck of the uterus). The cells are then smeared on a glass slide, preserved, and sent to the laboratory for microscopic examination. This test for cervical cancer was developed by and named after the late Dr. George Papanicolaou. Results are graded and reported as negative (no abnormalities) or ranging from mildly abnormal (presence of ASC or abnormal squamous cells) to high-grade squamous intraepithelial lesion (HSIL).

Paracentesis (pah-rah-sen-TE-sis): Surgical puncture of the membrane surrounding the abdomen (peritoneum) to remove fluid from the abdominal cavity. Fluid is drained for analysis and to prevent its accumulation in the abdomen. Also known as *abdominocentesis*.

PCR test: Blood test to find and analyze DNA and RNA in viruses, diagnose genetic diseases, and do DNA fingerprinting. Multiple copies of DNA or RNA are made. PCR stands for *polymerase chain reaction* and can detect very small amounts of RNA or DNA.

Pelvic exam (PEL-vik ek-ZAM): Physician inserts fingers into the vagina while keeping the other hand over the abdomen to palpate the uterus and ovaries. This examination checks the uterus and ovaries for enlargement, cysts, tumors, or abnormal bleeding. It is also known as an internal exam or a bimanual exam.

Percussion (per-KUSH-un): The technique of striking a part of the body with short, sharp taps of the fingers to determine the size, density, and position of the underlying parts by the sound obtained. Percussion is commonly used over the lungs to detect fluid, atelectasis, and infection, and on the abdomen to examine the liver.

Phlebotomy (fleh-BOT-o-me): Puncture of a vein to remove samples of blood for analysis. Also called *venipuncture*.

■ Radiology, Ultrasound, and Imaging Procedures
■ Nuclear Medicine—Radionuclide Scans

■ Clinical Procedures
■ Laboratory Tests

PKU test: Test that determines whether the urine of a newborn baby contains substances called *phenylketones*. If these ketones are present, the baby is diagnosed with a condition called *phenylketonuria* (*PKU*). *PKU* affects infants who lack a specific enzyme. When the enzyme is missing, high levels of *phenylalanine* (an amino acid) accumulate in the blood, affecting the infant's brain and causing mental retardation. This situation is prevented by placing the infant on a special diet that prevents accumulation of phenylalanine in the bloodstream.

Platelet count (PLAYT-let kownt): Determination of the number of clotting cells (platelets) in a sample of blood.

Positron emission tomography or **PET scan** (POZ-ih-tron e-MISH-un to-MOG-rah-fe scan): A radioactive substance (usually an isotope incorporated into a sugar-like molecule) that releases radioactive particles called positrons is injected and travels to specialized areas of the body. Because of the way in which the positrons are released, cross-sectional color pictures can be made showing the location of the radioactive substance. The most common use for PET scans is to detect cancer and examine the effects of cancer therapy by showing biochemical changes in tumors. Tumors pick up the radioactive substance (isotope) and appear as "hot spots" (areas of high glucose uptake) on the film. Also, PET scans can be performed on the heart to assess blood flow to heart muscle and to evaluate patients for coronary artery disease. PET scans of the brain are used to evaluate patients with memory disorders, seizure disorders, and brain tumors. Metabolically active parts of the brain appear as hot spots. *PET-CT* scans combine PET and CT imaging technology to aid localization of "hot" areas.

Potassium test (po-TAS-e-um test): Measurement of the concentration of potassium in serum. Potassium is an important chemical for regulating electrical currents and maintaining the cell membrane charge. Muscle and nerve function depends on movement of potassium and other electrolytes across the cell membrane. On laboratory reports, usually given as the symbol K^+ . See also **ELECTROLYTES**.

Pregnancy test (PREG-nan-se test): Measurement in blood or urine of *human chorionic gonadotropin*, or hCG, a hormone secreted by the placenta early in pregnancy.

Proctosigmoidoscopy (prok-to-sig-moy-DOS-ko-pe): Examination of the first 10 to 12 inches of the rectum and colon using an endoscope inserted through the anus. When the sigmoid colon is visualized with a longer (20-inch) flexible endoscope, the procedure is called *sigmoidoscopy*. The procedure detects polyps, malignant tumors, and sources of bleeding.

Progesterone receptor assay (pro-JES-teh-rone re-SEP-tor AS-a): Test to determine whether a sample of tumor contains a progesterone receptor protein. A positive test result identifies that a breast cancer tumor would be responsive to antihormone therapy.

Prostate-specific antigen (PSA) test (PROS-tat speh-SIH-fic AN-tih-jen): Blood test that measures the amount of an antigen elevated in patients with prostatic cancer and in some with an inflamed prostate gland. On laboratory reports, usually abbreviated *PSA*.

Protein electrophoresis: See **SERUM PROTEIN ELECTROPHORESIS**.

Prothrombin time (pro-THROM-bin time): Measurement of the activity of factors in the blood that participate in clotting. Deficiency of any of these factors can lead to a prolonged prothrombin time and difficulty in blood clotting. The test is important as a monitor for patients taking anticoagulants, substances that block the activity of blood clotting factors but increase the risk of bleeding.

Pulmonary angiography (PUL-mo-nair-e an-je-OG-rah-fe): X-ray images of blood vessels of the lung are obtained after injection of contrast. This procedure has been largely replaced by COMPUTED TOMOGRAPHY of the lung.

Pulmonary function test (PUL-mo-nair-e FUNG-shun test): Measurement of the volume and flow rate (ventilation) of air taken into and exhaled from the lungs by means of an instrument called a *spirometer*. Test results may be abnormal in patients with asthma, chronic bronchitis, emphysema, or occupational exposures to asbestos, chemicals, and dusts.

Pulmonary perfusion scan (PUL-mo-nair-e per-FU-shun scan): Radioactive particles are injected intravenously and travel rapidly to areas of the lung that are adequately filled with blood. Regions of obstructed blood flow caused by tumor, blood clot, swelling, and inflammation can be seen as nonradioactive areas on the scan.

Pulmonary ventilation scan (PUL-mo-nair-e ven-tih-LA-shun scan): Radioactive gas is inhaled, and a special camera detects its presence in the lungs. The scan is used to detect lung segments that fail to fill with the radioactive gas. Lack of filling is usually due to diseases that obstruct the bronchial tubes and air sacs. This scan is also used in the evaluation of lung function before surgery.

Pyelography or **pyelogram**: See UROGRAPHY.

R

Red blood cell (RBC) count: Test in which the number of erythrocytes in a sample of blood is counted. A low RBC count may indicate anemia. A high count can indicate *polycythemia vera*.

Rheumatoid factor assay (ROO-mah-toyd FAK-tor AS-a): Detection of the abnormal protein *rheumatoid factor* in the serum. This factor is found in patients with rheumatoid arthritis and some other autoimmune diseases.

S

Semen analysis (SE-men ah-NAL-ih-sis): Microscopic examination of sperm cells to detect number, viability, and motility of sperm cells.

Serum enzyme tests (SE-rum EN-zym tests): see CARDIAC ENZYME TESTS.

Serum protein electrophoresis test (SE-rum PRO-teen e-lek-tro-for-E-sis test): A procedure that separates proteins through their migration in an electric current. The material tested, such as serum, containing various proteins, is placed on gel or in liquid, and under the influence of an electric current, the proteins separate (-PHORESIS means separation) so that they can be identified and measured. The procedure is also known as *protein electrophoresis*.

■ Radiology, Ultrasound, and Imaging Procedures
■ Nuclear Medicine—Radionuclide Scans

■ Clinical Procedures
■ Laboratory Tests

Sigmoidoscopy (sig-moy-DOS-ko-pe): See PROCTOSIGMOIDOSCOPY.

Skin biopsy (skin BI-op-se): Procedure in which samples of skin lesions are removed and sent to the pathology laboratory for microscopic examination.

Skin tests: Tests in which substances are applied to the skin or injected under the skin and the reaction of immune cells in the skin is observed. These tests detect the patient's sensitivity to substances such as dust or pollen. They also can indicate whether the person has been exposed to the bacteria that cause tuberculosis or diphtheria.

Slit-lamp microscopy (slit-lamp mi-KROS-ko-pe): Examination of the anterior eye structures (such as the cornea) using an instrument that projects intense light through a narrow opening for optimal visualization.

SMA: See BLOOD CHEMISTRY PROFILE.

Small bowel follow-through: See BARIUM TESTS and UPPER GASTROINTESTINAL EXAMINATION.

Sodium level: Measurement of the concentration of sodium (Na^+) in serum. Sodium is one of the most important elements in the body. It is the chief *electrolyte* in fluid outside cells, and it exchanges with potassium within cells during muscle contraction or nerve conduction. Excess sodium is excreted by the kidneys, and sodium is thus involved in water (fluid) balance and acid-base chemical balance during muscle contraction or nerve conduction.

Sonography: See ULTRASONOGRAPHY.

Sputum test (SPU-tum test): Examination of mucus coughed up from the patient's lungs to detect tumor or infection. The sputum is examined microscopically, analyzed chemically, and cultured for the presence of microorganisms.

Stool culture (stool KUL-chur): Stool (feces) is placed in a growth medium (culture) and analyzed microscopically for evidence of microorganisms (bacteria).

Stool guaiac test (stool GWI-ak test): See HEMOCCULT TEST.

Stress test: Electrocardiography performed during exercise. With intense exercise, the ECG may become abnormal as a result of poor blood flow through blocked arteries. This study may reveal hidden heart disease or confirm the cause of cardiac signs and symptoms.

T

Technetium Tc-99m sestamibi scan (tek-NE-she-um Tc-99m ses-tah-MIH-be scan): Sestamibi, tagged with technetium-99, is injected, and the radioactivity is not taken up in areas of decreased blood flow (ischemia). This procedure can be used with an *exercise tolerance test (ETT-MIBI)* to help define areas of poor blood flow to the heart muscle.

Thallium-201 scintigraphy (THAL-e-um-201 sin-TIH-grah-fe): Thallium-201 is injected into a vein, and images of blood flow through the heart muscle are recorded. Cold spots correlate with areas of myocardial infarction. *Sestamibi scans* also are used to assess the status of blood flow through heart muscle during an *exercise tolerance test (ETT-MIBI)*. It also is useful in localizing disease of the parathyroid glands.

Thoracentesis (thor-ah-sen-TE-sis): Insertion of a needle into the chest to remove fluid from the space surrounding the lungs (pleural cavity). After injection of a local anesthetic, a hollow needle is placed through the skin and muscles of the back and into the space between the lungs and chest wall. Fluid is then withdrawn by applying suction. Excess fluid (*pleural effusion*) may be a sign of infection, heart failure, or malignant disease. This procedure is used to diagnose conditions, to drain a pleural effusion, or to re-expand a collapsed lung (*atelectasis*). This procedure can also be used to drain fluid (pleural effusion) from the pleural cavity.

Thoracoscopy (thor-ah-KOS-ko-pe): Visual examination of the surface of the lungs using an endoscope inserted through an incision in the chest. *VATS* is *video-assisted thoracoscopy* (or *thorascopy*).

Thyroid function tests (THI-royd FUNG-shun tests): Tests that measure the levels of thyroid hormones, such as *thyroxine* (T4) and *triiodothyronine* (T3), in serum. *Thyroid-stimulating hormone* (TSH), which is produced by the pituitary gland and stimulates the release of T4 and T3 from the thyroid gland, is also measured in serum. These tests diagnose hypothyroidism and hyperthyroidism, and are helpful in monitoring response to thyroid treatment.

Thyroid scan and uptake (THI-royd scan and UP-take): In a thyroid scan, radioactive iodine (the radiotracer) is injected intravenously or swallowed and then collects in the thyroid gland. A scanning device (probe) detects the radiotracer in the gland tissue, producing an image that shows the size, shape, and position of the thyroid. The thyroid uptake test, or *radioactive iodine uptake* (RAIU) test, evaluates the function of the thyroid. Radioactive iodine is swallowed, and a probe is placed over the thyroid gland to detect increased or decreased activity, as shown by the thyroid's ability to absorb the radiotracer. This test also can be used to detect areas of poor uptake (cold nodules), which may be cancerous.

Tomography (to-MOG-rah-fe) or **tomogram** (TO-mo-gram): X-ray recording or record that shows an organ in depth. Several pictures ("slices") are taken of an organ by moving the x-ray tube and film in sequence to blur out certain regions and bring others into sharper focus. Tomograms of the kidney and lung are examples.

Triglycerides test (tri-GLIS-er-ides test): Determination of the amount of triglycerides (fatty substances) in the serum. Elevated triglyceride levels (normal is 150 to 200 mg/dL) are considered to be an important risk factor for the development of heart disease.

Troponin test (tro-PO-nin): Measurement of levels of proteins *troponin I* and *troponin T* in blood is used to indicate the presence and degree of myocardial injury, as from a heart attack.

Tuning fork tests (TOO-ning fork tests): Procedure in which a vibration source (tuning fork) is placed in front of the opening to the ear to test air conduction of sound waves. The tuning fork is also placed on the mastoid bone behind the ear to test bone conduction of sound waves.

■ Radiology, Ultrasound, and Imaging Procedures

■ Nuclear Medicine—Radionuclide Scans

■ Clinical Procedures

■ Laboratory Tests

Tuberculin test (too-BUR-ku-lin tests): Agents are applied to the skin with punctures or injection and the reaction is noted. Redness and swelling result in people sensitive to the test substance and indicate previous or current infection with tuberculosis.

U

Ultrasonography (ul-trah-so-NOG-rah-fe) or **ultrasound imaging** (UL-trah-sownd IM-a-jing): Images are produced by beaming high-frequency sound waves (not x-rays) into the body and capturing the echoes that bounce off organs. These echoes are then processed to produce an image showing the difference between fluid and solid masses and the general position of organs. Because ultrasound images are captured in real time, they can show structure and movement of internal organs, as well as blood flowing through blood vessels. Ultrasonography is particularly useful for detecting gallstones, fibroid tumors of the uterus and ovarian tumors and cysts (*pelvic ultrasonography*), enlargement of the heart or defects in heart valves (*echocardiography*), blood flow through major arteries and veins (*Doppler ultrasound*), and enlargement of lymph nodes in the abdomen and chest. Also called *sonography*.

Upper gastrointestinal examination (UP-er gas-tro-in-TEs-tin-al ek-zam-ih-NA-shun): X-ray pictures are taken of the esophagus (BARIUM SWALLOW), duodenum, and small intestine after a liquid contrast substance (barium sulfate) is swallowed. In a *small bowel follow-through*, pictures are taken at increasing time intervals to follow the progress of barium through the small intestine. Identification of obstructions or ulcers is possible.

Uric acid test (UR-ik AS-id test): Measurement of the amount of uric acid (a nitrogen-containing waste material from breakdown of DNA and RNA) in the serum. High serum levels are associated with a type of arthritis called *gout*. In gout, uric acid accumulates as crystals in joints and in tissues. High levels of uric acid may also cause kidney stones.

Urinalysis (u-rih-NAL-ih-sis): Examination of urine as an aid in the diagnosis of disease. Routine urinalysis involves the observation of unusual color or odor; determination of specific gravity (amount of materials dissolved in urine); chemical tests (for protein, sugar, acetone); and microscopic examination for bacteria, blood cells, and sediment. Urinalysis is used to detect abnormal functioning of the kidneys and bladder, infections, and diabetes mellitus. On laboratory reports, usually abbreviated *UA*.

Urography (u-ROG-rah-fe) or **urogram** (U-ro-gram): X-ray recording (imaging) of the kidney and urinary tract. If x-ray pictures are taken after contrast material is injected intravenously, the procedure is called *intravenous urography* (*descending* or *excretion urography*) or *intravenous pyelography* (*IVP*). If x-ray pictures are taken after introduction of contrast directly into the bladder through the urethra, the study is called a *cystogram*. If contrast flows up the ureters into the kidneys, the procedure is called *retrograde urography* or *retrograde pyelography*. **PYEL/O** means renal pelvis (the collecting chamber of the kidney).

V

Venography (ve-NOG-rah-fe): X-ray examination of veins performed after contrast material is injected into veins. It is used to detect *deep vein thrombosis*, *pulmonary emboli*, or *venous insufficiency*.

Ventilation-perfusion scan or **V/Q scan**: Nuclear medicine test that uses radioactive materials (radiopharmaceuticals) to examine air flow (ventilation) and blood flow (perfusion) in the lungs. The purpose of this scan is find evidence of a blood clot (pulmonary embolism) in the lungs. Scans are performed together. If ventilation occurs in a segment that is not perfused, the mismatch implies a pulmonary embolism. When the scans match, abnormalities may reflect pneumonia or other lung disease.

Viral load test for HIV: Measures the number of viral particles in the blood. It is used to determine the effectiveness of antiviral treatment.

Voiding cystourethrogram (voy-ding sis-to-u-RE-thro-gram) or **VCUG**: X-ray films of the bladder and urethra taken after the bladder is filled with a contrast material and while the patient is expelling urine.

W

Western blot (WES-tern blot): Test used to detect infection by *HIV* (the AIDS virus). It is more specific than the ELISA. A patient's serum is mixed with purified proteins from HIV, and the reaction is examined. If the patient has made antibodies to HIV, those antibodies react with the purified HIV proteins, and the test result is positive.

White blood cell (WBC) count: Determination of the number of leukocytes in the blood. Higher-than-normal counts can indicate the presence of infection or leukemia. A *differential* (differential count) is the percentages of different types of white blood cells (neutrophils, eosinophils, basophils, lymphocytes, and monocytes) in a sample of blood. It gives more specific information about leukocytes and aids in the diagnosis of infection, allergic diseases, disorders of the immune system, and various forms of leukemia.

■ Radiology, Ultrasound, and Imaging Procedures
■ Nuclear Medicine—Radionuclide Scans

■ Clinical Procedures
■ Laboratory Tests

APPENDIX 3

Abbreviations, Acronyms, Symbols, and Eponyms

Abbreviations [318](#)

Acronyms [329](#)

Symbols [330](#)

Eponyms [331](#)

Abbreviations

A

AB	abortion
Ab	antibody
ABC	aspiration, biopsy, cytology
abd	abdomen
ABG	arterial blood gas
a.c., ac	before meals (<i>ante cibum</i>)
ACE	angiotensin-converting enzyme (ACE inhibitors treat hypertension)
ACL	anterior cruciate ligament (of knee)
ACS	acute coronary syndrome (myocardial infarction, unstable angina)
ACTH	adrenocorticotropic hormone (secreted by the pituitary gland)
AD	Alzheimer disease
ADD	attention deficit disorder
ADH	antidiuretic hormone (secreted by the pituitary gland)
ADHD	attention deficit/hyperactivity disorder
ad lib	freely as desired (<i>ad libitum</i>)
AED	automated external defibrillator
AICD	automatic implantable cardioverter-defibrillator
AIDS	acquired immunodeficiency syndrome
alb	albumin (protein)
ALL	acute lymphocytic leukemia
alk phos	alkaline phosphatase (enzyme elevated in liver disease)
ALS	amyotrophic lateral sclerosis (Lou Gehrig disease)
ALT	alanine transaminase (enzyme elevated in liver disease); formerly called SGPT
AMI	acute myocardial infarction
AML	acute myelocytic (myelogenous) leukemia
ANA	antinuclear antibody; test for rheumatoid arthritis
AP or A/P	anteroposterior (front to back)
A&P	auscultation and percussion
aq	water (<i>aqua</i>)
ARDS	acute respiratory distress syndrome
AS	aortic stenosis
ASD	atrial septal defect
ASHD	arteriosclerotic heart disease
AST	aspartate transaminase (elevated in liver and heart disease); formerly called SGOT
AV	arteriovenous; atrioventricular
A&W	alive and well

B

BE	barium enema
B cells	white blood cells (lymphocytes) produced in bone marrow
b.i.d., bid	twice a day (<i>bis in die</i>)
BM	bowel movement; bone marrow
BMT	bone marrow transplant
BP, B/P	blood pressure
BPH	benign prostatic hypertrophy (hyperplasia)
Bronch	bronchoscopy
bs	blood sugar; bowel sounds; breath sounds
BSE	breast self-examination
BSO	bilateral salpingo-oophorectomy
BUN	blood urea nitrogen (test of kidney function)
BW	birth weight
Bx, bx	biopsy

C

c̄	with (<i>cum</i>)
C1, C2	first cervical vertebra, second cervical vertebra
CA	cancer; carcinoma; cardiac arrest; chronologic age
Ca	calcium
CABG	coronary artery bypass graft
CAD	coronary artery disease

CAPD	continuous ambulatory peritoneal dialysis
cap	capsule
cath	catheter; catheterization
CBC	complete blood count
cc	cubic centimeter (1 cc equals 1/1000 liter, or 1 mL)
CC	chief complaint
CCU	coronary care unit; critical care unit
CF	cystic fibrosis
Chemo	chemotherapy
CHF	congestive heart failure
Chol	cholesterol
CIN	cervical intraepithelial neoplasia
CIS	carcinoma in situ
CKD	chronic kidney disease
cm	centimeter (1 cm is 1/100 meter)
CLL	chronic lymphocytic leukemia
CML	chronic myelocytic (myelogenous) leukemia
CNS	central nervous system
c/o	complains of
CO ₂	carbon dioxide
COPD	chronic obstructive pulmonary disease
CP	cerebral palsy; chest pain
CPAP	continuous positive airway pressure (provided by machine to aid breathing in patients with sleep apnea)
CPD	cephalopelvic disproportion
CPR	cardiopulmonary resuscitation
C&S, C+S	culture and sensitivity (testing)
C-section, CS	cesarean section
CSF	cerebrospinal fluid
CT scan	computed tomography scan (x-ray images in cross-sectional view)
CVA	cerebrovascular accident (stroke)
c/w	compare with; consistent with
CX, CXR	chest x-ray (image)
Cx	cervix
cysto	cystoscopy

D

D&C	dilation (dilatation) and curettage (of the uterine lining)
DES	diethylstilbestrol (estrogen causing defects in children whose mothers took the drug during pregnancy)
DEXA (DXA)	dual-energy x-ray absorptiometry
DIC	disseminated intravascular coagulation
diff.	differential (percentages of types of white blood cells)
DJD	degenerative joint disease
DKA	diabetic ketoacidosis
DM	diabetes mellitus
DNA	deoxyribonucleic acid
DNR	do not resuscitate
DOB	date of birth
DOE	dyspnea on exertion
DOMS	delayed-onset muscle soreness
DRE	digital rectal examination
DT	delirium tremens (caused by alcohol withdrawal)
DTR	deep tendon reflex
DUB	dysfunctional uterine bleeding
DVT	deep vein thrombosis
Dx	diagnosis

E

EBV	Epstein-Barr virus (cause of mononucleosis)
ECC	emergency cardiac care
ECG	electrocardiography
ECHO	echocardiography
ECMO	extracorporeal membrane oxygenator
ECT	electroconvulsive therapy
ED	emergency department; erectile dysfunction
EDD	expected date of delivery
EEG	electroencephalography

EENT	eyes, ears, nose, throat
EGD	esophagogastroduodenoscopy
EKG	electrocardiography (<i>ECG</i> is preferred)
ELISA	enzyme-linked immunosorbent assay (e.g., used as an AIDS test)
EMG	electromyography
ENT	ears, nose, throat
eos.	eosinophils (type of white blood cell)
ER	emergency room; estrogen receptor
ERCP	endoscopic retrograde cholangiopancreatography
ESR	erythrocyte sedimentation rate; see <i>sed rate</i>
ESRD	end-stage renal disease
ESWL	extracorporeal shock wave lithotripsy
ET	endotracheal
ETOH	ethyl alcohol (ethanol)
ETT	exercise tolerance test; endotracheal tube

F

FBS	fasting blood sugar
FDA	U.S. Food and Drug Administration
FDG-PET	fluorodeoxyglucose positron emission tomography (nuclear medicine test)
Fe	iron
FEV	forced expiratory volume
FH	family history
FHR	fetal heart rate
FSH	follicle-stimulating hormone (secreted by the pituitary gland)
F/U, f/u	follow-up
FUO	fever of unknown (undetermined) origin
Fx	fracture

G

G	gravida (a pregnant woman)
g, gm	gram
Ga	gallium (element used in nuclear medicine diagnostic tests)
GB	gallbladder
GC	gonococcus (bacterial cause of gonorrhea; another name for <i>Neisseria gonorrhoeae</i>)
Gd	gadolinium (widely used MRI contrast agent)
GERD	gastroesophageal reflux disease
GH	growth hormone (secreted by the pituitary gland)
GI	gastrointestinal
Grav. 1, 2, 3	gravida—a woman who has had a first, second, or third pregnancy of any duration
GFR	glomerular filtration rate
gt, gtt	drop, drops
GTT	glucose tolerance test
GU	genitourinary
GVHD	graft-versus-host disease
Gy	gray (unit of irradiation)
GYN, gyn	gynecology

H

H	hydrogen
h, hr	hour
HAART	highly active antiretroviral therapy (for AIDS)
Hb, hgb, Hgb	hemoglobin
HbA1c	glycosylated hemoglobin (measured to test for diabetes)
HBV	hepatitis B virus
HCG, hCG	human chorionic gonadotropin (secreted during pregnancy)
Hct, HCT	hematocrit
HCV	hepatitis C virus
HD	hemodialysis (performed by artificial kidney machine); heart disease
HDL	high-density lipoprotein (associated with decreased incidence of coronary artery disease)
HEENT	head, ears, eyes, nose, throat
Hg	mercury
Hgb, hgb, Hb	hemoglobin

HIPAA	Health Insurance Portability and Accountability Act (of 1996)
HIV	human immunodeficiency virus
h/o	history of
H ₂ O	water
H&P	history and physical (examination)
HPV	human papillomavirus
HRT	hormone replacement therapy
h.s.	at bedtime (<i>hora somni</i>); write out so as not to confuse with hs (half strength)
HSG	hysterosalpingography
HSV-1, HSV-2	herpes simplex virus type 1, type 2
HTN	hypertension (high blood pressure)
Hx	History

I

I	iodine
¹³¹ I	radioactive isotope of iodine
I&D	incision and drainage
IBD	inflammatory bowel disease (ulcerative colitis and Crohn disease)
IBS	irritable bowel syndrome (of unknown etiology)
ICD	implantable cardioverter-defibrillator
ICU	intensive care unit
ID	infectious disease
IgA, IgD, IgE, IgG, IgM	immunoglobulins (antibodies)
IM	intramuscular; infectious mononucleosis
INH	isoniazid (drug to treat tuberculosis)
INR	international normalized ratio (system for reporting results of blood coagulation tests)
I&O	intake and output (measurement of patient's fluids)
IOL	intraocular lens (implant)
IUD	intrauterine device (contraceptive)
IV	intravenous
IVF	<i>in vitro</i> fertilization
IVP	intravenous pyelography; intravenous push

K

K	potassium
kg	kilogram (1 kg is 1000 grams)
KS	Kaposi sarcoma (malignant lesion associated with AIDS)
KUB	kidneys, ureters, bladder (x-ray study without contrast)

L

L, l	left; liter; lower
L1, L2	first lumbar vertebra, second lumbar vertebra
LA	left atrium
LAD	left anterior descending artery (of the heart); lymphadenopathy
lat	lateral
LBP	low back pain; low blood pressure
LDH	lactate dehydrogenase (elevations associated with heart attacks)
LDL	low-density lipoprotein (high levels associated with heart disease)
LE	lupus erythematosus
LEEP	loop electrocautery excision procedure
LES	lower esophageal sphincter
LFTs	liver function tests
LLQ	left lower quadrant (of the abdomen)
LMP	last menstrual period
LP	lumbar puncture
LPN	licensed practical nurse
LTB	laryngotracheal bronchitis (croup)
LUQ	left upper quadrant (of the abdomen)
LV	left ventricle
LVAD	left ventricular assist device (bridge to cardiac transplantation)
L&W	living and well
lymphs	lymphocytes
lytes	electrolytes

M

m	meter; milli (one thousandth)
MAC	monitored anesthesia care
MCH	mean corpuscular hemoglobin (amount in each red blood cell)
MCHC	mean corpuscular hemoglobin concentration (amount per unit of blood)
MCV	mean corpuscular volume (size of individual red blood cell)
MD, M.D.	doctor of medicine; muscular dystrophy
MDI	metered-dose inhaler
MDS	myelodysplastic syndrome (a bone marrow disorder)
met	metastases
mg	milligram (1 mg is 1/1000 gram)
Mg	magnesium
MH	marital history; mental health
MI	myocardial infarction (heart attack)
mL	milliliter (1 mL is 1/1000 liter)
mm	millimeter (1 mm is 1/1000 meter)
mm Hg	millimeters of mercury (units for measurement of blood pressure)
mono	monocytes (type of white blood cell)
MRA	magnetic resonance angiography
MRI	magnetic resonance imaging
MRSA	methicillin-resistant <i>Staphylococcus aureus</i>
MS	mental status; mitral stenosis; multiple sclerosis
MSW	medical social worker
MTD	maximum tolerated dose
MVP	mitral valve prolapse
myop	myopia (nearsightedness)

N

N	nitrogen
Na	sodium
NB	newborn
NED	no evidence of disease
NG tube	nasogastric tube
NICU	neonatal intensive care unit
NKA	no known allergies
NPO	nothing by mouth (<i>nil per os</i>)
NSAID	nonsteroidal anti-inflammatory drug
NSR	normal sinus rhythm (of the heart)
NT	not tender (to touch)
NTP	normal temperature and pressure
N+V	nausea and vomiting

O

O₂	oxygen
OA	osteoarthritis
OB	obstetrics
OD	doctor of optometry
OR	operating room
ORIF	open reduction plus internal fixation (to set a broken bone)
ORTH, ortho.	orthopedics <i>or</i> orthopaedics
os	mouth
OSA	obstructive sleep apnea
OT	occupational therapy
OV	office visit

P

p̄	after; following
P	phosphorus; play; posterior; pressure; pulse; pupil
PA	posteroanterior (back to front); pulmonary artery
PAC	premature atrial contraction
PaCO₂, PaCO₂	arterial pressure of carbon dioxide in the blood; may also be written "arterial PCO ₂ "

PACS	picture archival communications system
palp	palpable; palpation (examine by touch)
PaO ₂ , PaO ₂	arterial pressure of oxygen in the blood; may also be written "arterial PO ₂ "
Pap smear	Papanicolaou smear (preparation of cells from the cervix and vagina for microscopic examination)
para	paracentesis (abdominocentesis)
Para 1, 2, 3	Woman who has produced one, two, or three viable offspring; unipara, bipara, tripara
p.c., pc	after meals (<i>post cibum</i>)
PCI	percutaneous coronary intervention
PCP	Pneumocystis pneumonia (opportunistic infection seen in patients with AIDS)
PE	physical examination; pulmonary embolus
PEEP	positive end-expiratory pressure
per	by
PERRLA	pupils equal, round, reactive to light and accommodation
PET	positron emission tomography
PE tube	pressure-equalizing tube (ventilating tube for the eardrum)
PFT	pulmonary function test
pH	hydrogen ion concentration (measurement of acidity or alkalinity of a solution)
PH	past history
PI	present illness
PID	pelvic inflammatory disease
PKU	phenylketonuria (disease due to lack of an enzyme in infants)
PM	afternoon (<i>post meridiem</i>); postmortem
PMH	past medical history
PMS	premenstrual syndrome
PND	paroxysmal nocturnal dyspnea; postnasal drip
p/o	postoperative
p.o., po	by mouth (<i>per os</i>)
polys	polymorphonuclear leukocytes (neutrophils)
poplit	popliteal (behind the knee)
post-op	after operation
PP	after meals (<i>postprandial</i>); after birth (<i>postpartum</i>)
PPD	purified protein derivative (skin test for tuberculosis)
pre-op	before operation (preoperative)
prep	prepare for
p.r.n., prn	as needed (<i>pro re nata</i>)
procto	proctoscopy (visual examination of the anus and rectum)
pro time	prothrombin time (test of blood clotting)
PSA	prostate-specific antigen (screening test for prostate cancer)
pt	patient
PT	physical therapy; prothrombin time
PTA	prior to admission (to hospital)
PTCA	percutaneous transluminal coronary angioplasty (balloon angioplasty)
PTH	parathyroid hormone
PTR	patient to return
PTSD	post-traumatic stress disorder
PTT	partial thromboplastin time (test of blood clotting)
PVC	premature ventricular contraction (abnormal heart rhythm)
PVD	peripheral vascular disease
PVT	paroxysmal ventricular tachycardia
PWB	partial weight bearing
Px	prognosis

Q

q	every (<i>quaque</i>)
q.d.	each (every) day (<i>quaque die</i>); better to write out "each day," because can be misread as q.i.d.
q.h.	each (every) hour (<i>quaque hora</i>)
q2h	each (every) two hours (<i>quaque secunda hora</i>)
q.i.d.	four times a day (<i>quater in die</i>)
q.n.	each (every) night (<i>quaque nox</i>)
q.n.s.	quantity not sufficient (<i>quantum non sufficit</i>)
q.s.	quantity sufficient (<i>quantum sufficit</i>)
qt	quart

R

R, r	respiration; right
RA	rheumatoid arthritis; right atrium

rad	radiation absorbed dose
RBC, rbc	red blood cell (count)
REM	rapid eye movement
RIA	radioimmunoassay (minute quantities are measured)
RLQ	right lower quadrant (of the abdomen)
R/O, r/o	rule out
ROM	range of motion
ROS	review of systems; reactive species
RP	retrograde pyelography (urography)
RR	recovery room; respiration rate
RRR	regular rate and rhythm (of the heart)
RT	radiation therapy; radiologic technologist; respiratory therapist
RUQ	right upper quadrant (of the abdomen)
RV	right ventricle (of the heart)
Rx	treatment; therapy; prescription (<i>recipe</i> , "to take")

S

S	without (<i>sine</i>)
S1, S2	first sacral vertebra, second sacral vertebra
S-A node	sinoatrial node (pacemaker of the heart)
SAD	seasonal affective disorder
SARS	severe acute respiratory syndrome
SBFT	small bowel follow-through (x-ray study of the small intestine with contrast)
sed rate	erythrocyte sedimentation rate (time it takes red blood cells to settle out of blood)
segs	segmented white blood cells (granulocytes)
SERM	selective estrogen receptor modulator (tamoxifen is an example)
s.gl.	without glasses
SGOT	see <i>AST</i>
SGPT	see <i>ALT</i>
SH	serum hepatitis; social history
sig.	"let it be labeled" (directions or medical instructions)
SIDS	sudden infant death syndrome
SIRS	systemic inflammatory response syndrome (severe bacteremia)
SLE	systemic lupus erythematosus
SMA-12	blood chemistry profile including 12 different studies or assays (sequential <i>multiple analysis</i>)
SOAP	subjective (symptoms perceived by the patient) data, objective (exam findings) data, assessment (evaluation of condition), plan (goals for treatment)
SOB	shortness of breath
S/P, s/p	status post (previous disease condition)
SPECT	single-photon emission computed tomography
sp. gr.	specific gravity
SSRI	selective serotonin reuptake inhibitor (antidepressant drug)
staph	staphylococci (bacteria)
STAT, stat	immediately (<i>statim</i>)
STD	sexually transmitted disease (older name for STI)
STI	sexually transmitted infection
strep	streptococci (bacteria)
sub-Q	subcutaneous (under the skin)
Sx	signs and symptoms
Sz	seizure

T

T	temperature; time
T1, T2	first thoracic vertebra, second thoracic vertebra
T3	triiodothyronine (thyroid gland hormone)
T4	thyroxine (thyroid gland hormone)
T&A	tonsillectomy and adenoidectomy
tab	tablet
TAB	therapeutic abortion
TAH-BSO	total abdominal hysterectomy–bilateral salpingo-oophorectomy
TB	tuberculosis
T cells	lymphocytes originating in the thymus gland
TEE	transesophageal echocardiography
TENS	transcutaneous electrical nerve stimulator
TFT	thyroid function test

THR	total hip replacement
TIA	transient ischemic attack
t.i.d., tid	three times a day (<i>tris in die</i>)
TLC	total lung capacity
TM	tympanic membrane
TMJ	temporomandibular joint
TNM	tumor-node-metastasis (staging system for cancer)
TPN	total parenteral nutrition (administration of IV solution to maintain nutrition)
TPR	temperature, pulse, respiration
TSH	thyroid-stimulating hormone (secreted by the pituitary gland)
TTE	transthoracic echocardiography
TUR, TURP	transurethral resection of the prostate gland
TVH	total vaginal hysterectomy
Tx	treatment

U

UA, U/A	urinalysis
UE	upper extremity
UGI	upper gastrointestinal
umb	navel (umbilical cord region)
ung	ointment
U/O	urine output
URI	upper respiratory infection
U/S, u/s	ultrasound (imaging examination)
UTI	urinary tract infection
UV	ultraviolet

V

VA	visual acuity
VATS	video-assisted thoracoscopy
VC	vital capacity (of lungs)
VCUG	voiding cystourethrogram
VEGF	vascular endothelial growth factor
VF	visual field; ventricular fibrillation
Vfib	ventricular fibrillation
VS, V/S	vital signs; versus
VSD	ventricular septal defect
VSS	vital signs stable
V tach, VT	ventricular tachycardia (abnormal heart rhythm)

W

WBC, wbc	white blood cell (count)
W/C	wheelchair
wd	wound
WDWN	well-developed and well-nourished
WNL	within normal limits
WT, wt	weight
w/u	workup

X

XRT	radiation therapy
-----	-------------------

Y

y, yr	year(s)
y/o	year(s) old

Acronyms*

An *acronym* is the name for an abbreviation that forms a pronounceable “word.”

ACE (ace)	angiotensin-converting enzyme
AIDS (aydz)	acquired immune deficiency syndrome
Apgar (apgahr)	appearance, pulse, grimace, activity, respiration (letters spell out name of originator of scoring system, Virginia Apgar)
BUN (bun)	blood urea nitrogen
CABG (cabbage)	coronary artery bypass graft (grafting)
CAT (cat)	computerized axial tomography (older name for CT)
CPAP (seepap)	continuous positive airway pressure
ELISA (eliza)	enzyme-linked immunosorbent assay
GERD (gird)	gastroesophageal reflux disease
HAART (heart)	highly active antiretroviral therapy
HIPAA (hippah)	Health Insurance Portability and Accountability Act of 1996
LASER (layzer)	light amplification by stimulated emission of radiation
LASIK (laysick)	laser in situ keratomileusis
LEEP (leap)	loop electrocautery excision procedure
MAC (mack)	monitored anesthesia care
MICU (mickyou)	medical intensive care unit
MIS (miss)	minimally invasive surgery
MODS (modz)	multiorgan dysfunction syndrome
MUGA (muh-guh)	multiple-gated acquisition (scan)
NICU (nickyou)	neonatal intensive care unit
NSAID (ensayd)	nonsteroidal anti-inflammatory drug
PACS (packs)	picture archival communications system
PALS (pals)	pediatric advanced life support
PEEP (peep)	positive end-expiratory pressure
PEG (peg)	percutaneous endoscopic gastrostomy
PERRLA (perlah)	pupils equal, round, reactive to light and accommodation
PET (pet)	positron emission tomography
PICC (pick)	peripherally inserted central catheter
PICU (pickyou)	pediatric intensive care unit
PIP (pip)	proximal interphalangeal (joint)
pixel (picksul)	picture element
PUVA (poovah)	psoralen ultraviolet A
REM (rem)	rapid eye movement
SAD (sad)	seasonal affective disorder
SARS (sarz)	severe acute respiratory syndrome
SERM (serm)	selective estrogen receptor modulator
SICU (sickyou)	surgical intensive care unit
SIDS (sidz)	sudden infant death syndrome
SIRS (sirz)	systemic inflammatory response syndrome
SMAC (smack)	sequential multiple analyzer computer (for blood testing)
SOAP (soap)	subjective, objective, assessment, plan (formatted approach to nursing care)
SPECT (spekt)	single-photon emission computed tomography
SPORE (spore)	specialized program of research excellence
TENS (tenz)	transcutaneous electrical nerve stimulation
TRUS (truss)	transrectal ultrasound
TURP (turp)	transurethral resection of the prostate
VATS (vatz)	video-assisted thoracoscopy
voxel (vocksul)	volume element (of CT scan)

Symbols*

=	equals
≠	does not equal
+	positive
-	negative
↑	above, increase
↓	below, decrease
♀	female
♂	male
→	to (in the direction of)
>	is greater than
<	is less than
1°	first-degree (burn, heart block); primary
2°	second-degree (burn, heart block); secondary
ʒ	dram
%	percent
°	degree; hour
:	ratio ("is to")
±	plus or minus (either positive or negative)
'	foot
"	inch
∴	therefore
@	at, each
\bar{c}	with (<i>cum</i>)
\bar{s}	without (<i>sine</i>)
#	pound; number
≈	approximately, about
Δ	change, change in
p	short arm of a chromosome
q	long arm of a chromosome

Eponyms

Achilles tendon (Achilles, Greek mythologic hero)	This tendon connects the calf muscles to the heel. It lies at the only part of Achilles' body that was still vulnerable after his mother dipped him as an infant into the river Styx, when she held him by the heel.
Alzheimer disease (Alois Alzheimer, German neurologist, 1864-1915)	Progressive mental deterioration marked by confusion, memory failure, and disorientation.
Apgar score (Virginia Apgar, American anesthesiologist, 1909-1974)	Evaluation of an infant's physical condition, usually performed 1 minute and then 5 minutes after birth. Highest score is 10. An Apgar rating of 9/10 is a score of 9 at 1 minute and 10 at 5 minutes.
Asperger syndrome (Hans Asperger, Austrian psychiatrist, 1906-1980)	Developmental disorder characterized by impairment of social interactions (resembling autism) but lacking in delays in language development and mental functioning.
Bell palsy (Charles Bell, Scottish surgeon, 1774-1842)	Unilateral (one-sided) paralysis of the facial nerve.
Barlow syndrome (John Barlow, South African cardiologist, born 1924)	Mitral valve prolapse.
Barrett esophagus (Norman Barrett, Australian thoracic surgeon, 1903-1979)	Abnormal changes in the lining of the esophagus, resulting from acid reflux from the stomach.
Burkitt lymphoma (Denis Burkitt, English surgeon in Africa, 1911-1993)	Malignant tumor of lymph nodes; chiefly seen in central Africa. The Epstein-Barr virus is associated with this lymphoma.
Cheyne-Stokes respiration (John Cheyne, Scottish physician, 1777-1836; William Stokes, Irish physician, 1804-1878)	Abnormal pattern of breathing with alternating periods of stoppage of breathing and deep, rapid breathing.
Colles fracture (Abraham Colles, Irish surgeon, 1773-1843)	Break (fracture) of the radius (bone near the wrist).
Crohn disease (Burrill B. Crohn, American physician, 1884-1983)	Chronic inflammatory bowel disease of unknown origin; usually affecting the ileum (last part of the small intestine), colon, or any part of the gastrointestinal tract.
Cushing syndrome (Harvey W. Cushing, American surgeon, 1869-1939)	Disorder resulting from chronic, excessive production of cortisol from the adrenal cortex. It can also result from administration of glucocorticoids (cortisone) in large doses for long periods of time.
Duchenne muscular dystrophy (Guillaume Benjamin Amand Duchenne, French neurologist, 1806-1875)	Abnormal, inherited condition that infants are born with; marked by progressive hardening of muscles in the leg and hips (pelvis).
Epstein-Barr virus (Michael A. Epstein, English pathologist, born 1921; Yvonne M. Barr, English virologist, born 1932)	The herpesvirus that causes infectious mononucleosis and is associated with malignant conditions such as nose and throat cancer, Burkitt lymphoma, and Hodgkin lymphoma.
eustachian tube (Bartolomeo Eustachio, Italian anatomist, 1524-1574)	A tube that joins the throat and the middle ear cavity.
Ewing sarcoma (James Ewing, American pathologist, 1866-1943)	Malignant tumor that develops from bone marrow, usually in long bones or the hip (pelvis).
fallopian tube (Gabriele Falloppio, Italian anatomist, 1523-1562)	One of a pair of tubes or ducts leading from the ovary to the upper portion of the uterus.
Foley catheter (Frederic Foley, American physician, 1891-1966)	Rubber tube that is placed in the urethra to provide drainage of urine.
Giardia (Alfred Giardia, French biologist, 1846-1908)	One-celled organism (protozoan) that causes gastrointestinal infection with diarrhea, abdominal cramps, and weight loss. Cause of infection usually is fecally contaminated water.
Hodgkin lymphoma (Thomas Hodgkin, English physician, 1798-1866)	Malignant tumor of the lymph nodes.
Horner syndrome (Johann Friedrich Horner, Swiss ophthalmologist, 1831-1886)	Partial ptosis (prolapse or drooping) of the upper eyelid, along with other signs of damage to nerves controlling the eye muscles and face.
Huntington disease (George S. Huntington, American physician, 1851-1916)	Rare, hereditary condition marked by chronic, progressively worsening dance-like movements (chorea) and mental deterioration, resulting in dementia.
Kaposi sarcoma (Moricz Kaposi, Austrian dermatologist, 1837-1902)	Malignant neoplasm of cells that line blood and lymph vessels. Soft brownish or purple papules appear on the skin. The tumor can metastasize to lymph nodes and internal organs. It often is associated with AIDS.
Marfan syndrome (Bernard-Jean A. Marfan, French pediatrician, 1858-1942)	Hereditary condition that affects bones, muscles, the cardiovascular system (leading to aneurysms) and eyes (lens dislocation). Affected people have long, "spidery" extremities, underdeveloped muscles, and easily movable joints.
Meniere disease (Prosper Meniere, French physician, 1799-	Chronic disease of the inner ear with recurrent episodes of dizziness (vertigo), hearing loss, and ringing in the ears (tinnitus).

1862)	
Neisseria gonorrhoeae (Albert L. S. Neisser, Polish dermatologist, 1855-1916)	A type of bacterium that causes gonorrhea (sexually transmitted infection).
Paget disease (James Paget, English surgeon, 1814-1899)	Disease of bone, often affecting middle-aged or elderly people; marked by bone destruction and poor bone repair.
Pap test (George Papanicolaou, Greek physician in the United States, 1883-1962)	Method of examining stained cells obtained from the cervix and vagina. It is a common way to detect cervical cancer.
Parkinson disease (James Parkinson, English physician, 1755-1824)	Slowly progressive degenerative neurological disorder marked by tremors, mask-like facial appearance, shuffling gait (manner of walking), and muscle rigidity and weakness.
Raynaud phenomenon (Maurice Raynaud, French physician, 1834-1881)	Intermittent attacks of loss of blood flow (ischemia) in the extremities of the body (fingers, toes, ears, and nose). Episodes most often are caused by exposure to cold.
Reye syndrome (R. Douglas Reye, Austrian pathologist, 1912-1978)	Acute brain disease (encephalopathy) and disease of internal organs following an acute viral infection.
Rinne test (Heinrich A. Rinne, German otologist, 1819-1868)	Hearing test using a vibrating tuning fork placed against a bone behind the patient's ear (mastoid bone).
Rorschach test (Herman Rorschach, Swiss psychiatrist, 1884-1922)	Personality test based on a patient's interpretation of 10 inkblots.
Salmonella (Daniel E. Salmon, American pathologist, 1850-1914)	Type of bacterium (rod-shaped) that causes typhoid fever and types of gastroenteritis (inflammation of the stomach and intestines).
Shigella (Kiyoshi Shiga, Japanese bacteriologist, 1870-1957)	Type of bacterium that causes severe infectious gastroenteritis (inflammation of stomach and intestines) and dysentery (diarrhea, abdominal pain, and fever).
Sjögren syndrome (Heinrik S.C. Sjögren, Swedish ophthalmologist, 1899-1986)	Abnormal dryness of the mouth, eyes, and mucous membranes, caused by deficient fluid production. It is a disorder of the immune system.
Snellen test (Herman Snellen, Dutch ophthalmologist, 1834-1908)	Test of visual clarity (acuity) using a special chart. Letters, numbers, or symbols are arranged on the chart in decreasing size from top to bottom.
Tay-Sachs disease (Warren Tay, English ophthalmologist, 1843-1927; Bernard Sachs, American neurologist, 1858-1944)	Inherited disorder of nerve degeneration caused by deficiency of an enzyme. Most affected children die between the ages of 2 and 4 years.
Tourette syndrome (George Gilles de la Tourette, French neurologist, 1857-1927)	Condition marked by abnormal facial grimaces, inappropriate speech, involuntary movements (tics) of eyes, arms, and shoulders.
von Willebrand disease (Erick A. von Willebrand, Finnish physician, 1870-1949)	Inherited blood disorder marked by abnormally slow blood clotting; caused by deficiency in a blood clotting factor (factor VIII).
Weber tuning fork test (Hermann D. Weber, English physician, 1823-1918)	Test of hearing by placing the stem of vibrating tuning fork in the center of the person's forehead.
Whipple procedure (Allen O. Whipple, American surgeon, 1881-1963)	Surgical to remove a portion of the pancreas and the stomach and the entire first part of the small intestine (duodenum). Used in the treatment of pancreatic cancer and other conditions.
Wilms tumor (Max Wilms, German surgeon, 1867-1918)	Malignant tumor of the kidney occurring in young children.

Modified from Chabner D-E: *The Language of Medicine*, ed 11, Philadelphia, 2017, Elsevier.

Modified from Chabner D-E: *The Language of Medicine*, ed 10, Philadelphia, 2014, Elsevier.

APPENDIX 4

Quick Drug Reference

Top 50

Prescribed Medications

Rank	Generic Name	Brand Name	Use
1.	Levothyroxine	Synthroid®	Thyroid hormone to treat low thyroid condition
2.	Hydrocodone/APAP	Vicodin®	Pain relief
3.	Amoxicillin	Amoxil®	Antibiotic; treats bacterial infection
4.	Lisinopril	Prinivil®	Treats high blood pressure; ACE inhibitor
5.	Esomeprazole	Nexium®	Treats acid reflux in treatment of GERD
6.	Atorvastatin	Lipitor®	Lowers cholesterol levels
7.	Simvastatin		Lowers cholesterol levels
8.	Clopidogrel	Plavix®	Antiplatelet; prevents platelets from clumping together and forming blood clots
9.	Montelukast	Singulair®	Reduces wheezing and shortness of breath (asthma attacks)
10.	Rosuvastatin	Crestor®	Lowers cholesterol levels
11.	Metoprolol	Lopressor®	Treats abnormal heart rhythms and high blood pressure; beta blocker
12.	Escitalopram	Lexapro®	Antidepressant
13.	Azithromycin	Zithromax®	Antibiotic; treats bacterial infections
14.	Albuterol	ProAir® HFA	Asthma inhaler
15.	Hydrochlorothiazide HCTZ		Diuretic; increases production of urine (water pill)
16.	Metformin	Glucophage®	Antidiabetic; reduces blood sugar in type 2 diabetes
17.	Sertraline	Zoloft®	Antidepressant
18.	Ibuprofen	Advil®	NSAID; reduces inflammation and pain
19.	Zolpidem	Ambien®	Treats insomnia (difficulty sleeping)
20.	Furosemide	Lasix®	Diuretic; increases production of urine (water pill)
21.	Omeprazole	Prilosec®	Treats acid reflux in treatment of GERD
22.	Trazodone	Desyrel®	Antidepressant
23.	Valsartan	Diovan®	A2RB; treats high blood pressure
24.	Tramadol	Ultram®	Pain relief
25.	Duloxetine	Cymbalta®	Antidepressant
26.	Warfarin	Coumadin®	Blood thinner; treats blood clots (anticoagulant)
27.	Amlodipine	Norvasc®	Calcium channel blocker; treats high blood pressure
28.	Oxycodone/APAP	Percocet®	Pain relief
29.	Quetiapine	Seroquel®	Antipsychotic; treats severe mental disorders
30.	Promethazine	Phenergan®	Antihistamine; treats allergy symptoms
31.	Fluticasone	Flonase®	Nasal spray for allergy relief
32.	Alprazolam	Xanax®	Antianxiety
33.	Clonazepam	Klonopin®	Antianxiety
34.	Benazepril	Lotensin®	Treats high blood pressure; ACE inhibitor
35.	Meloxicam	Mobic®	NSAID; reduces inflammation and pain
36.	Citalopram	Celexa®	Antidepressant
37.	Cephalexin	Keflex®	Antibiotic; treats bacterial infection
38.	Tiotropium	Spiriva®	Inhaler medicine to open airways treats and improve breathing in COPD
39.	Gabapentin	Neurontin®	Treats seizures (epilepsy) and nerve pain
40.	Aripiprazole	Abilify®	Antipsychotic; treats severe mental disorders
41.	Potassium	K-Tab®	Treats low levels of potassium (important electrolyte)
42.	Cyclobenzaprine	Flexeril®	Muscle relaxant
43.	Methylprednisolone	Medrol®	Corticosteroid drug to reduce inflammation
44.	Methylphenidate	Concerta®	Stimulant medication to treat ADHD
45.	Loratadine	Claritin®	Allergy relief
46.	Carvedilol	Coreg®	Treats heart failure (CHF)
47.	Carisoprodol	Soma®	Muscle relaxant
48.	Digoxin	Lanoxin®	Treats heart failure (CHF)
49.	Memantine	Namenda®	Treats Alzheimer disease
50.	Atenolol	Tenormin®	Treats abnormal heart rhythms and high blood pressure; beta blocker

Abbreviations:

A2RB = Angiotensin 2 Receptor Blocker

ACE = Angiotensin-Converting Enzyme

ADHD = Attention-Deficit Hyperactivity Disorder

APAP = Acetaminophen ®

CHF = Congestive Heart Failure

COPD = Chronic Obstructive Pulmonary Disease

GERD = Gastroesophageal Reflux Disease

HCTZ = Hydrochlorothiazide

HFA = Hydrofluoroalkane—type of inhaler

NSAID: Nonsteroidal Anti-inflammatory Drug

Source: from www.pharmacy-tech-test.com/top-200-drugs



APPENDIX 5

Allied Health Careers

Title/Description	Education Requirements	Certification or Licensure Requirements	National Association or Additional Information
<p>Audiologist Works with people who have hearing problems by using testing devices to measure hearing loss.</p>	<p>Clinical doctoral degree—Doctor of Audiology (AuD) graduate degree, including 9 to 12 months of clinical experience.</p>	<p>In addition to complying with state license requirements (which may include requirement for teaching certification for a particular practice setting), ASHA offers Certification of Clinical Competency in Audiology (CCC-A).</p>	<p>American Speech-Language-Hearing Association (ASHA) 1080 Rockville Pike Rockville, MD 20852 800-498-2071 American Academy of Audiology (AAA) 11730 Plaza America Dr., Suite 300 Reston, VA 20190 800-AAA-2336</p>
<p>Blood bank technologist Collects, types, and prepares blood and its components for transfusions and laboratory tests.</p>	<p>Baccalaureate degree in clinical laboratory science or other physical science degree, plus a 12-month program in blood bank technology. Some programs also offer master's degrees.</p>	<p>Certification through Board of Registry of the American Society of Clinical Pathologists (ASCP) (www.ascp.org).</p>	<p>American Association of Blood Banks (AABB) 8101 Glenbrook Road Bethesda, MD 20814 301-215-6482</p>
<p>Chiropractor Treats health problems associated with the muscular, nervous, and skeletal systems, especially the spine.</p>	<p>College degree plus 4 years of resident instruction in a college of chiropractics.</p>	<p>Must pass the National State Board Exam.</p>	<p>American Chiropractic Association (ACA) Public Information Department 1702 Clarendon Blvd. Arlington, VA 22209 703-276-8880</p>
<p>Clinical laboratory technologist (CLT) (also see <i>Medical laboratory technologist</i>) (CLT, CLS, MLT, MLS) Performs tests to examine and analyze body fluids, tissues and cells.</p>	<p>2-year associate's degree or 12-month certificate program.</p>	<p>Certification available through the following: Board of Registry of the American Society for Clinical Pathology, American Medical Technologists Association, the National Credentialing Agency for Laboratory Personnel, and Board of Registry of the American Association of Bioanalysts.</p>	<p>American Medical Technologists Association (AMTA) 710 Higgins Road Park Ridge, IL 60068 847-823-5169</p>
<p>Dental assistant Assists a dentist with dental procedures.</p>	<p>Typically, 9- to 11-month program at a community college, vocational school, or career school. It is also possible to work as a dental assistant without attending a program and learn on the job.</p>	<p>In most states, certification is optional. Person is eligible to take exam if a graduate of an accredited dental assisting program or has 2 years of work experience. Exam for Certified Dental Assistant (CDA) is administered by the American Dental Assistants Association.</p>	<p>American Dental Assistants Association (ADAA) 35 E. Wacker Dr., Suite 1730 Chicago, IL 60601 312-541-1550</p>
<p>Dental hygienist Provides preventive dental care and teaches the practice of good oral hygiene.</p>	<p>2-year associate's degree or 4-year baccalaureate degree.</p>	<p>State requirements vary. In most states, the person must graduate from an accredited dental hygiene program, pass the state-authorized licensure exam, and pass the comprehensive written exam. On passing the exam, the</p>	<p>American Dental Hygienists Association</p>

		dental hygienist becomes a Registered Dental Hygienist (RDH).	(ADHA) 444 N. Michigan Ave., Suite 3400 Chicago, IL 60611 312-440-8900
Dental laboratory technician Prepares materials (crowns, bridges) for use by a dentist.	A 2-year program at a community, vocational, or technical college, either an associate's degree or certificate. The person also can work as a dental laboratory technician with on-the-job training.	In most states, certification to become a Certified Dental Technician (CDT) is optional.	National Board of Certification for Dental Laboratory Technicians (NBCDLT) 1530 Metropolitan Blvd. Tallahassee, FL 32308 850-224-0711
Diagnostic medical sonographer Performs diagnostic ultrasound procedures.	From 1 to 4 years for certificate, associate's degree, or baccalaureate degree.	Optional certification exam through American Registry of Diagnostic Medical Sonographers, with the designation Registered Diagnostic Medical Sonographer (RDMS).	Society of Diagnostic Medical Sonographers (SDMS) 2745 Dallas Pkwy., Suite 350 Plano, TX 75093 214-473-8057
Dietitian/nutritionist Plans nutrition programs and supervises the preparation and serving of meals.	2-year component within a baccalaureate or master's degree program, plus internship of 6 months to 2 years.	National certification exam to become a Certified Registered Dietitian (CRD) through the Commission on Dietetic Registration.	American Dietetic Association (ADA) 120 S. Riverside Plaza, Suite 2000 Chicago, IL 60606 312-899-0400, ext 5500
ECG technician (cardiovascular technician) Operates an electro-cardiograph to record ECGs and for Holter monitoring and stress tests.	Training often done on the job in 8- to 16-week programs. Longer programs are also available.	Optional	Alliance of Cardiovascular Professionals (ACP) P.O. Box 2007 Midlothian, VA 23113 804-632-0078
Emergency medical technician 1. First responder 2. Basic (EMT-B) 3. Intermediate (EMT-I) 4. Paramedic (EMT-P) Gives immediate care and transports sick or injured to medical facilities.	Four levels: <i>First responder:</i> 40 hours <i>EMT Basic:</i> 120 hours <i>EMT Intermediate:</i> 200 to 400 hours <i>EMT Paramedic:</i> 1000+ hours	Administered by the National Registry of Emergency Medical Technicians (NREMT) for each level from EMT-B, EMT-I, and EMT-Paramedic.	National Association of Emergency Medical Technicians (NAEMT) P.O. Box 1400 Clinton, MS 39060 800-34-NAEMT
Health information management professional 1. Health information technician (HIT) 2. Health information administrator (HIA) Designs, manages, and administers the use of health care data and information.	Two levels: <i>Health Information Technician (HIT):</i> 2-year associate's degree <i>Health Information Administrator (HIA):</i> 4-year baccalaureate degree	On completion of the education program, a test is required through the national association (AHIMA) to become a Registered Health Information Technician (RHIT) or Registered Health Information Administrator (RHIA).	American Health Information Management Association (AHIMA) 233 N. Michigan Ave., Suite 2150 Chicago, IL 60601 312-233-1100
Home health aide Cares for elderly, disabled, and ill persons in their own homes, helping them live there instead of in an institution.	Often on-the-job training or technical/career college.	National Association for Home Care & Hospice offers optional certification.	National Association for Home Care & Hospice (NAHCH) (www.nahc.org) 202-547-7424
Licensed practical nurse (LPN) Cares for sick, injured, convalescing, and handicapped	Approximately 1-year program, with 36 to 28 semester hours.	Must pass the National Council Licensure Examination for Practical Nurses (NCLEX-PN).	National Federation for Licensed

persons, under the direct supervision of physicians and registered nurses; provides basic bedside care.			Practical Nurses (NFLPN) 1418 Aversboro Road Garner, NC 27529 919-779-0046
Medical assistant Helps physicians examine and treat patients and performs tasks to keep offices running smoothly.	Associate's degree, certificate, and diploma programs available. Medical assistants can focus on either administrative or clinical duties or both.	Optional certifications available. Exam to become a Certified Medical Assistant (CMA) through the AAMA or a Registered Medical Assistant (RMA) through American Medical Technologists Association (see next entry).	American Association of Medical Assistants (AAMA) 20 N. Wacker Dr., Suite 1575 Chicago, IL 60606 800-228-2262
Medical laboratory technologist (also see <i>Clinical laboratory technologist [CLT]</i>) Performs routine tests and laboratory procedures.	A 2-year associate's degree or a 12-month certificate program.	Certification available through the following: Board of Registry of the American Society for Clinical Pathology, the American Medical Technologists Association, the National Credentialing Agency for Laboratory Personnel, and the Board of Registry of the American Association of Bioanalysts.	American Medical Technologists Association (AMTA) 710 Higgins Road Park Ridge, IL 60068 847-823-5169 American Society of Clinical Laboratory Science (ASCLS) 6701 Democracy Blvd., Suite 300 Bethesda, MD 20817 301-657-2768
Nuclear medicine technologist Performs radioactive tests and procedures under the supervision of a nuclear medicine physician, who interprets the results.	Professional portion of the program is 1-2 years within an associate's or baccalaureate degree program.	On completion of an accredited program, certification exam is available through the Nuclear Medicine Technology Certification Board.	Society of Nuclear Medicine—Technologist Section (SNMTS) 1850 Samuel Morse Dr. Reston, VA 22090 703-708-9000 American Society of Radiologic Technologists (ASRT) 1500 Central Ave. SE Albuquerque, NM 87123
Nurse anesthetist Aids in the delivery of anesthesia during surgery.	RN with baccalaureate degree plus 24-month anesthesiology training course (leading to a master's degree).	Required exam by the Council on Certification for Nurse Anesthetists, to become a Certified Registered Nurse Anesthetist (CRNA).	Association of Nurse Anesthetists (ANA) 222 S. Prospect Ave. Park Ridge, IL 60068 847-692-7050 Additional information: National League of Nursing
Nursing aide (nursing assistant, orderly, hospital attendant) Helps care for physically or mentally ill, injured, or disabled patients confined to nursing, hospital, or residential care	Often on-the-job training or technical/career college.	Optional certification is available through state nursing registries for Certified Nursing Assistant (CNA).	National Association of Health Care Assistants (NAHCA) 1201 L St.

facilities; also known as nursing assistants or hospital attendants.			Washington, DC 20005 202-454-1288
Occupational therapist (OT) Helps people with mentally, physically, developmentally, or emotionally disabling conditions to develop, recover, or maintain daily living and working skills.	Two levels: <i>Baccalaureate degree:</i> 4-5 year program <i>Masters degree:</i> additional 2.5 years	National certification exam through National Board for Certification of Occupational Therapy (NBCOT). All states also regulate occupational therapists. Upon passing the exam, the occupational therapist becomes an Occupational Therapist Registered (OTR).	American Occupational Therapy Association (AOTA) 4720 Montgomery Lane P.O. Box 31220 Bethesda, MD 20824 301-652-2682
Occupational therapy assistant (OTA) Under the direction of an occupational therapist, the OTA works with patients to restore or enhance activities of daily living.	2-year associate's degree or 1-year certificate program.	National certification exam for OTA administered by: National Board for Certification of Occupational Therapy (NBCOT). Many states also regulate occupational therapy assistants.	American Occupational Therapy Association (AOTA) 4720 Montgomery Lane P.O. Box 31220 Bethesda, MD 20824 301-652-2682
Ophthalmic professional 1. Ophthalmic assistant 2. Ophthalmic technician/technologist Helps ophthalmologists provide medical eye care.	Two levels: <i>Assistant:</i> less than 1 year <i>Technician/technologist:</i> 1-2 years	After 1 year on the job, the person may test to become a Certified Ophthalmic Medical Assistant (COMA) through the Joint Commission on Allied Health Professionals in Ophthalmology (JCAHPO).	Association of Technical Personnel in Ophthalmology (ATPO) 2025 Woodland Dr. St. Paul, MN 55125 651-731-7233
Pharmacy technician Under the direction of licensed pharmacists, dispenses, distributes, and administers medications prescribed.	Usually 15 weeks (minimum 600 hours) of training required; can be on the job or through a career, technical, or community college.	Optional through the AAPT and Pharmacy Technician Certification Board, to become a Certified Pharmacy Technician (CPhT).	American Association of Pharmacy Technologists (AAPT) P.O. Box 1447 Greensboro, NC 27402 877-368-4771
Phlebotomist Draws and tests blood under the supervision of a medical technologist or laboratory manager.	Minimum 100 hours of clinical instruction.	Optional certification available through the following: American Medical Technologists Association, National Credentialing Agency for Laboratory Personnel, and Board of Registry of the American Association of Bioanalysts.	American Medical Technologists Association (AMTA) 710 Higgins Road Park Ridge, IL 60068 847-823-5169 American Society of Phlebotomy Technicians (ASPT) P.O. Box 1831 Hickory, NC 28603 828-294-0078 National Phlebotomy Association (NPA) 1901 Brightseat Road Landover, MD 20785 301-386-4200
Physical therapist (PT) Improves mobility, relieves pain, and prevents or limits permanent	Most programs are doctoral degree programs granting a doctorate in physical therapy (DPT); a few	On completion of accredited program, national exam is required. Other requirements vary by state.	American Physical Therapy

physical disabilities of patients experiencing injuries or disease.	master's degree programs are still offered.		Association (APTA) 111 North Fairfax St. Alexandria, VA 22314 703-684-2782
Physical therapy assistant (PTA) Under the direction of a physical therapist, works with patients to improve mobility.	Most programs are associate's degree programs, 1 year of which is for technical courses and clinical experience.	Most states require physical therapy assistants to be licensed, registered, or certified.	American Physical Therapy Association (APTA) 111 North Fairfax St. Alexandria, VA 22314 703-684-2782
Physician assistant (PA) Examines, diagnoses, and treats patients under the direct supervision of a physician.	Varies, but commonly a 25- to 27-month program in addition to at least 2 years of undergraduate study.	All states require passage of national exam through National Commission on Certification of Physician Assistants (NCCPA). To practice, PAs must also meet any additional state criteria and have a sponsoring physician.	American Association of Physician Assistants (AAPA) 950 N. Washington St. Alexandria, VA 22314 703-836-2272 National Commission on Certification of Physician Assistants (NCCPA) 12000 Findley Road, Suite 200 Duluth, GA 30097 678-417-8100
Radiation therapist Prepares cancer patients for treatment and examinations, and administers medications (this career is a specialty within imaging technology—see next entry).	After becoming a radiographer, 1 to 2 years of training.	Certification through American Registry of Radiologic Technologists (ARRT).	American Society of Radiologic Technologists (ASRT) 1500 Central Ave. SE Albuquerque, NM 87123 505-298-4500 American Registry of Radiologic Technologists (ARRT) 1255 Northland Dr. Mendota Heights, MN 55120 651-687-0048
Radiographer/radiologic technologist Produces x-ray images of parts of the body for use in diagnosing medical problems.	2- to 4-year training program resulting in degree or certificate.	Certification through American Registry of Radiologic Technologists (ARRT).	American Society of Radiologic Technologists (ASRT) 1500 Central Ave. SE Albuquerque, NM 87123 505-298-4500 American Registry of Radiologic Technologists (ARRT) 1255 Northland Dr. Mendota

			Heights, MN 55120 651-687-0048
Registered nurse (RN) Cares for sick and injured people by assessing and recording symptoms, assisting physicians during treatments and examinations, and administering medications.	ADN—community college or technical school, 2 years Diploma—hospital-based, often 3 years BSN—baccalaureate degree program, 4 years	All registered nurses must pass the NCLEX-RN, administered by the National Council of Licensure Examinations for RN.	American Nursing Association (ANA) 600 Maryland Ave. SW, Suite 100 Washington, DC 20024 800-274-4ANA National League of Nursing (NLN) 61 Broadway, 33rd Floor New York, NY 10006 212-363-5555
Respiratory therapist Evaluates, treats, and cares for patients with breathing disorders.	<i>Entry level:</i> 2-year associate's degree program. <i>Advanced level:</i> 2- to 4-year program with baccalaureate or graduate degree.	Certification through National Board for Respiratory Care for Certified Respiratory Therapist (CRT).	American Association for Respiratory Care (AARC) 11030 Ables Lane Dallas, TX 75229 972-243-2272
Speech-language pathologist Assesses and treats persons with speech, language, voice, and fluency disorders.	2-year master's degree plus typically 9 to 12 months of clinical experience.	49 states require compliance with state licensure standards and/or a teacher certification. Exam administered by ASHA for Certification of Clinical Competency in Speech-Language Pathology (CCC-SLP).	American Speech-Language-Hearing Association (ASHA) 1080 Rockville Pike Rockville, MD 20852 800-498-2071
Surgical technologist (CST) Assists in operations under the supervision of surgeons or registered nurses.	12- to 24-month associate's degree or certificate program.	Optional certification exam through National Board for Surgical Technologists and Surgical Assistants for Certified Surgical Technician (CST).	Association of Surgical Technologists (AST) 6 West Dry Creek Circle Littleton, CO 80120 800-637-7433

GLOSSARY 1

Mini-Dictionary

Pronunciation of each term is given with its meaning. The syllable that gets the accent is in CAPITAL LETTERS. Terms in SMALL CAPITAL LETTERS are defined elsewhere in this glossary.

A

Abdomen (AB-do-men): Space below the chest that contains organs such as the stomach, liver, intestines, and gallbladder. The abdomen lies between the diaphragm and the pelvis.

Abdominal (ab-DOM-ih-nal): Pertaining to the abdomen.

Abdominal cavity (ab-DOM-ih-nal KAV-ih-te): See [ABDOMEN](#).

Ablation (ab-LA-shun): Removal of abnormal tissue by surgical or mechanical means.

Abnormal (ab-NOR-mal): Pertaining to being away (AB-) from the norm; irregular.

Acquired immunodeficiency syndrome (ah-KWYRD im-u-no-deh-FISH-en-se SIN-droh) or AIDS: Suppression or deficiency of the immune response caused by exposure to the HUMAN IMMUNODEFICIENCY VIRUS (HIV).

Acromegaly (ak-ro-MEG-ah-le): Enlargement of extremities as a result of thickening of the bones and soft tissues; it is caused by excessive secretion of growth hormone from the pituitary gland (after completion of puberty).

Acute (uh-KYOOT): Sharp, sudden, and intense for a short period of time.

Acute myocardial ischemia (ah-KUT mi-o-KAR-de-al is-KE-me-ah): Sudden decrease in blood flow to the heart muscle.

Adenectomy (ad-eh-NEK-to-me): Removal of a gland.

Adenitis (ad-eh-NI-tis): Inflammation of a gland.

Adenocarcinoma (ah-deh-no-kar-sih-NO-mah): Cancerous tumor derived from glandular cells.

Adenoidectomy (ah-deh-noyd-EK-to-me): Removal of the adenoids.

Adenoids (AD-eh-noydz): Lymphatic tissue in the upper part of the throat near the nasal passageways.

Adenoma (ah-deh-NO-mah): Tumor (benign) of a gland. Benign means not cancerous.

Adenopathy (ah-deh-NOP-ah-the): Disease of glands. Often this term refers to enlargement of lymph nodes (which are not true glands, but collections of lymphatic tissue).

Adnexa uteri (ad-NEKS-ah U-ter-i): Accessory structures of the uterus (ovaries and fallopian tubes).

Adrenal cortex (ah-DRE-nal KOR-teks): Outermost part of the adrenal gland. The adrenal cortex secretes steroid hormones such as GLUCOCORTICOIDS (cortisone).

Adrenal glands (ah-DRE-nal glanz): Two endocrine glands, each above a kidney. The adrenal glands produce hormones such as adrenaline (epinephrine) and hydrocortisone (cortisol).

Adrenalectomy (ah-dre-nal-EK-to-me): Removal (excision) of adrenal glands.

Adrenaline (ah-DREN-ah-lin): Hormone secreted by the adrenal glands. It is released into the bloodstream in response to stress, such as from fear or physical injury. Also called EPINEPHRINE.

Adrenocorticotrophic hormone (ah-dre-no-kor-tih-ko-TROP-ic HOR-mone): Hormone secreted by the pituitary gland. It stimulates the adrenal gland (cortex or outer region) to secrete the hormone cortisone. Also called ACTH.

Adrenopathy (ah-dreh-NOP-a-the): Disease of ADRENAL GLANDS.

AIDS: See [ACQUIRED IMMUNODEFICIENCY SYNDROME](#).

Air sacs (ayr saks): Thin-walled sacs within the lung. Inhaled oxygen passes into the blood from the sacs, and carbon dioxide passes out from the blood into the sacs to be exhaled; ALVEOLI.

Albumin (al-BU-min): A large-molecule protein found in blood and tissues.

Albuminuria (al-bu-min-U-re-ah): Albumin (protein) in the urine; it indicates a malfunction of the kidney.

Alkaline phosphatase (AL-kah-line PHOS-fah-tays): An enzyme present in blood and body tissues, such as bone and liver. Elevated in diseases such as those of bone and liver. Also called alk phos.

Allergist (AL-er-jist): Medical doctor specializing in identifying and treating abnormal sensitivity to substances such as pollen, dust, foods, and drugs.

Alopecia (ah-lo-PE-shah): Loss of hair; baldness.

ALT: Alanine transferase, an enzyme normally found in blood and tissues, especially the liver. ALT is elevated in liver disease. (Formerly called SGPT.)

Alveolar (al-VE-o-lar): Pertaining to air sacs (alveoli) within the lungs.

Alveoli (al-VE-o-li): Thin-walled sacs within the lung. Inhaled oxygen passes into the blood from the sacs, and carbon dioxide passes out from the blood into the sacs to be exhaled (*singular:* ALVEOLUS).

Alveolus (al-ve-O-lus): An air sac within the lung (*plural:* ALVEOLI).

Alzheimer disease (ALTZ-hi-mer di-ZEEZ): Deterioration of mental capacity (irreversible dementia) marked by intellectual deterioration, disorganization of personality, and difficulties in carrying out tasks of daily living.

Amenorrhea (a-men-o-RE-ah): Absence of menstrual flow.

Amniocentesis (am-ne-o-sen-TE-sis): Surgical puncture to remove fluid from the amnion (sac surrounding the developing fetus).

Anal (A-nal): Pertaining to the anus (opening of the rectum to the outside of the body).

Analgesic (an-al-JE-zik): Medication that reduces or eliminates pain.

Analysis (ah-NAL-ih-sis): Separating a substance into its component parts.

Anastomosis (ah-nah-sto-MO-sis): New surgical connection between two previously unconnected bowel parts, vessels, or ducts.

Androgen (AN-dro-jen): Hormone that controls the development of masculine characteristics. An example is TESTOSTERONE.

Anemia (ah-NE-me-ah): Deficiency of hemoglobin and/or in number of red blood cells. This results in reduced delivery of oxygen to body cells. Literally, *anemia* means lacking (AN-) in blood (-EMIA).

Anemic (ah-NE-mik): Pertaining to ANEMIA.

Anesthesiologist (an-es-the-ze-OL-o-jist): Medical doctor specializing in administering agents capable of bringing about loss of sensation and consciousness.

Anesthesiology (an-es-the-ze-OL-o-je): Study of how to administer agents capable of bringing about loss of sensation and consciousness.

Aneurysm (AN-u-rizm): Localized widening of the wall of an artery, of a vein, or of the heart. From the Greek *aneurysma*, meaning "widening."

Angina (an-JI-nah): Sharp pain in the chest resulting from a decrease in blood supply to heart muscle. Also called angina pectoris (PECT/O means chest).

Angiography (an-je-OG-rah-fe): X-ray recording of blood vessels after contrast is injected.

Angioplasty (AN-je-o-plas-te): Surgical repair of a blood vessel. A tube (catheter) is placed in a clogged artery and a balloon at the end of the tube is inflated to flatten the clogged material against the wall of the artery. This enlarges the opening of the artery so that more blood can pass through. Also called balloon angioplasty.

Angiotensin (an-je-o-TEN-sin): Hormone that is a powerful vasoconstrictor and raises blood

pressure.

Ankylosing spondylitis (ang-kih-LO-sing spon-dih-LI-tis): Chronic inflammation of the vertebrae (backbones) with stiffening of spinal and hip joint so that movement becomes increasingly painful.

Ankylosis (ang-kih-LO-sis): Stiffening and immobility of a joint caused by injury, disease, or a surgical procedure.

Anomaly (ah-NOM-ah-le): Irregularity; a deviation from the normal. A congenital anomaly (irregularity) is present at birth.

Antenatal (an-teh-NA-tal): Before birth.

Antepartum (an-teh-PAR-tum): Before birth.

Anterior (an-TE-re-or): Located in the front (of the body or of a structure).

Antiandrogen (an-tih-AN-dro-jen): Substance that inhibits the effects of androgens (male hormones).

Antiarrhythmic (an-te-ah-RITH-mik): Pertaining to a drug that works against or prevents abnormal heartbeats (arrhythmias).

Antibiotic (an-tih-bi-OT-ik): A chemical substance produced by various microorganisms or fungi (immature plants) that inhibits or destroys bacteria or other small organisms. Examples of antibiotics are penicillin and streptomycin. They are used in the treatment of infectious diseases.

Antibody (AN-tih-bod-e): A substance that works against (ANTI-) germs ("bodies" of infection). Antibodies are produced by white blood cells when germs (antigens) enter the bloodstream.

Anticoagulant (an-tih-ko-AG-u-lant): Drug that prevents clotting (coagulation). Anticoagulants are given when there is danger of clot formation in blood vessels, as may happen after a heart attack.

Anticonvulsant (an-tih-kon-VUL-sant and an-tih-de-PRE-sant): Drug that prevents or relieves convulsions (involuntary muscular contractions).

Antidepressant (an-tih-de-PRES-ant): Drug used to prevent or treat depression.

Antidiabetic (an-tih-di-ah-BET-ik): Drug that prevents or relieves symptoms of diabetes.

Antiestrogen (an-tih-ES-tro-jen): Substance that inhibits the effects of estrogens (female hormones).

Antifungal (an-tih-FUNG-al): Drug that destroys or inhibits the growth of fungi (organisms such as yeasts, molds, and mushrooms).

Antigen (AN-tih-jen): Foreign protein (such as on a bacterium or virus) that stimulates white blood cells to make antibodies. Antigens are then destroyed by the antibodies.

Antihistamine (an-tih-HIS-tah-meen): Drug used to counteract the effects of histamine production in allergic reactions and colds.

Antihypertensive (an-te-hi-per-TEN-siv): Drug that reduces high blood pressure.

Antitubercular (an-tih-too-BER-ku-lar): Agent or drug used to treat tuberculosis.

Antiviral (an-tih-VI-ral): Agent that inhibits and prevents the growth and reproduction of viruses.

Anuria (an-U-re-ah): Abnormal condition of no urine production.

Anus (A-nus): Opening of the rectum to the surface of the body; solid wastes (feces) leave the body through the anus.

Aorta (a-OR-tah): Largest artery that leads from the lower left chamber of the heart to arteries all over the body.

Aortic stenosis (a-OR-tik steh-NO-sis): Narrowing of the aorta.

Apex (A-peks): Pointed end of an organ (*plural*: apices [A-pih-seez]).

Aphakia (ah-FA-ke-ah): Absence of the lens of the eye.

Aphasia (ah-FA-ze-ah): Absence or impairment of communication through speech.

Apnea (AP-ne-ah): Not (A-) able to breathe (-PNEA); temporary stoppage of breathing. In sleep apnea, during sleep, a person is momentarily unable to contract respiratory muscles and maintain air flow through the nose and mouth.

Appendectomy (ap-en-DEK-to-me): Removal of the appendix.

Appendicitis (ap-en-dih-SI-tis): Inflammation of the appendix.

Appendix (ah-PEN-dikz): Small sac that hangs from the juncture of the small and large intestines in the right lower quadrant of the abdomen. Its function is unknown.

Arachnoid membrane (ah-RAK-noyd MEM-brayn): The middle membrane of the MENINGES (coverings around the brain and spinal cord).

Areola (ah-RE-o-lah): Dark, pigmented area around the nipple of the breast.

Arrhythmia (a-RITH-me-ah): Abnormal heart rhythm.

Arteriography (ar-teer-e-OG-rah-fe): Process of recording (x-ray) of arteries after injecting contrast material.

Arteriole (ar-TEER-e-ole): Small artery.

Arteriolitis (ar-teer-e-o-LI-tis): Inflammation of small arteries (arterioles).

Arteriosclerosis (ar-teer-e-o-skleh-RO-sis): Hardening of arteries. The most common form is *atherosclerosis*, which is hardening of arteries caused by collection of fatty, cholesterol-like deposits (plaque) in arteries.

Arteriovenous fistula (ar-teer-e-o-VE-nus FIST-u-lah): An abnormal communication between an artery and a vein. It can also be created surgically to provide access for hemodialysis.

Artery (AR-ter-e): Largest (in diameter) blood vessel. Arteries carry blood away from the heart.

Arthralgia (ar-THRAL-jah): Pain in a joint.

Arthritis (ar-THRI-tis): Inflammation of a joint.

Arthrocentesis (ar-thro-sen-TE-sis): Surgical puncture to remove fluid from a joint for diagnosis or treatment.

Arthrogram (AR-thro-gram): X-ray record of a joint.

Arthropathy (ar-THROP-ah-the): Disease of joints.

Arthroplasty (AR-thro-plas-te): Surgical repair of a joint, especially to restore mobility in osteoarthritis or rheumatoid arthritis.

Arthroscope (AR-thro-skope): Instrument used to examine (inside of) a joint.

Arthroscopy (ar-THROS-ko-pe): Process of visual examination of a joint.

Arthrosis (ar-THRO-sis): Abnormal condition of a joint.

Ascites (ah-SI-teez): Abnormal collection of fluid in the abdomen.

Asphyxia (as-FIK-se-ah): Deficiency of oxygen in the blood and increase in carbon dioxide in blood and tissues. Major sign is a complete absence of breathing, leading to loss of consciousness or death.

Aspiration (as-per-A-shun): Withdrawal of fluid from a cavity or sac.

AST: Aspartate transferase, an enzyme normally present in blood and tissues such as heart and liver. (Formerly called SGOT.)

Asthma (AZ-mah): Difficult breathing caused by a spasm of the bronchial tubes or a swelling of their mucous membrane lining.

Atelectasis (ah-teh-LEK-tah-sis): Collapsed lung or part of a lung (ATEL-, meaning incomplete; -ECTASIS, meaning widening or dilation).

Atherosclerosis (ah-theh-ro-skle-RO-sis): See [ARTERIOSCLEROSIS](#).

Atrium (A-tre-um): Upper chamber of the heart (*plural*: atria).

Atrophy (AT-ro-fe): Decrease in size of cells within an organ.

Auditory canal (AW-dih-tor-e kah-NAL): Passageway leading into the ear from the outside of the body.

Auditory nerve (AW-dih-tor-e nurv): Nerve that transmits sound waves from the inner ear to the brain, making hearing possible.

Aura (AW-rah): A strange sensation coming before more definite symptoms of illness. An aura often precedes a migraine headache or an epileptic seizure, warning the patient that an attack is beginning.

Aural discharge (AW-rah! DIS-charj): Fluid or material that is expelled from the ear.

Autopsy (AW-top-se): Examination of a dead body to determine the cause of death. Also called a POSTMORTEM exam or NECROPSY. Literally, it means “to see” (-OPSY) with “one’s own” (AUT-) eyes.

Axial (AKS-e-al): Pertaining to an axis (an imaginary line through the center of a body or about which a structure revolves). Axial (transverse plane) views are seen in CT and MRI scans.

Axillary (AKS-ih-lar-e): Pertaining to the armpit or underarm.

B

Bactericidal (bak-tih-re-SI-dal): Pertaining to an agent that destroys bacteria.

Bacteriostatic (bak-tih-re-o-STAT-ik): Pertaining to an agent that inhibits bacterial growth.

Bacterium (bak-TIH-re-um): Type of one-celled organism whose genetic material (DNA) is not organized within a nucleus (*plural*: bacteria).

Balanitis (bah-lah-NI-tis): Inflammation of the penis.

Bariatric surgery (bah-re-AH-trik SUR-jer-e): Surgery on part of the gastrointestinal tract for obesity. BARI/O means weight, and IATR/O means treatment.

Barium (BAH-re-um): Substance used as a radiopaque (x-rays cannot pass through it) contrast medium for x-ray examination of the digestive tract.

Barium enema (BAH-re-um EN-eh-mah): X-ray study of the lower digestive tract performed by instilling a solution of barium into the rectum, which highlights structures seen on the x-ray images.

Barium swallow (BAH-re-um SWAH-lo): X-ray study of the upper digestive tract performed by having the patient swallow a solution of barium, which highlights structures seen on the x-ray images.

Benign (be-NIN): Not cancerous; a tumor that does not spread and is limited in growth. Benign is the opposite of malignant.

Benign prostatic hyperplasia (be-NIN pro-STAH-tik hi-per-PLA-ze-ah): Nonmalignant enlargement of the prostate gland. Also called benign prostatic hypertrophy (hi-PER-tro-fe).

Benzodiazepine (ben-zo-di-AZ-eh-pin): Drug used to relieve anxiety, relax muscles, and produce sedation.

Beta blocker (BA-tah BLOK-er): Drug that is used for the treatment of high blood pressure (hypertension), chest pain (angina), and abnormal rhythms of the heart (arrhythmias).

Bilateral (bi-LAT-er-al): Pertaining to two (both) sides.

Bile (bil): A yellow or orange fluid produced by the liver. It breaks up large fat globules and helps in the digestion of fats.

Bile duct (bil dukt): Tube that carries bile from the liver and gallbladder to the intestine.

Bilirubin (bil-ih-RU-bin): A red blood cell pigment excreted with bile from the liver into the intestine.

Biology (bi-OL-o-je): Study of life.

Biopsy (BI-op-se): Living tissue is removed and viewed under a microscope. In a *core (needle) biopsy*, a small sample of tissue is removed using a hollow needle. It is typically performed under imaging guidance such as ULTRASOUND or CT SCAN.

Bladder (BLAH-der): See [URINARY BLADDER](#).

Bone (bone): Hard, rigid type of connective tissue that makes up most of the skeleton. It is composed of calcium salts.

Bone marrow (bone MAH-ro): Soft, sponge-like material in the inner part of bones. Blood cells are

made in the bone marrow.

Bones of the middle ear: Three small bones (ossicles) that transmit sound vibrations to the inner ear; malleus, incus, and stapes.

Bradycardia (bra-de-KAR-de-ah): Slow heartbeat.

Brain (brayn): Organ in the head that controls the activities of the body.

Breast (brest): One of two glandular organs on the front of the chest. The breasts produce milk after childbirth.

Bronchial tube (BRONG-ke-al toob): One of two tubes that carry air from the windpipe to the lungs. Also called a bronchus (*plural*: bronchi).

Bronchiole (BRONG-ke-ol): Small bronchial tube.

Bronchiolitis (brong-ke-o-LI-tis): Inflammation of bronchioles.

Bronchitis (brong-KI-tis): Inflammation of bronchial tubes.

Bronchoscope (BRONG-ko-skope): Instrument used to visually examine bronchial tubes.

Bronchoscopy (brong-KOS-ko-pe): Visual examination of bronchial tubes by passing an endoscope through the trachea (windpipe) into the bronchi.

Bronchus (BRONG-kus): See [BRONCHIAL TUBE](#).

Bursa (BUR-sah): Sac of fluid near a joint (*plural*: bursae [BUR-se]).

Bursitis (bur-SI-tis): Inflammation of a bursa.

C

Calcaneus (kal-KA-ne-us): Heel bone.

Calcification (cal-sih-fih-KA-shun): Accumulation of calcium salts in tissues.

Calcium channel blocker (KAL-se-um CHAH-nel BLOK-er): Drug that dilates arteries by inhibiting the flow of calcium into muscle cells that line arteries. It is used to treat hypertension (high blood pressure) and angina (chest pain caused by insufficient oxygen to heart muscle).

Calculus (KAL-ku-lus): Stone (*plural*: calculi [KAL-ku-li]).

Callus (KAL-us): Bony deposit formed between and around the broken ends of a fractured bone. Also, a painless thickening of skin cells in areas of external pressure or friction.

Capillary (KAP-ih-lar-e): Smallest blood vessel (*plural*: capillaries).

Carbon dioxide (KAR-bon di-OK-side): Odorless, colorless gas formed in tissues and eliminated by the lungs.

Carcinoma (kar-sih-NO-mah): Cancerous tumor. Carcinomas form from epithelial cells that line the internal organs and cover the outside of the body.

Cardiac (KAR-de-ak): Pertaining to the heart.

Cardiac catheter ablation (KAR-de-ak KAH-theh-ter ab-LA-shun): Procedure to correct an [ARRHYTHMIA](#) by advancing a flexible tube (catheter) through blood vessels into the heart. High-frequency electrical impulses then destroy the abnormal tissue that is causing the arrhythmia.

Cardiologist (kar-de-OL-o-jist): Physician specializing in the study of the heart and heart disease.

Cardiology (kar-de-OL-o-je): Study of the heart.

Cardiomegaly (kar-de-o-MEG-ah-le): Enlargement of the heart.

Cardiomyopathy (kar-de-o-mi-OP-ah-the): Disease of heart muscle.

Cardiovascular surgeon (kar-de-o-VAS-ku-lar SUR-jun): Specialist in operating on the heart and blood vessels.

Cardioversion (KAR-de-o-ver-zhun): Brief discharges of electricity passing across the chest to stop a cardiac [ARRHYTHMIA](#). Also called [DEFIBRILLATION](#).

Carpals (KAR-palz): Wrist bones.

Carpal tunnel syndrome (KAR-pal TUN-el SYN-droh-m): Group of symptoms resulting from

compression of the median nerve in the wrist. Symptoms include tingling, pain, and burning sensations in the hand and wrist.

Cartilage (KAR-tih-laj): Flexible, fibrous connective tissue, found as part of the nose, ears, voice box, and windpipe and chiefly attached to bones at joints.

Cataract (KAT-ah-rakt): Clouding of the lens of the eye.

Cathartic (ka-THAR-tik): Pertaining to a substance that causes the release of feces from the large intestine.

Catheter (KATH-eh-ter): Flexible or rigid hollow tube used to drain fluids from the body or inject fluids into the body. Catheters are also used to help keep passageways open.

CAT scan (kat skan): Computerized axial tomography. See [CT SCAN](#).

Cauda equina (KAW-dah eh-KWI-nah): Bundle of nerve fibers and nerve roots extending from the end of the spinal cord (L3) to the sacral and coccygeal nerves. *Cauda equina* is Latin for "horse's tail," which describes its appearance.

Caudal (KAW-dal): Pertaining to the tail or the lower portion of the body.

Cauterization (kaw-tur-e-ZA-shun): Heat is used to destroy abnormal tissue, for example, in the lining of the cervix (lower neck-like region of the uterus).

Cautery (KAW-tur-e): Instrument or agent used to destroy tissue by burning.

Cell (sel): Smallest unit or part of an organ.

Cellulitis (sel-u-LI-tis): Inflammation of soft tissue under the skin; it is marked by swelling, redness, and pain, and is caused by bacterial infection.

Cephalgia (seh-FAL-jah): Headache. Shortened form of *cephalalgia*.

Cephalic (seh-FAL-ik): Pertaining to the head. *Cephalic presentation* refers to a fetal position in which the head of the fetus appears at the uterine cervix as the infant is born.

Cephalosporin (sef-ah-lo-SPOR-in): Antibiotic similar to penicillin and used to treat infections of the respiratory tract, ear, urinary tract, bones, and blood.

Cerebellar (ser-eh-BEL-ar): Pertaining to the CEREBELLUM.

Cerebellum (ser-eh-BEL-um): Lower, back part of the brain that coordinates muscle movement and balance.

Cerebral (seh-RE-bral or SER-eh-bral): Pertaining to the CEREBRUM.

Cerebrospinal fluid (seh-RE-bro SPI-nal FLOO-id): Fluid surrounding the brain and spinal cord.

Cerebrovascular accident (seh-re-bro-VAS-ku-lar AK-sih-dent): Blood is prevented from reaching areas of the cerebrum, and brain cells die; also called a STROKE.

Cerebrum (seh-RE-brum): Largest part of the brain. It controls thought processes, hearing, speech, vision, and body movements.

Cervical (SER-vih-kal): Pertaining to the neck of the body or the neck (cervix) of the uterus.

Cervical region (SER-vih-kal RE-jun): Seven backbones in the area of the neck.

Cervical vertebra (SER-vih-kal VER-teh-brah): Backbone in the neck.

Cervix (SER-viks): Lower, neck-like portion of the uterus opening into the vagina.

Cesarean section (seh-ZAR-re-an SEK-shun): Incision of the uterus to remove the fetus at birth.

Chlamydial infection (klah-MID-e-al in-FEK-shun): A bacterial infection commonly transmitted by sexual contact.

Chemotherapy (ke-mo-THER-ah-pe): Treatment with drugs. Chemotherapy is most often used in the treatment of cancer.

Cholecystectomy (ko-leh-sis-TEK-to-me): Removal of the gallbladder.

Choledochoduodenostomy (ko-led-oh-ko-doo-o-deh-NOS-to-me): New surgical attachment of the common bile duct to the duodenum; an anastomosis.

Choledochotomy (ko-led-o-KOT-o-me): Incision of the common bile duct.

Cholelithiasis (ko-leh-lih-THI-ah-sis): Abnormal condition of gallstones.

Cholesterol (ko-LES-ter-ol): Fatty substance made in the liver and found in the bloodstream. It is an important part of all cells and is necessary for creating hormones. It may accumulate in the lining of arteries, such as in the heart, causing heart disease, or in the gallbladder to form gallstones. Normal adult levels are 120 to 200 mg/dL.

Chondroma (kon-DRO-mah): Benign tumor of CARTILAGE.

Chondrosarcoma (kon-dro-sar-KO-mah): Malignant tumor of CARTILAGE.

Chronic (KRON-ik): Lasting a long time.

Chronic obstructive pulmonary disease (KRON-ik ob-STRUK-tiv PUL-mo-na-re dih-ZEEZ): Chronic limitation in airflow into and out of the body; includes chronic bronchitis, ASTHMA, and EMPHYSEMA. Also called COPD.

Circulatory system (SER-ku-lah-tor-e SIS-tem): Organs (heart and blood vessels) that carry blood throughout the body.

Cirrhosis (seh-RO-sis): Liver disease with deterioration of the liver cells. Cirrhosis is often caused by alcoholism and poor nutrition.

Clavicle (KLAV-ih-kul): Collarbone.

Clinical (KLIN-ih-kal): Pertaining to the bedside or clinic; involving patient care.

Coccygeal (kok-sih-JE-al): Pertaining to the tailbone (coccyx).

Coccygeal region (kok-sih-JE-al RE-jun): Four fused (joined-together) bones at the base of the spinal column (backbone).

Coccyx (KOK-siks): Tailbone.

Cochlear (KO-kle-er): Pertaining to the spiral-shaped cavity (cochlea) of the inner ear that transmits sound vibrations to the auditory nerve.

Colectomy (ko-LEK-to-me): Removal of the colon (large intestine).

Colitis (ko-LI-tis): Inflammation of the colon (large intestine).

Colocolostomy (ko-lo-ko-LOS-to-me): New surgical connection between two previously unconnected portions of the colon. This is an anastomosis.

Colon (KO-lon): Large intestine (bowel).

Colonic polyposis (ko-LON-ik pol-ih-PO-sis): Condition of growths or masses protruding from the mucous membrane lining the colon.

Colonoscopy (ko-lon-OS-ko-pe): Visual examination of the colon.

Colorectal surgeon (ko-lo-REK-tal SUR-jun): Physician specializing in operating on the colon and rectum.

Colostomy (ko-LOS-to-me): Opening of the colon to the outside of the body.

Colposcopy (kol-POS-ko-pe): Visual examination of the vagina and cervix.

Computed tomography scan (kom-PU-ted to-MOG-rah-fe skan): X-ray images taken to show the body in cross-sectional views. Also called CT SCAN.

Concussion (kon-KUSH-un): Traumatic brain injury that can cause bruising, damage to blood vessels, and injury to nerves. Loss of consciousness may result.

Congenital anomaly (con-JEN-ih-tal ah-NOM-ah-le): See [ANOMALY](#).

Congestive heart failure (kon-JES-tiv hart FAIL-ur): Condition in which the heart is unable to pump its required amount of blood, resulting in inadequate oxygen to body cells.

Conization (ko-nih-ZA-shun): Removal of a wedge-shaped piece (cone) of tissue from the cervix for biopsy in the diagnosis and treatment of early cervical cancer.

Conjunctiva (kon-junk-TI-vah): Thin protective membrane over the front of the eye and attached to the eyelids.

Conjunctivitis (kon-junk-ti-VI-tis): Inflammation of the CONJUNCTIVA.

Connective tissue (kon-NEK-tiv TIS-u): Fibrous tissue that supports and connects internal organs, bones, and walls of blood vessels.

Contraindication (kon-tra-in-dih-KA-shun): Specific situation in which a drug, procedure, or surgery should not be used because it may be harmful to the patient.

Contralateral (kon-tra-LAT-er-al): Pertaining to the opposite side.

Core biopsy (kor BI-op-se): See [BIOPSY](#).

Corium (KOR-e-um): Middle layer of the skin below the epidermis; DERMIS.

Cornea (KOR-ne-ah): Transparent layer over the front of the eye. It bends light to focus it on sensitive cells (retina) at the back of the eye.

Coronal plane (kor-O-nal playn): See [FRONTAL PLANE](#).

Coronary (KOR-on-ayr-e): Pertaining to the heart.

Coronary angiogram (KOR-on-ayr-e AN-je-o-gram): X-ray record of blood vessels surrounding the heart.

Coronary arteries (KOR-on-ayr-e AR-ter-eez): Blood vessels that carry oxygen-rich blood from the aorta to the heart muscle.

Coroner (KOR-oh-ner): A person who determines the cause of death in cases where the death was sudden, unexpected, of suspicious origin, or while under police custody. Generally, coroners have legal and/or medical backgrounds.

Cortex (KOR-teks): Outer part of an organ (*plural: cortices* [KOR-tih-seez]).

Cortisol (KOR-tih-sol): Anti-inflammatory hormone secreted by the adrenal cortex.

Costochondritis (kos-to-kon-DRI-tis): Inflammation of the cartilage attached to a rib.

Costochondral (kos-to-KON-dral): Pertaining to a rib and its cartilage.

Cranial cavity (KRA-ne-al KAV-ih-te): Space surrounded by the skull and containing the brain and other organs.

Craniotomy (kra-ne-OT-o-me): Incision of the skull.

Cranium (KRA-ne-um): Skull.

Creatinine (kre-AT-tih-neen): Nitrogen-containing waste that is removed from the blood by the kidney and excreted in urine.

Crohn disease (kron dih-ZEEZ): Inflammation of the gastrointestinal tract (often the ileum) marked by bouts of diarrhea, abdominal cramping, and fever. Along with ulcerative colitis, Crohn's is a type of INFLAMMATORY BOWEL DISEASE.

Cross section (kros SEK-shun): Division of an organ or the body into upper and lower portions; TRANSVERSE PLANE.

Cryosurgery (kri-o-SUR-jeh-re): Use of cold temperatures (such as liquid nitrogen) to freeze and destroy tissue.

Cryotherapy (kri-o-THER-ah-pe): Treatment using cold (CRY/O) temperatures.

Cryptorchism (kript-OR-kizm): Undescended (CRYPT- means hidden) testicle. The testicle is not in the scrotal sac at birth. Also called *cryptorchidism*.

CT colonography (CT ko-lon-OG-ra-fe): CT imaging procedure using x-rays and computer equipment to produce images of the colon and display them on a screen. Also called *virtual colonoscopy*.

CT scan: Computed tomography study; series of x-ray images showing organs in cross section (transverse view). Also called a CAT SCAN.

Cusp (KUSP): Any one of the small flaps on the valves of the heart. Also, a sharp projection extending from the surface of a tooth.

Cushing syndrome (KOOSH-ing SYN-drohm): Clinical signs and symptoms produced by an excess of cortisol from the adrenal cortex. Cushing syndrome is marked by "moon face," fatty swellings, and weakness.

Cuticle (KU-ti-cul): Thin layer of dead skin at the base of the nail plate.

Cyanosis (si-ah-NO-sis): Bluish discoloration of the skin due to deficient OXYGEN in the bloodstream.

Cystitis (sis-TI-tis): Inflammation of the urinary bladder.

Cystoscope (SIS-to-skope): Instrument (endoscope) used to view the urinary bladder.

Cystoscopy (sis-TOS-ko-pe): Visual examination of the urinary bladder.

Cytology (si-TOL-o-je): Study of cells.

D

Debridement (de-BREED-ment): Removal of diseased tissue from the skin.

Deep vein thrombosis (deep vayn throm-BO-sis): Abnormal condition of clot formation in a deep vein, usually in the leg or pelvic (hip) region.

Defibrillation (de-fib-rih-LA-shun): Brief discharges of electricity applied to the chest to stop an abnormal heart rhythm.

Delusion (deh-LOO-zhun): A persistent belief held by a person despite evidence to the contrary.

Dementia (deh-MEN-shah): Loss of memory and mental abilities.

Dermal (DER-mal): Pertaining to the skin.

Dermatitis (der-mah-TI-tis): Inflammation of the skin.

Dermatologist (der-mah-TOL-o-jist): Physician specializing in the skin and its diseases.

Dermatology (der-mah-TOL-o-je): Study of the skin and its diseases.

Dermatosis (der-mah-TO-sis): Abnormal condition of the skin.

Dermis (DER-mis): Fibrous middle layer of the skin below the epidermis. The dermis contains nerves and blood vessels, hair roots, and oil and sweat glands.

Diabetes mellitus (di-ah-BE-teez MEL-lih-tus): Disorder marked by deficient insulin in the blood, which causes sugar to remain in the blood rather than entering cells. Diabetes is named from a Greek word meaning "siphon" (through which water passes easily). One symptom is frequent urination (polyuria). Type 1 diabetes is marked by lack of insulin, and patients need injections of insulin. In type 2 diabetes, insulin is not adequately or appropriately secreted. Type 2 diabetes has a tendency to develop later in life, and patients can be managed with diet, exercise, and oral antidiabetic drugs.

Diagnosis (di-ag-NO-sis): Complete knowledge of patient's condition (*plural*: diagnoses).

Dialysis (di-AL-ih-sis): Complete separation (-LYSIS) of wastes (urea) from the blood when the kidneys fail. See also [HEMODIALYSIS](#) and [PERITONEAL DIALYSIS](#).

Diameter (di-AM-eh-ter): Measurement (-meter) through (dia-) center of a circle or tube. The diameter of an artery is larger than the diameter of a vein or capillary.

Diaphragm (DI-ah-fram): Muscle that separates the chest from the abdomen.

Diarrhea (di-ah-RE-ah): Discharge of watery wastes from the COLON.

Digestive system (di-JES-tiv SIS-tem): Organs that bring food into the body and break it down to enter the bloodstream or eliminate it through the rectum and anus.

Dilation (di-LA-shun): Widening; dilatation.

Dilation and curettage (di-LA-shun and kur-eh-TAZH): Widening of the opening to the cervix and scraping (curettage) of the inner lining of the uterus; also called D&C.

Disc (disk): Pad of cartilage that is between each backbone. Also spelled disk.

Diuretic (di-u-RET-ik): Drug that causes kidneys to allow more fluid (as urine) to leave the body. Diuretics remove fluid from the blood and are used to treat HYPERTENSION. DI- (from DIA-) means complete, and UR- means urine.

Diverticula (di-ver-TIK-u-lah): Small pouches or sacs created by herniation of mucous membrane linings, most commonly in the colon (*singular*: diverticulum).

Diverticulitis (di-ver-tik-u-LI-tis): Inflammation of diverticula. Penetration of fecal material through thin-walled diverticula causes inflammation and infection in the colon.

Diverticulosis (di-ver-tik-u-LO-sis): Abnormal condition of small pouches in the lining of the intestines.

Duodenal (do-o-DE-nal): Pertaining to the duodenum.

Duodenum (do-o-DE-num): First part of the small intestine.

Dura mater (DU-rah MAH-ter): Outermost of the three layers of the MENINGES surrounding the brain and spinal cord. The name comes from Latin, meaning "hard mother." It is the toughest of the three layers.

Dysentery (DIS-en-teh-re): Condition of painful intestines (often caused by bacterial infection).

Dysmenorrhea (dis-men-o-RE-ah): Painful menstrual flow.

Dyspepsia (dis-PEP-se-ah): Painful (DYS-) digestion (-PEPSIA).

Dysphagia (dis-FA-jah): Difficult swallowing.

Dysphasia (dis-FA-zhah): Difficult (impairment of) speech.

Dysplasia (dis-PLA-zhah): Abnormality of the development or the formation of cells. Normal cells change in size, shape, and organization.

Dyspnea (disp-NE-ah): Painful (DYS-) (labored, difficult) breathing (-PNEA).

Dysuria (dis-U-re-ah): Painful or difficult urination.

E

Ear: Organ that receives sound waves and transmits them to nerves leading to the brain.

Eardrum (EAR-drum): Membrane separating the outer and middle parts of the ear; the tympanic membrane.

Ectopic pregnancy (ek-TOP-ik PREG-nan-se): Pregnancy that is not in the uterus, usually occurring in the FALLOPIAN TUBES.

Edema (eh-DE-mah): Swelling in tissues. Edema is often caused by retention (holding back) of fluid and salt by the kidneys.

Ejaculation (e-jak-ku-LA-shun): Release of semen from the male urethra.

Electrocardiogram (e-lek-tro-KAR-de-o-gram): Record of the electricity in the heart.

Electroencephalogram (e-lek-tro-en-SEF-ah-lo-gram): Record of the electricity in the brain.

Electroencephalography (e-lek-tro-en-sef-ah-LOG-rah-fe): Process of recording the electricity in the brain.

Electrolyte (eh-LEK-tro-lite): Substance that conducts an electrical current and is found in blood (serum) and body cells. Examples are sodium (Na⁺), potassium (K⁺), calcium (Ca²⁺), and chloride (Cl⁻).

Embolization (em-bo-lih-ZA-shun): Use of a substance to block or reduce blood flow in a vessel.

Embolus (EM-bo-lus): Foreign object (air, tissue, tumor, or clot) that circulates in the bloodstream until it lodges in a vessel.

Embryo (EM-bre-o): A new organism in an early stage of development (2 to 6 weeks). From 6 to 38 weeks, the developing infant is a fetus.

Emergency medicine (e-MER-jen-se MED-ih-sin): Care of patients requiring immediate action.

Emphysema (em-fih-SE-mah): Lung disorder in which air becomes trapped in the air sacs and bronchioles, making breathing difficult. Emphysema is marked by the accumulation of mucus and the loss of elasticity in lung tissue.

Encephalitis (en-sef-ah-LI-tis): Inflammation of the brain.

Encephalopathy (en-sef-ah-LOP-ah-the): Disease of the brain.

Endocarditis (EN-do-kar-DI-tis): Inflammation of the inner lining of the heart (ENDOCARDIUM).

Endocardium (en-do-KAR-de-um): Inner lining of the heart.

Endocrine glands (EN-do-krin glanz): Organs that produce (secrete) hormones; examples are thyroid, pituitary, and adrenal glands.

Endocrine system (EN-do-krin SIS-tem): Endocrine glands.

Endocrinologist (en-do-krin-NOL-o-jist): Specialist in the study of endocrine glands and their disorders.

Endocrinology (en-do-krin-NOL-o-je): Study of ENDOCRINE GLANDS.

Endodontist (en-do-DON-tist): Dentist who specializes in diagnosis and treatment of the inner parts of a tooth (root canal therapy).

Endometriosis (en-do-me-tre-O-sis): An abnormal condition in which tissue from the inner lining of the uterus is found outside the uterus, usually in the pelvic cavity.

Endometrium (en-do-ME-tre-um): Inner lining of the uterus.

Endoscope (EN-do-skope): Instrument used to view a hollow organ or body cavity; a tube fitted with a lens system that allows viewing in different directions.

Endoscopic retrograde cholangiopancreatography (en-do-SKOP-ik RET-tro-grade kol-an-je-o-pan-kre-ah-TOG-rah-fe): X-ray images of bile ducts and pancreas after injection of contrast through a catheter from the mouth, esophagus, and stomach into bile and pancreatic ducts.

Endoscopy (en-DOS-ko-pe): Process of viewing the inside of hollow organs or cavities with an endoscope.

Enteric (en-TER-ik): Pertaining to the small intestine.

Enteritis (en-teh-RI-tis): Inflammation of the small intestine.

Epidermis (ep-ih-DER-mis): Outer (EPI-) layer of the skin (-DERMIS).

Epidural hematoma (ep-ih-DUR-al he-mah-TO-mah): Pathologic mass of blood above the dura mater (outermost layer of membranes surrounding the brain and spinal cord).

Epiglottis (ep-ih-GLOT-tis): Flap of cartilage that covers the mouth of the trachea when swallowing occurs so that food cannot enter the airway.

Epiglottitis (ep-ih-gloh-TI-tis): Inflammation of the EPIGLOTTIS.

Epilepsy (EP-ih-lep-se): Condition in which abnormal electrical activity in the brain results in sudden, fleeting disturbances in nerve cell functioning. An attack of epilepsy is called a SEIZURE.

Epinephrine (eh-pih-NEF-rin): Hormone secreted by the adrenal gland in response to stress and physical injury. It is a drug used to treat hypersensitivity reactions (severe allergy), asthma, bronchial spasm, and nasal congestion. Also called ADRENALINE.

Epithelial (ep-ih-THE-le-al): Pertaining to skin cells. This term originally described cells upon (EPI-) the breast nipple (THELI-). Now, it indicates cells lining the inner part of internal organs and covering the outside of the body.

Epithelium (ep-ih-THE-le-um): Covering of the internal and external tissues of the body (skin, vessels, body cavities, glands, and organs).

Erythrocyte (eh-RITH-ro-site): Red blood cell.

Erythrocytosis (eh-rith-ro-si-TO-sis): Abnormal condition (slight increase in numbers) of red blood cells.

Erythromycin (eh-rith-ro-MI-sin): An antibiotic that is produced from a red (ERYTHR/O-) mold (-MYCIN).

Esophageal (eh-sof-ah-JE-al): Pertaining to the esophagus.

Esophagitis (eh-sof-ah-JI-tis): Inflammation of the esophagus.

Esophagoscopy (eh-sof-ah-GOS-ko-pe): Visual examination of the esophagus.

Esophagus (eh-SOF-ah-gus): Tube leading from the throat to the stomach.

Estrogen (ES-tro-jen): Hormone that promotes the development of female secondary sex characteristics. Examples are estradiol, estriol, and conjugated estrogen.

Eustachian tube (u-STA-she-an tube): Channel connecting the middle part of the ear with the throat.

Exacerbation (eg-zas-er-BA-shun): Increase in the seriousness of a disease, with greater intensity in the signs or symptoms.

Excision (ek-SIZH-un): Act of cutting out, removing, or resecting.

Exocrine glands (EK-so-krin glanz): Glands that produce (secrete) chemicals that leave the body through tubes (ducts). Examples are tear, sweat, and salivary glands.

Exophthalmic goiter (ek-sof-THAL-mik GOY-ter): Enlargement of the thyroid gland accompanied by high levels of thyroid hormone in the blood and protrusion of the eyeballs (EXOPHTHALMOS).

Exophthalmos (ek-sof-THAL-mos): Abnormal protrusion of eyeballs usually caused by HYPERTHYROIDISM.

Extracranial (eks-tra-KRA-ne-al): Pertaining to outside the skull.

Extrahepatic (eks-tra-heh-PAT-ik): Pertaining to outside the liver.

Extrapulmonary (eks-trah-PUL-mo-nah-re): Outside the lungs.

Eye (i): Organ that receives light waves and transmits them to the brain.

F

Fallopian tubes (fah-LO-pe-an toobz): Two tubes that lead from the ovaries to the uterus. They transport egg cells to the uterus; also called uterine tubes.

Family medicine (FAM-ih-le MED-ih-sin): Primary care of all members of the family on a continuing basis.

Family practitioner (FAM-ih-le prak-TIH-shan-er): Medical doctor responsible for primary care and treatment of patients on a continuing basis.

Fatigue (fah-TEEG): State of exhaustion or loss of strength.

Feces (FEE-seez): Waste material from the digestive tract that is expelled from the body through the rectum and anus.

Fellowship training (FEL-o-ship TRA-ning): Postgraduate training for doctors in specialized fields. The training may include CLINICAL and RESEARCH (laboratory) work.

Female reproductive system (FE-male re-pro-DUK-tiv SIS-tem): Organs (OVARIES) that produce and transport (FALLOPIAN TUBES) egg cells and secrete female hormones (ESTROGEN and PROGESTERONE). The system includes the uterus, where the embryo and fetus grow.

Femur (FE-mur): Thigh bone.

Fetus (FE-tus): Unborn offspring in the uterus after 8 weeks of pregnancy until birth.

Fibrillation (fih-brih-LA-shun): Rapid, irregular, involuntary muscular contraction. Atrial and ventricular fibrillation are cardiac (heart) ARRHYTHMIAS.

Fibroids (FI-broydz): Benign growths of muscle tissue in the uterus.

Fibrosarcoma (fi-bro-sar-KO-mah): Malignant tumor of fibrous tissue.

Fibula (FIB-u-lah): Smaller lower leg bone.

Fistula (FIS-tu-lah): Abnormal passageway from an internal organ to the body surface or between two internal organs.

Fixation (fik-SA-shun): Act of holding, sewing, or fastening a part in a fixed position.

Flutter (FLUT-er): Rapid but regular, abnormal heart muscle contraction. Atrial and ventricular flutter are heart ARRHYTHMIAS.

Follicle-stimulating hormone (FOL-ih-kl STIM-u-la-ting HOR-mone): Hormone secreted by the pituitary gland to stimulate the egg cells in the ovaries.

Fracture (FRAK-chur): Breaking of a bone.

Frontal (FRUN-tal): Pertaining to the front; anterior.

Frontal plane (FRUN-tal playn): Vertical plane that divides the body or an organ into front and back portions; the CORONAL PLANE.

Functional disorder (FUNG-shih-nal dis-OR-der): Condition in which there are clinical signs and symptoms but no evidence of a structural or biochemical cause.

G

Gadolinium (gad-o-LIN-e-um): Chemical element that is used as a contrast agent in MRI studies. Symbol is Gd.

Gallbladder (GAWL-blah-der): Sac below the liver that stores bile and delivers it to the small intestine.

Ganglion (GANG-le-on): Benign cyst near a joint (wrist); also, a group of nerve cells (*plural*: ganglia [GANG-le-ah]).

Gangrene (GANG-reen): Necrosis (death) of tissue as a result of blood vessel injury, frostbite, or conditions such as diabetes or atherosclerosis. It results from ischemia, deficiency of blood flow caused by narrowing or obstruction of blood vessels.

Gastralgia (gas-TRAL-jah): Stomach pain.

Gastrectomy (gas-TREK-to-me): Excision (removal) of the stomach.

Gastric (GAS-trik): Pertaining to the stomach.

Gastritis (gas-TRI-tis): Inflammation of the stomach.

Gastroenteritis (gas-tro-en-teh-RI-tis): Inflammation of the stomach and intestines.

Gastroenterologist (gas-tro-en-ter-OL-o-jist): Specialist in the treatment of stomach and intestinal disorders.

Gastroenterology (gas-tro-en-ter-OL-o-je): Study of the stomach and intestines.

Gastroesophageal reflux disease (gas-tro-eh-sof-ah-JE-al RE-flux dih-ZEEZ): Condition marked by backflow (reflux) of contents of the stomach into the esophagus. Abbreviation is GERD.

Gastrojejunostomy (gas-tro-jeh-joo-NOS-to-me): New, surgically created opening between the stomach and the jejunum (second part of the small intestine). This procedure is an anastomosis.

Gastroscope (GAS-tro-skope): Instrument used to view the stomach. It is passed down the throat and esophagus into the stomach.

Gastroscoy (gas-TROS-ko-pe): Visual examination of the stomach.

Gastrotomy (gas-TROT-o-me): Incision of the stomach.

GERD: See [GASTROESOPHAGEAL REFLUX DISEASE](#).

Geriatric (jer-e-AH-trik): Pertaining to treatment of older people.

Geriatrician (jer-e-ah-TRISH-an): Specialist in the treatment of diseases of old age.

Geriatrics (jer-e-AH-triks): Treatment of disorders of old age.

Gestation (jes-TA-shun): Growth of the fetus that occurs during pregnancy.

Gland: Group of cells that secretes chemicals to the outside of the body (EXOCRINE GLANDS) or hormones directly into the bloodstream (ENDOCRINE GLANDS).

Glaucoma (glaw-KO-mah): Increase of fluid pressure within the eye. Fluid is formed more rapidly than it is removed. The increased pressure damages sensitive cells in the back of the eye, and vision is disturbed.

Glial cells (GLI-al selz): Supporting cells of nervous tissue in the brain. Examples are astrocytes and microglial and oligodendroglial cells. These cells are the source of primary brain tumors.

Glioblastoma (gli-o-blas-TO-mah): Malignant brain tumor composed of immature (-BLAST) glial (supportive nervous tissue) cells.

Glucocorticoid (gloo-ko-KOR-tih-koyd): Hormone secreted by the adrenal gland (cortex) to raise blood sugar levels. Examples are cortisone and cortisol.

Glycosuria (gli-ko-SU-re-ah): Abnormal condition of sugar in the urine.

Goiter (GOY-ter): Enlargement of the thyroid gland.

Gonorrhea (gon-oh-RE-ah): Sexually transmitted disease most often affecting the reproductive and urinary tracts and caused by infection with the bacterium *Neisseria gonorrhoeae*.

Gout (gout): See [GOUTY ARTHRITIS](#).

Gouty arthritis (GOW-te arth-RI-tis): Deposits of uric acid crystals in joints and other tissues that cause swelling and inflammation of joints. Also called GOUT.

Graves disease (grayvz dih-ZEEZ): See [HYPERTHYROIDISM](#).

Growth hormone (groth HOR-mone): Hormone secreted by the pituitary gland to stimulate the growth of bones and the body in general. Also called somatotropin.

Gynecologist (gi-neh-KOL-o-jist): Specialist in the study of female disorders.

Gynecology (gi-neh-KOL-o-je): Study of female disorders.

H

Hair follicle (hayr FOL-ih-k'l): Pouch-like depression in the skin in which a hair develops.

Hair root (hayr root): Part of the hair from which growth occurs.

Hallucination (hah-loo-sih-NA-shun): False sensory perception, such as hearing voices when none are present.

HDL: See [HIGH-DENSITY LIPOPROTEIN](#).

Heart (hart): Hollow, muscular organ in the chest that pumps blood throughout the body.

Heart attack (hart ah-TAK): See [MYOCARDIAL INFARCTION](#).

Hemangioma (he-man-je-O-mah): Tumor (benign) of blood vessels.

Hematemesis (he-mah-TEM-eh-sis): Vomiting (-EMESIS) of blood (HEMAT/O-).

Hematologist (he-mah-TOL-o-jist): Specialist in blood and blood disorders.

Hematology (he-mah-TOL-o-je): Study of the blood.

Hematoma (he-mah-TO-mah): Mass or collection of blood under the skin. Commonly called a bruise or "black-and-blue" mark.

Hematuria (he-mah-TUR-e-ah): Abnormal condition of blood in the urine.

Hemigastrectomy (heh-me-gas-TREK-to-me): Removal of half of the stomach.

Hemiglossectomy (heh-me-glos-EK-to-me): Removal of half of the tongue.

Hemiplegia (hem-ih-PLE-jah): Paralysis that affects the right or left side of the body.

Hemoccult test (he-mo-KULT test): A standardized test to look for hidden (occult) blood in stool. It is a screening test for colon and rectal cancer. See also [STOOL GUAIAAC](#).

Hemodialysis (he-mo-di-AL-ih-sis): Use of a kidney machine to filter blood to remove waste materials such as urea. Blood leaves the body, enters the machine, and is carried back to the body through a catheter (tube).

Hemoglobin (HE-mo-glo-bin): Oxygen-carrying protein found in red blood cells.

Hemoptysis (he-MOP-tih-sis): Spitting up (-PTYSIS) of blood (HEM/O-) from the respiratory tract.

Hemorrhage (HEM-or-ij): Bursting forth of blood.

Hemothorax (he-mo-THOR-aks): Collection of blood in the chest (pleural cavity).

Hepatic (heh-PAT-ik): Pertaining to the liver.

Hepatitis (hep-ah-TI-tis): Inflammation of the liver. Viral hepatitis is an acute infectious disease caused by at least three different viruses: hepatitis A, B, and C viruses.

Hepatocellular carcinoma (hep-ah-to-SEL-u-lar kar-sih-NO-mah): Malignant tumor of the liver.

Hepatoma (hep-ah-TO-mah): Tumor (malignant) of the liver; HEPATOCELLULAR CARCINOMA.

Hepatomegaly (hep-ah-to-MEG-ah-le): Enlargement of the liver.

Hernia (HER-ne-ah): Bulge or protrusion of an organ or part of an organ through the wall of the

cavity that usually contains it. In an **INGUINAL** hernia, part of the wall of the abdomen weakens and the intestine bulges outward or into the **SCROTAL** sac (in males).

Herpes genitalis (HER-pee-z jen-ih-TAL-is): Chronic sexually transmitted disease caused by type 2 herpes simplex virus.

Hiatal hernia (hi-A-tal HER-ne-ah): Upward protrusion of the wall of the stomach into the lower part of the esophagus.

High-density lipoprotein (hi DEN-sih-te li-po-PRO-teen): Combination of fat and protein in the blood. It carries cholesterol to the liver, which is beneficial.

Hilum (HI-lum): Depression at that part of an organ where blood vessels and nerves enter.

HIV: See [HUMAN IMMUNODEFICIENCY VIRUS](#).

Hodgkin lymphoma (HOJ-kin lim-FO-mah): Malignant tumor of lymph nodes.

Hormone (HOR-mone): Chemical made by a gland and sent directly into the bloodstream, not to the outside of the body. **ENDOCRINE GLANDS** produce hormones.

Hospitalist (HOS-pih-tah-list): A physician whose primary focus is hospital medicine. This includes patient care, teaching, and research related to hospital care.

Human immunodeficiency virus (HYOO-man im-u-no-deh-FISH-en-se VI-rus): Virus that infects white blood cells (T-cell lymphocytes), causing damage to the patient's immune system. It is the cause of AIDS. Abbreviated HIV.

Humerus (HYOO-mer-us): Upper arm bone.

Hydrocele (HI-dro-seel): Swelling of the **SCROTUM** caused by a collection of fluid within the outermost covering of the **TESTIS**.

Hyperbilirubinemia (hi-per-bil-ih-roo-bin-E-me-ah): High levels of bilirubin (pigment released from hemoglobin breakdown and processed in the liver) in the bloodstream. See [JAUNDICE](#).

Hyperglycemia (hi-per-gli-SE-me-ah): High blood sugar.

Hyperparathyroidism (hi-per-par-ah-THI-royd-ism): Higher than normal level of parathyroid hormone in the blood.

Hyperplasia (hi-per-PLA-ze-ah): Cells increase in number. The prostate gland is enlarged in benign prostatic hyperplasia (BPH).

Hyperplastic (hi-per-PLAS-tik): Pertaining to excessive growth of normal cells in an organ.

Hypersecretion (hi-per-se-KRE-shun): Abnormally high production of a substance.

Hypertension (hi-per-TEN-shun): High blood pressure. *Essential hypertension* has no known cause, but contributing factors are age, obesity, smoking, and heredity. *Secondary hypertension* is a sign of other disorders such as kidney disease.

Hyperthyroidism (hi-per-THI-royd-izm): Excessive activity of the thyroid gland.

Hypertrophy (hi-PER-tro-fe): Enlargement or overgrowth of an organ or part of the body as a result of an increase in size of individual cells.

Hypochondriac (hi-po-KON-dre-ak): Pertaining to lateral regions of the upper abdomen beneath the lower ribs. Also, the term describes a person who has chronic concern about their health and body functions.

Hypodermic (hi-po-DER-mik): Pertaining to under or below the skin.

Hypoglycemia (hi-po-gli-SE-me-ah): Low blood sugar.

Hypophyseal (hi-po-FIZ-e-al): Pertaining to the pituitary gland.

Hypopituitarism (hi-po-pih-TOO-ih-tah-rizm): Decrease or stoppage of hormonal secretion by the pituitary gland.

Hypoplastic (hi-po-PLAS-tik): Pertaining to underdevelopment of a tissue or organ in the body.

Hyposecretion (hi-po-se-KRE-shun): Abnormally low production of a substance.

Hypotensive (hi-po-TEN-siv): Pertaining to low blood pressure or to a person with abnormally low blood pressure.

Hypothyroidism (hi-po-THI-royd-izm): Less than normal activity of the thyroid gland.

Hysterectomy (his-teh-REK-to-me): Excision of the uterus, either through the abdominal wall (abdominal hysterectomy) or through the vagina (vaginal hysterectomy).

Hysteroscopy (his-ter-OS-ko-pe): Visual examination of the uterus with an endoscope inserted through the vagina and uterine cervix.

I

Iatrogenic (i-ah-tro-JEN-ik): Pertaining to an adverse condition that results from a medical or surgical treatment.

Ileostomy (il-e-OS-to-me): New opening of the ILEUM to the outside of the body.

Ileum (IL-e-um): Third part of the small intestine.

Ilium (IL-e-um): Side, high portion of the hip bone (pelvis).

Incision (in-SIZH-un): Cutting into the body or into an organ.

Infarction (in-FARK-shun): Area of dead tissue (necrosis) caused by decreased blood flow to that part of the body. Also called *infarct*.

Infectious disease specialist (in-FEK-shus dih-ZEEZ SPESH-ah-list): Physician who treats disorders caused and spread by microorganisms such as bacteria.

Infiltrate (IN-fil-trat): Material that accumulates in an organ. The term infiltrate often describes solid material or fluid collection in the lungs.

Inflammatory bowel disease (in-FLAM-ah-tor-e BOW-el dih-ZEEZ): Disorder marked by inflammation of the small and large intestines with bouts of diarrhea, abdominal cramping, and fever. Inflammatory bowel diseases include CROHN DISEASE and ULCERATIVE COLITIS.

Inguinal (IN-gwih-nal): Pertaining to the groin, or the area where the legs meet the body. Inguinal lymph nodes are located in the groin.

Insulin (IN-su-lin): Hormone produced by the pancreas and released into the bloodstream. Insulin allows sugar to leave the blood and enter body cells.

Insulin pump (IN-su-lin pump): Portable, battery-powered device that delivers insulin through the abdominal wall in measured amounts.

Internal medicine (in-TER-nal MED-ih-sin): Branch of medicine specializing in the diagnosis of disorders and treatment with drugs.

Intervertebral (in-ter-VER-teh-bral): Pertaining to lying between two backbones. A disc (disk) is an intervertebral structure.

Intra-abdominal (in-trah-ab-DOM-ih-nal): Pertaining to within the abdomen.

Intracranial (in-trah-KRA-ne-al): Pertaining to within the skull.

Intrauterine (in-trah-U-ter-in): Pertaining to within the uterus.

Intravenous (in-trah-VE-nus): Pertaining to within a vein.

Intravenous pyelogram (in-trah-VE-nus PI-eh-lo-gram): X-ray record of the kidney (PYEL/O-means renal pelvis) after contrast is injected into a vein.

Intravesical (in-trah-VES-ih-kal): Pertaining to within the urinary bladder.

Iris (I-ris): Colored (pigmented) portion of the eye.

Irritable bowel syndrome (IR-ih-tah-b'l BOW-el SYN-droh-m): A FUNCTIONAL DISORDER of the bowel marked by abdominal pain, discomfort, and bloating, but without evidence of detectable lesions or cause.

Ischemia (is-KE-me-ah): Deficiency of blood flow to a part of the body, caused by narrowing or obstruction of blood vessels. Ischemia may lead to necrosis (death of cells).

J

Jaundice (JAWN-dis): Orange-yellow coloration of the skin and other tissues. A symptom caused

by accumulation of BILIRUBIN (pigment) in the blood.

Jejunum (jeh-JOO-num): Second part of the small intestine.

Joint (joynt): Place where two or more bones come together (articulate).

K

Kidney (KID-ne): One of two organs located behind the abdomen that produce urine by filtering wastes from the blood.

L

Laminectomy (lah-mih-NEK-to-me): Removal of a piece of backbone (lamina) to relieve pressure on nerves from a herniating disk (disc).

Laparoscope (LAP-ah-ro-skope): Instrument to visually examine the abdomen. An endoscope is inserted through a small incision in the abdominal wall.

Laparoscopic appendectomy (lap-ah-ro-SKOP-ik ah-pen-DEK-to-me): Removal of the appendix through a small incision in the abdomen and with the use of a laparoscope.

Laparoscopic cholecystectomy (lap-ah-ro-SKOP-ik ko-leh-sis-TEK-to-me): Removal of the gallbladder through a small incision in the abdomen and with the use of a laparoscopic instrument.

Laparoscopic surgery (lap-ah-ro-SKOP-ik SUR-jer-e): Removal of organs or tissues via instruments inserted into the abdomen through small incisions. Also called MINIMALLY INVASIVE SURGERY or keyhole surgery.

Laparoscopy (lap-ah-ROS-ko-pe): Visual examination of the abdomen. Small incisions are made near the navel, and an instrument (endoscope or laparoscope) is inserted to view abdominal organs.

Laparotomy (lap-ah-ROT-o-me): Incision of the abdomen. A surgeon makes a large incision across the abdomen to examine and operate on its organs.

Large intestine (larj in-TES-tin): Part of the intestine that receives undigested material from the small intestine and transports it out of the body; the COLON.

Laryngeal (lah-rin-JE-al): Pertaining to the LARYNX (voice box).

Laryngectomy (lah-rin-JEK-to-me): Removal of the LARYNX (voice box).

Laryngitis (lah-rin-JI-tis): Inflammation of the LARYNX.

Laryngoscopy (lar-in-GOS-ko-pe): Visual examination of the interior of the voice box (LARYNX) with an endoscope.

Laryngotracheitis (lah-ring-o-tra-ke-I-tis): Inflammation of the larynx and the trachea (windpipe).

Larynx (LAR-inks): Voice box; located at the top of the trachea and containing vocal cords.

Lateral (LAT-er-al): Pertaining to the side.

LDL: See [LOW-DENSITY LIPOPROTEIN](#).

Leiomyoma (li-o-mi-O-mah): Benign tumor derived from smooth (involuntary or visceral) muscle, most often of the uterus (leiomyoma uteri). LEIOMY/O- means smooth muscle.

Leiomyosarcoma (li-o-mi-o-sar-KO-mah): Malignant tumor of smooth (involuntary) muscle.

Lens (lenz): Transparent elastic structure behind the iris and pupil of the eye. The lens bends light rays so that they are properly focused on the RETINA at the back of the eye.

Lesion (LE-zhun): Abnormal tissue, usually damaged by disease or trauma. From the Latin *laesio*, meaning "injury."

Leukemia (loo-KE-me-ah): Increase in malignant (cancerous) white blood cells (in blood and bone marrow).

Leukocyte (LOO-ko-site): White blood cell.

Leukocytosis (loo-ko-si-TO-sis): Abnormal condition of white blood cells. This is a slight increase

in numbers of normal white blood cells in response to infection.

Ligament (LIG-ah-ment): Connective tissue that joins bones to other bones.

Ligamentous (lig-ah-MEN-tus): Pertaining to a LIGAMENT.

Liposarcoma (li-po-sar-KO-mah): Malignant tumor of fatty tissue.

Lithotripsy (LITH-o-trip-se): Process of crushing a stone in the urinary tract using ultrasonic vibrations. Also called extracorporeal shock-wave lithotripsy (ESWL).

Liver (LIV-er): Organ in the right upper quadrant of the abdomen. The liver produces BILE, stores sugar, and produces blood-clotting proteins.

Lobe (lobe): Part of an organ, especially of the brain, lungs, or glands.

Low-density lipoprotein (lo DEN-sih-te li-po-PRO-teen): Combination of lipid (fat) and protein. It has a high CHOLESTEROL content and is associated with formation of plaques in arteries.

Lower gastrointestinal (GI) series (LO-er gas-tro-in-TES-tin-al SER-eez): Barium is injected into the anus and rectum, and x-rays are taken of the colon (large intestine).

Lumbar (LUM-bar): Pertaining to the loins; part of the back and sides between the chest and the hip.

Lumbar puncture (LUM-bar PUNK-cher): Removal of cerebrospinal fluid (CSF) for diagnostic analysis or occasionally as treatment to relieve increased intracranial pressure.

Lumbar region (LUM-bar RE-jun): Pertaining to the 5 backbones that lie between the thoracic (chest) and sacral (lower back) vertebrae.

Lumbar vertebra (LUM-bar VER-teh-brah): Backbone in the region between the chest and lower back.

Lung (lung): One of two paired organs in the chest through which oxygen enters and carbon dioxide leaves the body.

Lung capillaries (lung KAP-ih-layr-eez): Tiny blood vessels surrounding lung tissue and through which gases pass into and out of the bloodstream.

Lupus erythematosus: See [SYSTEMIC LUPUS ERYTHEMATOSUS](#).

Lymph (limf): Clear fluid that is found in lymph vessels and produced from fluid surrounding cells. Lymph contains white blood cells (lymphocytes) that fight disease.

Lymphadenectomy (limf-ah-deh-NEK-to-me): Removal of LYMPH NODES.

Lymphadenopathy (lim-fad-eh-NOP-ah-the): Disease of lymph nodes (glands).

Lymphangiectasis (limf-an-je-EK-tah-sis): Dilation (-ECTASIS) of small lymph vessels; often resulting from obstruction in large lymph vessels.

Lymphatic system (lim-FAT-ik SIS-tem): Group of organs (lymph vessels, lymph nodes, spleen, thymus) composed of lymphatic tissue that produce lymphocytes to defend the body against foreign organisms.

Lymphatic vessels (lim-FAT-ik VES-elz): Tubes that carry lymph from tissues to the bloodstream (into a vein in the neck region); lymph vessels.

Lymphedema (limf-ah-DE-mah): Accumulation of fluid in tissue spaces, causing swelling. Lymphedema is caused by the obstruction of lymph nodes or vessels.

Lymph node (limf node): Stationary collection of lymph cells, found all over the body. Lymph nodes are sometimes called lymph "glands."

Lymphocyte (LIMF-o-site): White blood cell that is found within lymph and lymph nodes. T cells and B cells are types of lymphocytes.

Lymphoid (LIM-foid): Resembling or pertaining to lymphatic tissue.

Lymphoma (lim-FO-mah): Malignant tumor of lymphatic tissue. Previously called lymphosarcoma. There are several types, including Hodgkin lymphoma and non-Hodgkin lymphoma.

M

Magnetic resonance imaging (mag-NET-ik REZ-o-nans IM-aj-ing): Image of the body with magnetic and radio waves. Organs are seen in three planes: coronal (front to back), sagittal (side to side), and transverse (cross-section). Also called MRI.

Male reproductive system (male re-pro-DUK-tiv SIS-tem): Organs that produce sperm cells and male hormones.

Malignant (mah-LIG-nant): Cancerous tumors that invade and spread to distant organs; tending to become progressively worse.

Mammary (MAM-er-e): Pertaining to the breast.

Mammogram (MAM-o-gram): X-ray record of the breast.

Mammography (mam-MOG-ra-fe): X-ray recording (imaging) of the breast.

Mammoplasty (MAM-o-plas-te): Surgical repair (reconstruction) of the breast.

Mastectomy (mas-TEK-to-me): Removal (excision) of the breast.

Mastitis (mas-TI-tis): Inflammation of the breast.

Mediastinal (me-de-ah-STI-nal): Pertaining to the MEDIASTINUM.

Mediastinoscopy (me-de-ah-sti-NOS-ko-pe): Visual examination of the mediastinum with an endoscope.

Mediastinum (me-de-ah-STI-num): Space between the lungs in the chest. The mediastinum contains the heart, large blood vessels, trachea, esophagus, thymus gland, and lymph nodes.

Medulla oblongata (meh-DUL-ah ob-lon-GAh-tah): Lower part of the brain near the spinal cord. The medulla oblongata controls breathing and the heartbeat.

Medullary (MEH-du-lar-e): Pertaining to the inner, or soft, part of an organ.

Melanocytes (meh-LA-no-sites): Pigmented cells in the lower portion of the epidermis. They produce a dark pigment called melanin.

Melanoma (meh-lah-NO-mah): Malignant tumor arising from pigmented cells (melanocytes) in the skin. A melanoma usually develops from a NEVUS (mole).

Meninges (meh-NIN-jeez): Membranes surrounding the brain and spinal cord.

Meningitis (men-in-JI-tis): Inflammation of the meninges (membranes around the brain and spinal cord).

Menorrhagia (men-or-RA-jah): Excessive bleeding from the uterus during the time of MENSTRUATION.

Menorrhea (men-o-RE-ah): Normal discharge of blood and tissue from the uterine lining during MENSTRUATION.

Menses (MEN-seez): Menstruation; menstrual period.

Menstruation (men-stroo-A-shun): Breakdown of the lining of the uterus that occurs every 4 weeks during the active reproductive period of a female.

Mesothelioma (mez-o-the-le-O-mah): Malignant tumor of the lining tissue (mesothelium) of the pleura. A mesothelioma is associated with exposure to asbestos.

Metacarpals (met-ah-KAR-palz): Bones of the hand between the wrist bones (carpals) and the finger bones (phalanges).

Metastasis (meh-TAS-tah-sis): Spread of a cancerous tumor to a distant organ or location. *Metastasis* literally means change (META-) of place (-STASIS). *Metastatic* means pertaining to a metastasis.

Metatarsals (meh-tah-TAR-salz): Foot bones.

Microscopic discectomy (mi-cro-SCOP-ic dis-KEK-to-me): Surgical removal of a herniated intervertebral disc.

Migraine (MI-grayn): Attack of headache, usually on one side of the head, caused by changes in blood vessel size and accompanied by nausea, vomiting, and sensitivity to light (photophobia).

This term is from the French word *migraine*, meaning “severe head pain.”

Minimally invasive surgery (MIN-ih-mah-le in-VA-siv SUR-jer-e): Removal and repair of organs and tissues with small incisions for an endoscope and instruments. Examples are laparoscopic cholecystectomy (gallbladder removal), laparoscopic appendectomy (appendix removal), laparoscopic herniorrhaphy (repair of a hernia), and laparoscopic colectomy (removal of a portion of the colon).

Mitral valve prolapse (MI-tral valv PRO-laps): Protrusion of one or both cusps of the mitral valve back into the left atrium when the ventricles contract.

Monocyte (MON-o-site): White blood cell with one large nucleus.

Mononucleosis (mon-o-nu-kle-O-sis): Acute infectious disease with excess monocytes in the blood and usually associated with extreme fatigue. Mononucleosis is caused by the Epstein-Barr virus and is transmitted by direct oral (mouth) contact.

Mouth (mowth): The opening that forms the beginning of the digestive system.

MRI: See [MAGNETIC RESONANCE IMAGING](#).

Mucus (MU-kus): Sticky secretion from mucous membranes and glands.

Multiple myeloma (MUL-tih-pul mi-eh-LO-mah): Malignant tumor of the bone marrow.

Multiple sclerosis (MUL-tih-pul skleh-RO-sis): Chronic neurologic disease in which there are patches of demyelination (loss of myelin sheath covering on nerve cells) throughout the brain and spinal cord. Weakness, abnormal sensations, incoordination, and speech and visual disturbances are symptoms.

Muscle (MUS-el): Connective tissue that contracts to make movement possible.

Muscular (MUS-ku-lar): Pertaining to muscles.

Muscular dystrophy (MUS-ku-lar DIS-tro-fe): Group of degenerative muscle diseases that cause crippling because muscles are gradually weakened and eventually ATROPHY (shrink).

Musculoskeletal system (mus-ku-lo-SKEL-eh-tal SIS-tem): Organs that support the body and allow it to move, including the muscles, bones, joints, and connective tissues.

Myalgia (mi-AL-jah): Pain in a muscle or muscles.

Myelitis (mi-eh-LI-tis): Inflammation of the spinal cord.

Myelin sheath (MI-eh-lin sheeth): Fatty covering around part (axon) of nerve cells. The myelin sheath insulates the nerve, helping to speed the conduction of nerve impulses.

Myelodysplasia (mi-eh-lo-dis-PLA-ze-ah): Abnormal development of bone marrow, a premalignant condition leading to leukemia.

Myelogram (MI-eh-lo-gram): X-ray image of the spinal cord after contrast is injected within the membranes surrounding the spinal cord in the lumbar area of the back.

Myelography (mi-eh-LOG-rah-fe): X-ray imaging of the spinal cord after injection of contrast material.

Myeloma (mi-eh-LO-mah): Malignant tumor originating in the bone marrow (MYEL/O-). Also called MULTIPLE MYELOMA.

Myocardial (mi-o-KAR-de-al): Pertaining to the muscle of the heart.

Myocardial infarction (mi-o-KAR-de-al in-FARK-shun): Death of tissue in heart muscle; also known as a heart attack or an MI.

Myocardial ischemia (mi-o-KAR-de-al is-KE-me-ah): Decrease in the blood supply to the heart muscle.

Myoma (mi-O-mah): Tumor (benign) of muscle.

Myomectomy (mi-o-MEK-to-me): Removal of a benign muscle tumor (fibroid).

Myosarcoma (mi-o-sar-KO-mah): Tumor (malignant) of muscle. SARC- means flesh, indicating that the tumor is of connective or “fleshy” tissue origin.

Myositis (mi-o-SI-tis): Inflammation of a muscle.

Myringotomy (mir-in-GOT-o-me): Incision of the eardrum.

N

Nasal (NA-zl): Pertaining to the nose.

Nausea (NAW-se-ah): Unpleasant sensation in the upper abdomen, often leading to vomiting. The term comes from the Greek *nausia*, meaning "seasickness."

Necropsy (NEH-krop-se): Examination of a dead body, usually in veterinary science, to determine the cause of death; POSTMORTUM.

Necrosis (neh-KRO-sis): Death of cells.

Necrotic (neh-KRO-tik): Pertaining to death of cells.

Needle biopsy (NE-d'I BI-op-se): Removal of living tissue for microscopic examination by inserting a hollow needle through the skin.

Neonatal (ne-o-NA-tal): Pertaining to new birth; the first 4 weeks after birth.

Neoplasm (NE-o-plazm): Any new growth of tissue; a tumor.

Neoplastic (ne-o-PLAS-tik): Pertaining to a new growth, or NEOPLASM.

Nephrectomy (neh-FREK-to-me): Removal (excision) of a kidney.

Nephritis (neh-FRI-tis): Inflammation of kidneys.

Nephrolithiasis (neh-fro-lih-THI-ah-sis): Condition of kidney stones.

Nephrologist (neh-FROL-o-jist): Specialist in the diagnosis and treatment of kidney diseases.

Nephrology (neh-FROL-o-je): Study of the kidney and its diseases.

Nephropathy (neh-FROP-ah-the): Disease of the kidney.

Nephrosis (neh-FRO-sis): Abnormal condition of the kidney. Nephrosis is often associated with a deterioration of the kidney tubules.

Nephrostomy (neh-FROS-to-me): Opening from the kidney to the outside of the body.

Nervous system (NER-vus SIS-tem): Organs (brain, spinal cord, and nerves) that transmit electrical messages throughout the body.

Neural (NU-ral): Pertaining to nerves.

Neuralgia (nu-RAL-jah): Nerve pain.

Neuritis (nu-RI-tis): Inflammation of nerves.

Neuroglial cells (nu-ro-GLE-al selz): See [GLIAL CELLS](#).

Neurologist (nu-ROL-o-jist): Specialist in the diagnosis and treatment of nervous disorders.

Neurology (nu-ROL-o-je): Study of the nervous system and nerve disorders.

Neuropathy (nu-ROP-ah-the): Disease of nervous tissue.

Neurosurgeon (nu-ro-SUR-jun): Physician who operates on the organs of the nervous system (brain, spinal cord, and nerves).

Neurotomy (nu-ROT-o-me): Incision of a nerve.

Nevus (NE-vus): Pigmented lesion on the skin (plural: nevi); a mole.

Nitroglycerin (ni-tro-GLIS-er-in): Drug that relaxes muscle and opens blood vessels.

Nocturia (nok-TU-re-ah): Excessive urination at night.

Nose (noz): Structure that is the organ of smell and permits air to enter and leave the body.

Nosocomial (nos-o-KO-me-al): Pertaining to or originating in a hospital. A *nosocomial infection* is acquired during hospitalization.

O

Obstetric (ob-STEh-trik): Pertaining to pregnancy, labor, and delivery of a baby.

Obstetrician (ob-steh-TRISH-an): Specialist in the delivery of a baby and care of the mother during pregnancy and labor.

Obstetrics (ob-STET-riks): Practice or branch of medicine concerned with the management of women during pregnancy, childbirth, and the period just after delivery of the infant.

Ocular (OK-u-lar): Pertaining to the eye.

Oncogenic (ong-ko-JEN-ik): Pertaining to producing (-GENIC) tumors.

Oncologist (ong-KOL-o-jist): Physician specializing in the study and treatment of cancerous tumors.

Oncology (ong-KOL-o-je): Study of tumors.

Onycholysis (on-ih-KOL-ih-sis): Separating (-LYSIS) of a nail (ONYCH/O) from its foundation (bed).

Oocyte (o-o-site): Egg cell (ovum).

Oophorectomy (o-of-o-REK-to-me or oo-fo-REK-to-me): Removal of an ovary or ovaries.

Oophoritis (o-of-o-RI-tis or oo-pho-RI-tis): Inflammation of an ovary.

Ophthalmologist (of-thal-MOL-o-jist): Specialist in the study of the eye and the treatment of eye disorders.

Ophthalmology (of-thal-MOL-o-je): Study of the eye; the diagnosis and treatment of eye disorders.

Ophthalmoscope (of-THAL-mo-scope): Instrument used to visually examine the eyes.

Optic nerve (OP-tik nerv): Nerve in the back of the eye that transmits light waves to the brain.

Optician (op-TISH-an): Nonmedical specialist trained to provide eyeglasses by filling prescriptions.

Optometrist (op-TOM-eh-trist): Nonmedical specialist trained to examine and test eyes and prescribe corrective lenses.

Oral (OR-al): Pertaining to the mouth.

Orchidectomy (or-kih-DEK-to-me): Removal (excision) of a testis (testicle).

Orchiectomy (or-ke-EK-to-me): Removal (excision) of a testicle or testicles.

Orchiopexy (or-ke-o-PEK-se): Surgical fixation of the testicle (testis) into its proper location within the scrotum. This surgery corrects CRYPTORCHISM.

Orchitis (or-KI-tis): Inflammation of a testicle.

Organ (OR-gan): Independent part of the body composed of different tissues working together to do a specific job.

Orthodontist (or-tho-DON-tist): Dentist specializing in straightening teeth.

Orthopedist (or-tho-PE-dist): Specialist in the surgical correction of musculoskeletal disorders. This physician was originally concerned with straightening (ORTH/O) bones in the legs of children (PED/O) with deformities.

Osteitis (os-te-I-tis): Inflammation of bone.

Osteoarthritis (os-te-o-ar-THRI-tis): Inflammation of bones and joints. Osteoarthritis is a disease of older people and is marked by stiffness, pain, and degeneration of joints.

Osteogenic sarcoma (os-te-o-JEN-ik sar-KO-mah): Malignant (cancerous) tumor of bone (-GENIC means produced in).

Osteoma (os-te-O-mah): Tumor (benign) of bone.

Osteomyelitis (os-te-o-mi-eh-LI-tis): Inflammation of bone and bone marrow. Osteomyelitis is caused by a bacterial infection.

Osteopenia (os-te-o-PE-ne-ah): Deficiency (-PENIA) of bone tissue.

Osteoporosis (os-te-o-po-RO-sis): Decrease in bone mass with formation of pores or spaces in normally mineralized bone tissue. This condition is more serious than osteopenia.

Osteotomy (os-te-OT-o-me): Incision of a bone.

Otalgia (o-TAL-jah): Pain in an ear.
Otitis (o-TI-tis): Inflammation of an ear.
Otolaryngologist (o-to-lah-rin-GOL-o-jist): Specialist in the treatment of diseases of the ear, nose, and throat.
Ovarian (o-VAYR-e-an): Pertaining to an ovary or ovaries.
Ovarian cancer (o-VAYR-e-an KAN-ser): Malignant condition of the ovaries.
Ovarian cyst (o-VAYR-e-an sist): Sac containing fluid or semisolid material in or on the ovary.
Ovary (O-vah-re): One of two organs in the female abdomen that produces egg cells and female hormones.
Ovum (O-vum): Egg cell (*plural:* ova [O-vah]).
Oxygen (OK-sih-jen): Colorless, odorless gas that is essential to sustaining life.

P

Pancreas (PAN-kre-us): Gland that produces digestive juices (exocrine function) and the hormone INSULIN (endocrine function).
Pancreatectomy (pan-kre-ah-TEK-to-me): Removal of the pancreas.
Pancreatitis (pan-kre-ah-TI-tis): Inflammation of the pancreas.
Pap Smear (PAP smear): Insertion of an instrument (spatula) into the vagina to obtain a sample of cells from the cervix (neck of the uterus).
Paralysis (pah-RAL-ih-sis): Loss or impairment of movement in a part of the body.
Paraplegia (par-ah-PLE-jah): Impairment or loss of movement in the lower part of the body, primarily the legs and in some cases bowel and bladder function.
Parathyroid glands (par-ah-THI-royd glanz): Four endocrine glands behind the thyroid gland. These glands are concerned with maintaining the proper levels of calcium in the blood and bones.
Parathyroid hormone (par-ah-THI-roid HOR-mone): Hormone secreted by the parathyroid glands to maintain a constant concentration of calcium in the blood and bones. Also called PTH.
Patella (pah-TEL-ah): Kneecap.
Pathogen (PATH-o-jen): Disease-producing organism (such as a bacterium or virus).
Pathologist (pah-THOL-o-jist): Specialist in the study of disease. A pathologist examines biopsies and performs autopsies.
Pathology (pah-THOL-o-je): Study of disease.
Pediatric (pe-de-AT-rik): Pertaining to treatment of a child.
Pediatrician (pe-de-ah-TRISH-un): Specialist in the treatment of childhood diseases.
Pediatrics (pe-de-AT-riks): Branch of medicine specializing in the treatment of children.
Pedodontist (ped-o-DON-tist): Dentist specializing in the diagnosis and treatment of children's dental problems.
Pelvic (PEL-vik): Pertaining to the bones of the hip area.
Pelvic cavity (PEL-vik KAV-ih-te): Space contained within the hip bones (front and sides) and the lower part of the backbone (sacrum and coccyx).
Pelvic inflammatory disease (PEL-vik in-FLAM-ah-to-re dih-ZEEZ): Inflammation of the pelvic region in females, usually involving the FALLOPIAN TUBES.
Pelvic ultrasonography (PEL-vik ul-trah-so-NOG-rah-fe): Recording of sound waves as they impact organs in the region of the hip.
Pelvis (PEL-vis): Lower part of the trunk of the body including the hip bone, tailbone, and sacrum (lower backbones).
Penicillin (pen-ih-SIL-in): Substance, derived from certain molds, that can destroy bacteria; an

ANTIBIOTIC.

- Penis (PE-nis):** External male organ containing the urethra, through which both urine and semen (sperm cells and fluid) leave the body.
- Peptic ulcer (PEP-tik UL-ser):** Sore (lesion) of the mucous membrane lining the first part of the small intestine (duodenum) or lining the stomach.
- Percutaneous (per-ku-TA-ne-us):** Pertaining to through the skin.
- Percutaneous transhepatic cholangiography (per-ku-TA-ne-us trans-heh-PAT-ik kol-an-je-OG-rah-fe):** Bile vessels are imaged after injection of contrast material through the skin into the liver.
- Perianal (peh-re-A-nal):** Pertaining to surrounding the ANUS.
- Pericardium (peh-rih-KAR-de-um):** Membrane surrounding the heart.
- Periodontist (peh-re-o-DON-tist):** Dentist specializing in the treatment of gum disease (surrounding a tooth).
- Periosteum (peh-re-OS-te-um):** Membrane that surrounds bone.
- Peritoneal (peh-rih-to-NE-al):** Pertaining to the PERITONEUM.
- Peritoneal dialysis (peh-rih-to-NE-al di-AL-ih-sis):** Process of removing wastes from the blood by introducing a special fluid into the abdomen (peritoneal cavity). The wastes pass into the fluid from the bloodstream, and then the fluid is drained from the body.
- Peritoneal fluid (peh-rih-to-NE-al FLOO-id):** Fluid produced in the abdominal cavity.
- Peritoneoscopy (peh-rih-to-ne-OS-ko-pe):** Visual examination of the peritoneal cavity with an endoscope. See LAPAROSCOPY.
- Peritoneum (peh-rih-to-NE-um):** Membrane that surrounds the abdomen and holds the abdominal organs in place.
- Peritonitis (peh-rih-to-NI-tis):** Inflammation of the peritoneum.
- Phalanges (fah-LAN-jeez):** Finger and toe bones.
- Pharyngeal (fah-rin-JE-al):** Pertaining to the pharynx (throat).
- Pharyngitis (fah-rin-JI-tis):** Inflammation of the pharynx (throat).
- Pharynx (FAR-inks):** Organ behind the mouth that receives swallowed food and delivers it into the esophagus. The pharynx (throat) also receives air from the nose and passes it to the trachea (windpipe).
- Phenothiazine (fe-no-THI-ah-zeen):** Substance whose derivatives are used as tranquilizers and antipsychotic agents to treat mental illness.
- Phlebitis (fleh-BI-tis):** Inflammation of a vein.
- Phlebography (fleh-BOG-rah-fe):** X-ray examination of veins after injection of contrast material.
- Phlebotomy (fleh-BOT-o-me):** Incision of a vein.
- Photoselective vaporization of the prostate (fo-to-se-LEK-tiv va-por-ih-ZA-shun of the PROS-tate):** Use of a GreenLight® laser to vaporize and remove prostatic tissue to treat benign prostatic hyperplasia.
- Phrenic (FREH-nik):** Pertaining to the DIAPHRAGM.
- Physical medicine and rehabilitation (FIZ-ih-kal MED-ih-sin and re-hah-bil-ih-TA-shun):** Field of medicine that specializes in restoring the function of the body after illness.
- Pilosebaceous (pi-lo-seh-BA-shus):** Pertaining to hair and its associated sebaceous gland.
- Pineal gland (pi-NE-al gland):** Small endocrine gland within the brain that secretes the hormone melatonin, whose exact function is unclear. In lower animals, the pineal gland is a receptor for light.
- Pituitary gland (pih-TOO-ih-tar-e gland):** Organ at the base of the brain that secretes hormones. These hormones enter the blood to regulate other organs and other endocrine glands.
- Platelet (PLAYT-let):** Clotting cell; a thrombocyte.

Pleura (PLOO-rah): Double membrane that surrounds the lungs. *Pleural* means pertaining to the pleura.

Pleural cavity (PLOO-ral KAH-vih-te): Space between each pleura surrounding the lung.

Pleural effusion (PLOO-ral e-FU-zhun): Collection of fluid between the double membrane surrounding the lungs.

Pleurisy (PLOO-rih-se): Inflammation of the PLEURA.

Pleuritis (plo-RI-tis): Inflammation of the PLEURA.

Pneumoconiosis (noo-mo-ko-ne-O-sis): Group of lung diseases resulting from inhalation of particles of dust such as coal, with permanent deposition of such particles in the lung.

Pneumonectomy (noo-mo-NEK-to-me): Removal of a lung.

Pneumonia (noo-MO-ne-ah): Abnormal condition of the lungs marked by inflammation and collection of material within the air sacs of the lungs.

Pneumonitis (noo-mo-NI-tis): Inflammation of a lung or lungs.

Pneumothorax (noo-mo-THOR-aks): Abnormal accumulation of air in the space between the pleura.

Polycythemia (pol-e-si-THE-me-ah): Increase in red blood cells. One form of polycythemia is polycythemia vera, in which the bone marrow produces an excess of erythrocytes and hemoglobin level is elevated.

Polydipsia (pol-e-DIP-se-ah): Excessive thirst.

Polyneuropathy (pol-e-nu-ROP-ah-the): Disease of many nerves.

Polyp (POL-ip): A growth or mass (benign) protruding from a mucous membrane.

Polyuria (pol-e-UR-e-ah): Excessive urination.

Pons (ponz): Part of the brain containing nerve pathways connecting upper and lower areas.

Posterior (pos-TEER-e-or): Located in the back portion of a structure or of the body.

Posteroanterior (pos-ter-o-an-TEER-e-or): Pertaining to direction from back to front.

Postmortem (post-MOR-tem): After death.

Postpartum (post-PAR-tum): After birth.

Precancerous (pre-KAN-ser-us): Pertaining to a condition that may come before a cancer; a condition that tends to become malignant.

Prenatal (pre-NA-tal): Pertaining to before birth.

Proctologist (prok-TOL-o-jist): Physician who specializes in the study of the anus and rectum.

Proctoscopy (prok-TOS-ko-pe): Inspection of the anus and rectum with a proctoscope (ENDOSCOPE). Proctoscopy is often performed before rectal surgery.

Proctosigmoidoscopy (prok-to-sig-moyd-OS-ko-pe): Visual examination of the anus, rectum, and sigmoid colon with an endoscope.

Progesterone (pro-JES-teh-rone): Hormone secreted by the ovaries to prepare to maintain the uterine lining during pregnancy.

Prognosis (prog-NO-sis): Prediction that forecasts the outcome of treatment. Prognosis literally means before (PRO-) knowledge (-GNOSIS).

Prolapse (pro-LAPS): Falling down or drooping of a part of the body. Prolapse literally means sliding (-LAPSE) forward (PRO-).

Prostate gland (PROS-tayt gland): Male gland that surrounds the base of the urinary bladder. It produces fluid (semen) that leaves the body with sperm cells.

Prostatectomy (pros-tah-TEK-to-me): Removal of the prostate gland.

Prostatic (pros-TAH-tik): Pertaining to the prostate gland.

Prostatic carcinoma (pros-TAH-tik kar-si-NO-mah): Malignant tumor arising from the PROSTATE GLAND. Also called *prostate cancer*.

Prostatic hyperplasia (pros-TAH-tik hi-per-PLA-zhah): Abnormal increase in growth (benign) of the prostate gland.

Prosthesis (pros-THE-sis): Artificial substitute for a missing part of the body. Prosthesis literally means to place (-THESIS) before (PROS-).

Prosthodontist (pros-tho-DON-tist): Dentist specializing in artificial appliances to replace missing teeth.

Proteinuria (pro-teen-U-re-ah): Abnormal condition of protein in the urine (albuminuria).

Psychiatrist (si-KI-ah-trist): Specialist in the treatment of the mind and mental disorders.

Psychiatry (si-KI-ah-tre): Treatment (IATR/O-) of disorders of the mind (PSYCH/O).

Psychology (si-KOL-o-je): Study of the mind, especially in relation to human behavior.

Psychosis (si-KO-sis): Abnormal condition of the mind; a serious mental disorder that involves loss of normal perception of reality (*plural*: psychoses [si-KO-seez]).

Pulmonary (PUL-mo-nair-e): Pertaining to the lungs.

Pulmonary artery (PUL-mo-nair-e AR-ter-e): Artery carrying blood from the right ventricle to the lungs.

Pulmonary circulation (PUL-mo-nair-e ser-ku-LA-shun): Passage of blood from the heart to the lungs and back to the heart.

Pulmonary edema (PUL-mo-nair-e eh-DE-mah): Abnormal collection of fluid in the lung (within the air sacs of the lung). Fluid backs up into lung tissue commonly from congestive heart failure as the heart weakens and is unable to pump blood effectively.

Pulmonary embolism (PUL-mo-nair-e EM-bo-lizm): Blockage of blood vessels in the lung by foreign matter (clot, tumor, fat, or air). The EMBOLUS frequently arises from the deep veins of the leg.

Pulmonary specialist (PUL-mo-nair-e SPESH-ah-list): Physician trained to treat lung disorders.

Pupil (PU-pil): Black center of the eye through which light enters.

Pyelitis (pi-eh-LI-tis): Inflammation of the renal pelvis (central section of the kidney).

Pyelogram (PI-eh-lo-gram): X-ray record of the renal pelvis after injection of contrast.

Q

Quadriplegia (kwad-rih-PLE-jah): Paralysis of all four extremities and usually the trunk of the body caused by injury to the spinal cord in the cervical region of the spine.

R

Radiation oncologist (ra-de-A-shun ong-KOL-o-jist): Physician trained in the treatment of disease (cancer) with high-energy x-rays or particles.

Radiation therapy (ra-de-A-shun THER-a-pe): Treatment of disease (cancer) with high-energy x-rays or particles (photons and protons). Also called RADIO THERAPY.

Radioisotope (ra-de-o-I-so-tope): See [RADIONUCLIDE](#).

Radiologist (ra-de-OL-o-jist): Physician trained in the use of x-rays (such as computed tomography and also including ultrasound) to diagnose illness.

Radiology (ra-de-OL-o-je): Science of using x-rays in the diagnosis of disease.

Radionuclide (ra-de-o-NOO-klid): A chemical substance that emits radioactivity; radioisotope. Radionuclides are used in nuclear medicine to image parts of the body.

Radiotherapist (ra-de-o-THER-ah-pist): Physician trained to treat disease (cancer) with high-energy x-rays or particles. See [RADIATION ONCOLOGIST](#).

Radiotherapy (ra-de-o-THER-ah-pe): Treatment of disease (cancer) with high-energy x-rays or particles such as photons and protons. Also called RADIO THERAPY.

Radius (RA-de-us): One of two lower arm bones. The radius is located on the thumb side of the

hand.

Rectal resection (REK-tal re-SEK-shun): Excision (resection) of the RECTUM.

Rectocele (REK-to-seel): Hernia (protrusion) of the rectum into the vagina.

Rectum (REK-tum): End of the colon. The rectum delivers wastes (feces) to the anus for elimination.

Relapse (RE-laps): Return of disease after its apparent termination.

Remission (re-MISH-un): Lessening or absence of signs and symptoms of a disease.

Renal (RE-nal): Pertaining to the kidney.

Renal calculus (RE-nal KAL-ku-lus): Kidney stone.

Renal failure (RE-nal FAIL-ur): Condition in which the kidneys no longer function.

Renal pelvis (RE-nal PEL-vis): Central section of the kidney, where urine collects.

Renal transplantation (RE-nal tranz-plan-TA-shun): A donor kidney is transferred to a recipient whose kidneys have failed.

Reproductive (re-pro-DUK-tiv): Pertaining to the process by which living things produce offspring.

Research (RE-surch): Laboratory investigation of a medical problem.

Resection (re-SEK-shun): Removal (excision) of an organ or a structure.

Residency training (RES-i-den-se TRAY-ning): Period of hospital work involving the care of patients after the completion of four years of medical school.

Respiratory system (RES-pir-ah-tor-e SIS-tem): Organs that control breathing, allowing air to enter and leave the body.

Retina (RET-ih-nah): Layer of sensitive cells at the back of the eye. Light is focused on the retina and then is transmitted to the optic nerve, which leads to the brain.

Retinopathy (reh-tih-NOP-ah-the): Disease of the RETINA.

Retrogastric (reh-tro-GAS-trik): Pertaining to behind the stomach.

Retroperitoneal (reh-tro-peh-rih-to-NE-al): Pertaining to behind the PERITONEUM.

Rhabdomyosarcoma (rab-do-mi-o-sar-KO-mah): Malignant tumor of muscle cells (skeletal, voluntary muscle) that occurs most frequently in the head and neck, extremities, body wall, and area behind the abdomen.

Rheumatoid arthritis (ROO-mah-toyd arth-RI-tis): Chronic inflammatory disease of the joints and connective tissue that leads to deformed joints.

Rheumatologist (roo-mah-TOL-o-jist): Specialist in the treatment of diseases of connective tissues, especially the joints. RHEUMAT/O- comes from the Greek *rheuma*, meaning "that which flows, as a stream or a river." Inflammatory disorders of joints are often marked by a collection of fluid in joint spaces.

Rheumatology (roo-mah-TOL-o-je): Branch of medicine dealing with inflammation, degeneration, or chemical changes in connective tissues, such as joints and muscles. Pain, stiffness, or limitation of motion are often characteristics of rheumatologic disorders.

Rhinitis (ri-NI-tis): Inflammation of the nose.

Rhinoplasty (RI-no-plas-te): Surgical repair of the nose.

Rhinorrhea (ri-no-RE-ah): Discharge from the nose.

Rhinotomy (ri-NOT-o-me): Incision of the nose.

Rib (rib): One of twelve paired bones surrounding the chest. Seven ribs (true ribs) attach directly to the breastbone, three (false ribs) attach to the seventh rib, and two (floating ribs) are not attached at all.

S

Sacral (SA-kral): Pertaining to the SACRUM.

Sacral region (SA-kral RE-jun): Five fused bones in the lower back, below the lumbar bones and wedged between two parts of the hip (ilium).

Sacrum (SA-krum): Triangular bone in the lower back, below the lumbar bones and formed by five fused bones.

Sagittal plane (SAJ-ih-tal playn): Imaginary plane that divides an organ or the body into right and left portions. The *mid-sagittal* plane divides a structure equally into right and left halves.

Sagittal section (SAJ-ih-tal SEK-shun): Cut (section) through the body, dividing it into a right and a left portion.

Salpingectomy (sal-pin-JEK-to-me): Removal of a fallopian (uterine) tube.

Salpingitis (sal-pin-JI-tis): Inflammation of a fallopian (uterine) tube.

Sarcoidosis (sahr-koy-DO-sis): Chronic, inflammatory disorder of cells in connective tissue, spleen, liver, bone marrow, lungs, and lymph nodes. Small collections of cells (granulomas) form in affected organs and tissues. The cause is unknown but may involve malfunction of the immune system.

Sarcoma (sar-KO-mah): Cancerous (malignant) tumor of connective tissue, such as bone, muscle, fat, or cartilage. The root SARC means flesh.

Scapula (SKAP-u-lah): Shoulder bone.

Sclera (SKLE-rah): White, outer coat of the eyeball.

Scotoma (sko-TO-mah): Defect in vision in a defined area (blind spot).

Scrotal (SKRO-tal): Pertaining to the scrotum.

Scrotum (SKRO-tum): Sac on the outside of the body that contains the testes.

Sebaceous gland (seh-BA-shus gland): Oil-producing (sebum-producing) gland in the skin.

Section (SEK-shun): Act of cutting; a segment or subdivision of an organ.

Seizure (SE-zhur): Convulsion (involuntary contraction of muscles) or attack of epilepsy. A seizure can also indicate a sudden attack or recurrence of a disease.

Sella turcica (SEL-ah TUR-sih-kah): Cup-like depression at the base of the skull that holds the pituitary gland.

Semen (SE-men): Fluid composed of sperm cells and secretions from the prostate gland and other male exocrine glands.

Seminoma (sem-ih-NO-mah): Malignant tumor of the testis.

Sense organs (sens OR-ganz): Parts of the body that receive messages from the environment and relay them to the brain so that we see, hear, and feel sensations. Examples of sense organs are the eye, the ear, and the skin.

Septic (SEP-tik): Pertaining to infection.

Septicemia (sep-tih-SE-me-ah): Infection in the blood. Septicemia is commonly called blood poisoning and is associated with the presence of bacteria or their toxins in the blood.

Sexually transmitted infection (SEK-shoo-ah-le trans-MIT-ed in-FEK-shun): Contagious disease acquired through sexual intercourse or genital contact.

Shock (shok): Group of symptoms (pale skin, rapid pulse, shallow breathing) that indicate poor oxygen supply to tissue and insufficient return of blood to the heart.

Sigmoid colon (SIG-moyd KO-len): S-shaped lower portion of the colon.

Sigmoidoscopy (sig-moyd-OS-ko-pe): Visual examination of the sigmoid colon with an endoscope inserted through the anus and rectum.

Sinus (SI-nus): Cavity or space, such as in a bone. Also refers to the sinoatrial node or pacemaker of the heart.

Skin (skin): Outer covering that protects the body.

Skull (skul): Bone that surrounds the brain and other organs in the head.

Sleep apnea (SLEEP AP-nee-ah): See [APNEA](#).

Small intestine (smal in-*TES*-tin): Organ that receives food from the stomach. The small intestine is divided into three sections: duodenum, jejunum, and ileum.

Sonogram (SON-o-gram): Record of sound waves after they bounce off organs in the body; an ULTRASOUND or echogram.

Spasm (SPAZ-um): Involuntary, sudden muscle contraction.

Spermatozoon (sper-mah-to-ZO-on): Sperm cell (*plural*: spermatozoa [sper-mah-to-ZO-ah]).

Spinal (SPI-nal): Pertaining to the spine (backbone).

Spinal cavity (SPI-nal KAV-ih-te): Space in the back that contains the spinal cord and is surrounded by the backbones.

Spinal column (SPI-nal KOL-um): Backbones; vertebrae.

Spinal cord (SPI-nal kord): Bundle of nerves that extends from the brain down the back. Spinal nerves carry electrical messages to and from the spinal cord.

Spinal nerves (SPI-nal nervz): Nerves that transmit messages to and from the spinal cord.

Spinal tap (SPI-nal TAP): See [LUMBAR PUNCTURE](#).

Spirometer (spi-ROM-eh-ter): Instrument for testing lung function by measuring the volume of inspired and expired air.

Spleen (spleen): Organ in the upper left part (quadrant) of the abdomen that produces white blood cells (LYMPHOCYTES) and disposes of old, dying red blood cells. The spleen, as part of the immune system, helps fight foreign organisms.

Splenectomy (spleen-EK-to-me): Removal of the spleen.

Splenomegaly (spleen-o-MEG-ah-le): Enlargement of the spleen.

Spondylitis (spon-dih-LI-tis): Chronic, serious inflammatory disorder of backbones involving erosion and collapse of vertebrae. See [ANKYLOSING SPONDYLITIS](#).

Spondylosis (spon-dih-LO-sis): Abnormal condition of a vertebra or vertebrae.

Sputum (SPU-tum): Material expelled from the lungs and expelled through the mouth.

Staging of tumors (STA-ging of TOO-morz): A system that describes the severity of a patient's cancer based on the extent of the original primary tumor and whether it has spread in the body.

Stent (stent): Tube inserted into an artery, blood vessel, or duct to keep it open.

Sternum (STER-num): Breastbone.

Stereotactic radiosurgery (steh-re-o-TAC-tic rad-e-o-SUR-je-re): This is a non-surgical type of radiation therapy used to treat abnormalities and small tumors of the brain. Also called Cyberknife©, this treatment can deliver precisely targeted radiation in fewer high-dose treatments than traditional therapy.

Stomach (STUM-ak): Organ that receives food from the esophagus and sends it to the small intestine. Enzymes in the stomach break down food particles during digestion.

Stomatitis (sto-mah-TI-tis): Inflammation of the mouth.

Stool culture (stool KUL-tur): Feces (stools) are placed in a growth medium (culture medium), which is later examined microscopically for evidence of microorganisms (such as bacteria).

Stool guaiac (stool GWI-ak) [test]: Examination of a small sample of stool for hidden traces of blood; HEMOCCULT TEST.

Stroke (strok): Condition resulting from trauma to or blockage of blood vessels within the brain; less blood arrives to nerve cells in the brain.

Stye (sti): Infection of a gland near the edge the eyelid, often caused by bacteria (staphylococci). Also spelled *sty*.

Subcostal (sub-KOS-tal): Pertaining to below the ribs.

Subcutaneous (sub-ku-TA-ne-us): Pertaining to under the skin.

Subcutaneous tissue (sub-ku-TA-ne-us TIS-u): Lower layer of the skin composed of fatty tissue.

Subdural hematoma (sub-DUR-al he-mah-TO-mah): Collection of blood under the dura mater (outermost layer of the membranes surrounding the brain).

Subgastric (sub-GAS-trik): Pertaining to below the stomach.

Subhepatic (sub-heh-PAT-ik): Pertaining to under the liver.

Subscapular (sub-SKAP-u-lar): Pertaining to under the shoulder bone.

Subtotal (sub-TO-tal): Less than total; often just under the total amount.

Subungual (sub-UN-gwal): Pertaining to under (SUB-) a nail (UNGU/O).

Suprarenal glands (soo-prah-RE-nal glanz): Two endocrine glands, each located above a kidney. See [ADRENAL GLANDS](#).

Surgery (SUR-jer-e): Branch of medicine that treats disease by manual (hand) or operative methods.

Sweat gland (swet gland): Organ in the skin that produces a watery substance containing salts.

Syncope (SING-koh-pe): Fainting; sudden loss of consciousness.

Syndrome (SYN-droh-m): Set of symptoms and signs that occur together to indicate a disease condition.

Syphilis (SIF-ih-lis): Sexually transmitted infection caused by spirochete (type of bacterium).

System (SIS-tem): Group of organs working together to do a job in the body. For example, the digestive system includes the mouth, throat, stomach, and intestines, all of which help to bring food into the body, break it down, and deliver it to the bloodstream.

Systemic circulation (sis-TEM-ik ser-ku-LA-shun): Passage of blood from the heart to the tissues of the body and back to the heart.

Systemic lupus erythematosus (sis-TEM-ik LOO-pus er-ih-the-mah-TO-sus): Chronic inflammatory disease affecting many systems of the body (joints, skin, kidneys, and nerves). A red (erythematous) rash over the nose and cheeks is characteristic.

T

Tachycardia (tak-eh-KAR-de-ah): Condition of a fast, rapid heartbeat.

Tachypnea (tak-ip-NE-ah): Condition of rapid breathing.

Tendinitis (ten-dih-NI-tis): Inflammation of a tendon.

Tendon (TEN-don): Connective tissue that joins muscles to bones.

Tenorrhaphy (ten-OR-ah-fe): Suture of a tendon.

Testicle (TES-tih-kl): See [TESTIS](#).

Testicular carcinoma (tes-TIK-u-lar kar-sih-NO-mah): Malignant tumor originating in a testis. An example is a SEMINOMA.

Testis (TES-tis): One of two paired male organs in the scrotal sac. The testes (*plural*) produce sperm cells and male hormone (testosterone). Also called a testicle.

Testosterone (tes-TOS-teh-rone): A hormone that produces male secondary sex characteristics; an ANDROGEN.

Thoracentesis (tho-rah-sen-TE-sis): Surgical puncture of the chest to remove fluid; thoracocentesis.

Thoracic (tho-RAS-ik): Pertaining to the chest.

Thoracic cavity (tho-RAS-ik KAV-ih-te): Space above the abdomen that contains the heart, lungs, and other organs; the chest cavity.

Thoracic region (tho-RAS-ik RE-jun): Twelve backbones attached to the ribs and located in the region of the chest, between the neck and the waist.

Thoracic surgeon (tho-RAS-ik SUR-jun): Physician who operates on organs in the chest.

Thoracic vertebra (tho-RAS-ik VER-teh-brah): A backbone in the region of the chest.

Thoracotomy (tho-rah-KOT-o-me): Incision of the chest.

Throat (throt): See PHARYNX.

Thrombocyte (THROM-bo-site): Clotting cell; a PLATELET.

Thrombolytic therapy (throm-bo-LIT-ik THER-ah-pe): Treatment with drugs such as streptokinase and tPA (tissue plasminogen activator) to dissolve clots that may cause a heart attack.

Thrombophlebitis (throm-bo-fleh-BI-tis): Inflammation of a vein accompanied by formation of a clot.

Thrombosis (throm-BO-sis): Abnormal condition of clot formation.

Thrombus (THROM-bus): Blood clot.

Thymoma (thi-MO-mah): Tumor (malignant) of the thymus gland.

Thymus gland (THI-mus gland): Lymphoid organ of the immune system. It is located in the chest between the lungs. It stimulates the production of LYMPHOCYTES (white blood cells).

Thyroadenitis (thi-ro-ah-deh-NI-tis): Inflammation of the thyroid gland.

Thyroidectomy (thi-roy-DEK-to-me): Removal of the thyroid gland.

Thyroid gland (THI-royd gland): Endocrine gland in the neck that produces hormones that act on cells all over the body. The hormones increase the activity of cells by stimulating metabolism and the release of energy.

Thyroid-stimulating hormone (THI-royd STIM-u-la-ting HOR-mone): Hormone secreted by the pituitary gland to stimulate the thyroid gland to produce its hormones, such as thyroxine. Also called TSH.

Thyroxine (thi-ROK-sin): Hormone secreted by the thyroid gland. Also known as T₄.

Tibia (TIB-e-ah): Larger of the two lower leg bones; the shin bone.

Tinnitus (TIN-ih-tus): Noise in the ears, such as ringing, roaring, or buzzing.

Tissue (TISH-u): Groups of similar cells that work together to do a job in the body. Examples are muscle tissue, nerve tissue, and epithelial (skin) tissue.

Tissue capillaries (TISH-u KAP-ih-lar-eez): Tiny blood vessels that lie near cells and through whose walls gases, food, and waste materials pass.

Tomography (to-MOG-rah-fe): Series of x-ray images that show an organ in depth by producing images of single tissue planes.

Tomosynthesis (to-mo-SIN-theh-sis): New mammographic technique that shows clearer and more detailed images.

Tonsillectomy (ton-sih-LEK-to-me): Removal (excision) of a tonsil or TONSILS.

Tonsillitis (ton-sih-LI-tis): Inflammation of the TONSILS.

Tonsils (TON-silz): Lymphatic tissue in the back of the mouth near the throat.

Trachea (TRA-ke-ah): Tube that carries air from the throat to the BRONCHIAL TUBES; the windpipe.

Tracheitis (tra-ke-I-tis): Inflammation of the trachea.

Tracheostomy (tra-ke-OS-to-me): Opening of the trachea to the outside of the body.

Tracheotomy (tra-ke-OT-o-me): Incision of the trachea.

Transabdominal (tranz-ab-DOM-ih-nal): Pertaining to across the abdomen.

Transdermal (tranz-DER-mal): Pertaining to through the skin.

Transgastric (tranz-GAS-trik): Pertaining to across (through) the stomach.

Transhepatic (tranz-he-PAH-tik): Pertaining to across or through the liver.

Transurethral (tranz-u-RE-thral): Pertaining to across (through) the urethra. TURP is transurethral resection of the prostate gland by surgery through the urethra.

Transvaginal ultrasound (tranz-VAH-jin-al UL-trah-sound): A sound probe is placed in the vagina and ultrasound images are made of the pelvic organs (uterus and ovaries).

Transverse plane (tranz-VERS playn): Imaginary plane that divides an organ or the body into an upper and a lower portion; a cross-sectional view.

Trichotillomania (trik-o-til-o-MAN-e-ah): Obsessive-compulsive disorder marked by the urge to pull out (TILL/O) one's hair.

Tricuspid valve (tri-KUS-pid valv): Fold of tissue between the upper and lower chambers on the right side of the heart. It has three cusps or points and prevents backflow of blood into the right ATRIUM when the heart is pumping blood.

Triglyceride (tri-GLIS-eh-ride): Fat consisting of three molecules of fatty acid and glycerol. It makes up most animal and vegetable fats and is the major lipid (fat) in blood.

Tubal ligation (TOO-bul li-GA-shun): Fallopian tubes are tied off (ligated) with sutures.

Tuberculosis (too-ber-ku-LO-sis): Infectious, inflammatory disease that commonly affects the lungs, although it can occur in any part of the body. It is caused by the tubercle bacillus (type of bacterium).

Tympanic membrane (tim-PAN-ik MEM-brayn): See [EARDRUM](#).

Tympanoplasty (tim-pan-o-PLAS-te): Surgical repair of the eardrum.

U

Ulcer (UL-ser): Sore or defect in the surface of an organ. Ulcers (hollowed-out spaces) are produced by destruction of tissue.

Ulcerative colitis (UL-seh-rah-tiv ko-LI-tis): Recurrent inflammatory disorder marked by ulcers in the large bowel. Along with Crohn disease, ulcerative colitis is an INFLAMMATORY BOWEL DISEASE.

Ulna (UL-nah): One of two lower arm bones. The ulna is located on the little finger side of the hand.

Ultrasonography (ul-trah-so-NOG-rah-fe): Recording of internal sound waves as they impact body structures.

Ultrasound (UL-tra-sownd): Sound waves with greater frequency than can be heard by the human ear. This energy is used to detect abnormalities by beaming the waves into the body and recording echoes that reflect off tissues.

Unilateral (u-nih-LAT-er-al): Pertaining to one side.

Upper gastrointestinal (GI) series (UP-er gas-tro-in-TES-tin-al SEER-eez): Barium is swallowed, and x-ray images are taken of the esophagus, stomach, and small intestine.

Urea (u-RE-ah): Chief nitrogen-containing waste that the kidney removes from the blood and eliminates from the body in urine.

Uremia (u-RE-me-ah): Abnormal condition of excessive amounts of urea (nitrogenous waste) in the bloodstream.

Ureter (YOOR-eh-ter or u-RE-ter): One of two tubes that lead from the kidney to the urinary bladder.

Ureterectomy (u-re-ter-EK-to-me): Removal (excision) of a ureter.

Urethra (u-RE-thrah): Tube that carries urine from the urinary bladder to the outside of the body. In males, the urethra, which is within the penis, also carries sperm from the VAS DEFERENS to the outside of the body when sperm are discharged (ejaculation).

Urethral stricture (u-RE-thral STRIK-shur): Narrowing of the urethra.

Urethritis (u-re-THRI-tis): Inflammation of the urethra.

Uric acid (U-rik acid): Nitrogen-containing waste material from breakdown of nucleic acids (DNA and RNA). It is normally filtered from the blood by the kidneys and passes out of the body in urine. High levels of uric acid in the blood are an indication of GOUT, a type of arthritis.

Urinalysis (u-rih-NAL-ih-sis): Examination of urine to determine its contents.

Urinary bladder (UR-in-air-e BLA-der): Muscular sac that holds urine and then releases it to leave the body through the urethra.

Urinary catheterization (UR-in-air-e kath-eh-ter-ih-ZA-shun): Catheter (tube) is passed through

the urethra into the urinary bladder for short- or long-term drainage of urine.

Urinary retention (UR-in-air-e re-TEN-shun): Condition in which urine is unable to leave the urinary bladder.

Urinary system (UR-in-air-e SIS-tem): Organs that produce and send urine out of the body. These organs are the kidneys, ureters, bladder, and urethra.

Urinary tract (UR-in-air-e trakt): Tubes and organs that carry urine from the kidney to the outside of the body.

Urine (UR-in): Fluid that is produced by the kidneys, passed through the ureters, stored in the bladder, and released from the body through the urethra.

Urologist (u-ROL-o-jist): Specialist in operating on the urinary tract in males and females and on the reproductive tract in males.

Urology (u-ROL-o-je): Study of the urinary tract (surgical specialty).

Uterine (U-ter-in): Pertaining to the uterus.

Uterine artery embolization (U-ter-in AR-ter-e em-bo-lih-ZA-shun): Blockage of blood flow in the uterine artery to slow the growth of uterine fibroids.

Uterine tubes (U-ter-in toobz): See [FALLOPIAN TUBES](#).

Uterus (U-ter-us): Muscular organ in a female that holds and provides nourishment for the developing fetus; the WOMB.

V

Vagina (vah-JI-nah): Muscular passageway from the uterus to the outside of the body.

Vaginitis (vah-jih-NI-tis): Inflammation of the vagina.

Valve (valv): Natural structure or artificial device that prevents backward flow of fluid (such as blood).

Varicocele (VAR-ih-ko-seel): Abnormal enlargement of veins in the SCROTUM. This condition produces a swelling that feels like a “bag of worms.”

Varix (VAH-riks): An enlarged, swollen, tortuous vein (*plural*: varices [VAH-rih-seez]).

Vas deferens (vas DEF-er-enz): One of two tubes that carry sperm from the testes to the urethra for ejaculation.

Vascular (VAS-ku-lar): Pertaining to blood vessels.

Vasculitis (vas-ku-LI-tis): Inflammation of blood vessels.

Vasectomy (vas-EK-to-me): Removal of a portion of the vas deferens so that sperm cells are prevented from becoming part of SEMEN.

Vasoconstrictor (vas-o-kon-STRIK-tor): Drug that narrows blood vessels, especially small arteries.

Vasodilator (vas-o-DI-la-tor): Agent that widens blood vessels.

Vein (van): Blood vessel that carries blood back to the heart from tissues of the body.

Ventricle (VEN-trih-kl): One of the two lower chambers of the heart. The right ventricle receives blood from the right atrium (upper chamber) and sends it to the lungs. The left ventricle receives blood from the left atrium and sends it to the body through the aorta.

Ventricular arrhythmia (ven-TRIK-u-lar ah-RITH-me-ah): Abnormal heart rhythm originating in the lower chambers of the heart.

Venule (VEN-ul): Small vein.

Venulitis (ven-u-LI-tis): Inflammation of a small vein.

Vertebra (VER-teh-brah): Backbone.

Vertebrae (VER-teh-bray): Backbones.

Vertebral (VER-teh-bral): Pertaining to a backbone.

Vertebroplasty (ver-teh-bro-PLAS-te): Surgical repair of backbone fractures by injecting cement

into vertebrae to strengthen them and relieve pain.

Vesical (VES-ih-kal): Pertaining to the urinary bladder (VESIC/O).

Vitreous humor (VIT-re-us HU-mor): Transparent clear gel that fills the space between the lens and the retina of the eye.

Virtual colonoscopy (VER-choo-al ko-lon-OS-ko-pe): See [CT COLONOGRAPHY](#).

Virus (VI-rus): Small infectious agent that can reproduce itself only when it is inside another living cell (host).

Visceral (VIS-er-al): Pertaining to internal organs.

W

Womb (woom): See [UTERUS](#).

Wound (woond): Any physical injury involving a break in the skin (chest wound, gunshot wound, puncture wound, and so on).



GLOSSARY 2

Word Parts

Section I: Medical Terminology → English [386](#)

Section II: English → Medical Terminology [394](#)

Section I of this glossary is a list of **medical terminology word parts** and their **English meanings**. Section II is the reverse of that list, giving **English meanings** and their corresponding **medical terminology word parts**. Section II begins on page 394.

Section I: Medical Terminology → English

Word Part	Meaning
a-, an-	no, not
ab-	away from
abdomin/o	abdomen; <i>see also</i> lapar/o
-ac	pertaining to
ad-	toward
aden/o	gland
adenoid/o	adenoids
adren/o	adrenal gland
-al	pertaining to
-algia	condition of pain; <i>see also</i> -dynia
alveol/o	alveolus (air sac within the lung)
amni/o	amnion (sac that surrounds the embryo)
-an	pertaining to
ana-	up, apart
an/o	anus
angi/o	vessel (blood)
ante-	before, forward
anter/o	front
anti-	against
aort/o	aorta
append/o, appendic/o	appendix
-ar	pertaining to
arteri/o	artery
arteriol/o	small artery
arthr/o	joint
-ary	pertaining to
ather/o	fatty plaque
-ation	process, condition
aur/o	ear; <i>see also</i> ot/o
aut-	self
axill/o	armpit
balan/o	penis
bari/o	weight
bi-	two
bi/o	life
blephar/o	eyelid
brady-	slow
bronch/o	bronchial tube
bronchiol/o	small bronchial tube
calcane/o	calcaneus (heel bone)
capillar/o	capillary
carcin/o	cancer, cancerous
cardi/o	heart
carp/o	wrist bones (carpals)
-cele	hernia
-centesis	surgical puncture to remove fluid
cephal/o	head
cerebell/o	cerebellum (posterior part of the brain)
cerebr/o	cerebrum (largest part of the brain)
cervic/o	neck
chem/o	drug, chemical
cholecyst/o	gallbladder
choledoch/o	common bile duct
chondr/o	cartilage
chron/o	time
-cision	process of cutting
cis/o	to cut
clavicul/o	clavicle (collarbone)
-coccus	bacterium (berry-shaped); <i>plural: -cocci</i>
coccyg/o	tailbone
col/o	colon (large intestine)
colon/o	colon
colp/o	vagina
comi/o	to care for
con-	with, together
coni/o	dust
-coniosis	abnormal condition of dust

contra-	against
coron/o	heart
cost/o	rib
crani/o	skull
crin/o	secrete
-crine	secretion
-crit	separation
cry/o	cold
cutane/o	skin
cyan/o	blue
cyst/o	urinary bladder
-cyte	cell
cyt/o	cell
dactyl/o	fingers or toes
de-	away from, down
dent/i	tooth
dermat/o, derm/o	skin
dia-	complete, through
-dipsia	thirst
duoden/o	duodenum
dur/o	dura mater (outermost meningeal layer)
-dynia	pain
dys-	abnormal, bad, difficult, painful
-eal	pertaining to
ec-	out, outside
-ectasia, -ectasis	dilation, stretching, widening
ecto-	out, outside
-ectomy	excision (resection, removal); process of cutting out
electr/o	electricity
-emesis	vomiting
-emia	blood condition
en-	in, inner, within
encephal/o	brain
endo-	within, in, inner
endocrin/o	endocrine glands
endometr/o, endometri/o	endometrium (inner lining of the uterus)
enter/o	intestines (usually small intestine)
epi-	above, upon
epiglott/o	epiglottis
epitheli/o	skin (surface tissue)
erythr/o	red
esophag/o	esophagus
esthesi/o	sensation
eu-	good (normal)
ex-, exo-, extra-	out, outside
femor/o	femur, thigh bone
fibr/o	fibrous tissue
fibul/o	fibula (smaller lower leg bone)
gastr/o	stomach
gen/o	to produce
-gen	production, formation
-genesis	producing, forming
-genic	pertaining to producing, produced by
ger/o	old age
-globin	protein
glyc/o	sugar
gnos/o	knowledge
-gram	record
-graph	instrument to record
-graphy	process of recording, to record
gynec/o	woman, female
hemat/o, hem/o	blood
hepat/o	liver
humer/o	humerus (upper arm bone)
hydr/o	water
hyper-	excessive, more than normal, too much, above
hypo-	below, deficient, less than normal, too little
hypophys/o	pituitary gland
hyster/o	uterus
-ia	condition
-ian	practitioner
iatr/o	treatment

-ic, -ical	pertaining to
ile/o	ileum (third part of small intestine)
ili/o	ilium (upper part of hip bone)
in-	in, into
-ine	pertaining to
infra-	below
inguin/o	groin
inter-	between
intra-	within
-ior	pertaining to
isch/o	to hold back
-ism	condition, process
-ist	specialist
-itis	inflammation
jejun/o	jejunum
lapar/o	abdomen
-lapse	slide
laryng/o	larynx (voice box)
later/o	side
ligament/o	ligament
leiomy/o	smooth muscle
leuk/o	white
lip/o	fat
-listhesis	sliding
lith/o	stone
-lith	stone
-logist	specialist in the study of
-logy	process of study, study of
lumb/o	loin, waist region
lymph/o	lymph
lymphaden/o	lymph nodes
lymphangi/o	lymph vessel
lys/o	breakdown, destruction, separation
-lysis	breakdown, destruction, separation
macro-	large
mal-	bad
-malacia	softening
mamm/o	breast
mast/o	breast
mediastin/o	mediastinum
medull/o	medulla oblongata (lower part of the brain)
-megaly	enlargement
men/o	menstruation
mening/o	meninges (membranes covering brain and spinal cord)
meta-	beyond, change
metacarp/o	metacarpals (hand bones)
metatars/o	metatarsals (foot bones)
-meter	measure
metr/o, metri/o	uterus; to measure
-metry	measurement
micro-	small
-mortem	death
-motor	movement
multi-	many
muscul/o	muscle
my/o	muscle
myel/o	bone marrow (with -blast-, -cyte, -genous, -oma)
myel/o	spinal cord (with -cele, -gram, -itis)
myos/o	muscle
myring/o	eardrum
nas/o	nose
nat/i	birth
necr/o	death
neo-	new
nephr/o	kidney
neur/o	nerve
norm/o	rule, order
nos/o	disease
nulli-	none
obstetr/o	midwife
ocul/o	eye
odont/o	tooth

-oid	pertaining to, resembling
-oma	tumor, mass, swelling
onc/o	tumor (cancerous)
onycho/o	nail
o/o	egg
oophor/o	ovary
ophthalm/o	eye
-opsy	to view; process of viewing
opt/o, optic/o	eye
or/o	mouth
orch/o	testicle, testis
orchi/o	testicle, testis
orchid/o	testicle, testis
orth/o	straight
-osis	abnormal condition
osm/o	smell
oste/o	bone
ot/o	ear
-ous	pertaining to
ovari/o	ovary
pan-	all
pancreat/o	pancreas
para-	along the side of, beside, near
parathyroid/o	parathyroid gland
-partum	birth
path/o	disease
-pathy	disease condition
ped/o	child
pelv/o	hip bone
-penia	deficiency
per-	through
peri-	surrounding
peritone/o	peritoneum (membrane around abdominal organs)
perone/o	fibula
-pexy	fixation (surgical)
phak/o	lens of the eye
phalang/o	phalanges (finger and toe bones)
pharyng/o	pharynx, throat
-phasia	speech
-philia	attraction to
phleb/o	vein
phren/o	diaphragm
phren/o	mind
physi/o	function
pituitar/o	pituitary gland
plas/o	development, formation, growth
-plasm	development, formation, growth
-plasia	formation, growth
-plasty	surgical repair
-plegia	paralysis
pleur/o	pleura (membranes surrounding the lungs)
-pnea	breathing
pneum/o	air, lung
pneumon/o	lung
-poiesis	formation
poly-	many, much
post-	after, behind
poster/o	back, behind
pre-	before
pro-, pros-	before, forward
prosth/o	artificial replacement
proct/o	anus and rectum
prostat/o	prostate gland
psych/o	mind
-ptosis	prolapse, sagging
-ptysis	spitting
pulmon/o	lung
pyel/o	renal pelvis (central section of the kidney)
radi/o	x-ray; radius (lateral lower arm bone)
re	back
rect/o	rectum
ren/o	kidney

retin/o	retina of the eye
retro-	behind
rhabdomy/o	striated (skeletal) muscle
rheumat/o	flow, fluid
rhin/o	nose
-rrhage	excess flow of blood
-rrhagia	excess flow of blood
-rrhaphy	suture
-rrhea	discharge, flow
sacr/o	sacrum
salping/o	fallopian (uterine) tube; eustachian tube
-salpinx	fallopian (uterine) tube; eustachian tube
sarc/o	flesh
scapul/o	shoulder blade (bone)
-sclerosis	hardening
-scope	instrument to view or visually examine
-scopy	process of visual examination
scrot/o	scrotal sac, scrotum
-section	process of cutting into
sept/o	infection
septic/o	infection
-sis	state of; condition
-somatic	pertaining to the body
son/o	sound
-spasm	constriction
spin/o	backbone, spine, vertebra
splen/o	spleen
spondyl/o	backbone, vertebra
-stasis	control, stop; place, to stand
-stat	stop, control
-stenosis	narrowing
stern/o	sternum (breastbone)
stomat/o	mouth
-stomy	opening
sub-	below, under
supra-	above
syn-	with, together (use before b, p, and m)
syn-	with, together
tachy-	fast
tendin/o, ten/o	tendon
-tension	pressure
theli/o, thel/o	nipple
-therapy	treatment
-thesis	put, place
thorac/o	chest
thromb/o	clotting, clot
thym/o	thymus gland
thyr/o, thyroid/o, thyroaden/o	thyroid gland
tibi/o	tibia or shin bone (larger lower leg bone)
-tic	pertaining to
-tomy	process of cutting into, incision
tonsill/o	tonsils
top/o	to put, place
trache/o	trachea, windpipe
trans-	across, through
tri-	three
troph/o	development, nourishment
-trophy	development, nourishment
tympan/o	eardrum
uln/o	ulna (medial lower arm bone)
ultra-	beyond
-um	structure
ungu/o	nail
uni-	one
ureter/o	ureter
urethr/o	urethra
ur/o	urine, urinary tract
-uria	urine condition
uter/o	uterus
vagin/o	vagina
vas/o	vas deferens, vessel
vascul/o	blood vessel

ven/o	vein
venul/o	venule
vertebr/o	backbone, vertebra
vesic/o	urinary bladder
-y	condition, process

Section II: English → Medical Terminology

Meaning	Word Part
abdomen	abdomin/o (<i>use with -al, -centesis</i>)
	lapar/o (<i>use with -scope, -scopy, -tomy</i>)
abnormal	dys-
abnormal condition	-osis
abnormal condition of dust	-coniosis
above	epi-, hyper-, supra-
across	trans-
adenoids	adenoid/o
adrenal gland	adren/o
after	post-
against	anti-, contra-
air	pneum/o
air sac	alveol/o
all	pan-
along the side of	para-
alveolus	alveol/o
amnion	amni/o
anus	an/o
anus and rectum	proct/o
aorta	aort/o
apart	ana-
appendix	append/o (<i>use with -ectomy</i>)
	appendic/o (<i>use with -itis</i>)
armpit	axill/o
artery	arteri/o
artificial replacement	prosth/o
attraction to	-philia
away from	ab-, de-
back	poster/o, re-, retro-
backbone	spin/o (<i>use with -al</i>)
	spondyl/o (<i>use with -itis, -listhesis, -osis, -pathy</i>)
	vertebr/o (<i>use with -al</i>)
bacterium (berry-shaped)	-coccus (<i>plural: -cocci</i>)
bad	dys-, mal-
before	ante-, pre-, pro-, pros-
behind	post-, poster/o, re-, retro-
below	hypo-, infra-, sub-
beside	para-
between	inter-
beyond	meta-, ultra-
birth	nat/i, -partum
bladder (urinary)	cyst/o (<i>use with -ic, -itis, -cele, -gram, -scopy</i>)
	vesic/o (<i>use with -al, -stomy, -tomy</i>)
blood	hem/o (<i>use with -cyte, -dialysis, -globin, -lysis, -philia, -ptysis, -rrhage, -stasis, -stat</i>)
	hemat/o (<i>use with -crit, -emesis, -logist, -logy, -oma, -poiesis, -salpinx, -uria</i>)
blood condition	-emia
blood flow, excess	-rrhage, -rrhagia
blood vessel	angi/o (<i>use with -ectomy, -dysplasia, -genesis, -gram, -graphy, -oma, -plasty, -spasm</i>)
	vas/o (<i>use with -constriction, -dilation, -dilatation, -motor</i>)
	vascul/o (<i>use with -ar, -itis</i>)
blue	cyan/o
body	-somatic
bone	oste/o
bone marrow	myel/o
brain	encephal/o
breakdown	-lysis, lys/o
breast	mamm/o (<i>use with -ary, -gram, -graphy, -plasty</i>)
	mast/o (<i>use with -algia, -ectomy, -itis</i>)
breastbone	stern/o
breathing	-pnea
bronchial tube	bronch/o
bronchiole	bronchiol/o
calcaneus	calcane/o
cancer	carcin/o
cancerous	carcin/o
capillary	capillar/o
care for (to)	comi/o

carpals	carp/o
cartilage	chondr/o
cell	-cyte, cyt/o
cerebellum	cerebell/o
cerebrum	cerebr/o
change	meta-
chemical	chem/o
chest	thorac/o
child	ped/o
clavicle	clavicul/o
clotting, clot	thromb/o
cold	cry/o
collarbone	clavicul/o
colon	col/o (use with -ectomy, -itis, -stomy) colon/o (use with -pathy, -scope, -scopy)
common bile duct	choledoch/o
complete	dia-
condition	-ation, -ia, -ism, -osis, -sis, -y
condition of blood	-emia
constriction	-spasm
control	-stasis, -stat
cut	-cision, cis/o, -section, -tomy
death	-mortem, nect/o
deficiency	-penia
deficient	hypo-
destruction	lys/o, -lysis
development	plas/o, -plasm, troph/o, -trophy
dilation	-ectasia, -ectasis
diaphragm	phren/o
difficult	dys-
discharge	-rrhea
disease	nos/o; path/o, -pathy
drug	chem/o
duodenum	duoden/o
dura mater	dur/o
dust	coni/o
dust condition	-coniosis
ear	aur/o, ot/o
eardrum	myring/o (use with -ectomy, -itis, -tomy) tympan/o (use with -ic, -metry, -plasty)
egg	o/o
electricity	electr/o
endocrine gland	endocrin/o
endometrium	endometri/o
enlargement	-megaly
epiglottis	epiglott/o
esophagus	esophag/o
eustachian tube	salping/o, -salpinx
excessive	hyper-
excision	-ectomy
eye	ocul/o (use with -ar, -facial, -motor) ophthalm/o (use with -ia, -ic, -logist, -logy, -pathy, -plasty, -plegia, -scope, -scopy) opt/o (use with -ic, -metrist) optic/o (use with -ian)
eyelid	blephar/o
fallopian tube	salping/o, -salpinx
fast	tachy-
fat	lip/o
fatty plaque	ather/o
female	gynec/o
femur	femor/o
fibrous tissue	fibr/o
fibula	fibul/o, perone/o
fingers	dactyl/o
fixation (surgical)	-pexy
flesh	sarc/o
flow	-rrhea, rheumat/o
fluid	rheumat/o
foot bones	metatars/o
formation	-genesis, -plasia, plas/o, -plasm, -poiesis
forward	ante-, pro-, pros-
front	anter/o

function	physi/o
gallbladder	cholecyst/o
gland	aden/o
good	eu-
groin	inguin/o
growth	plas/o, -plasm
hand bones	metacarp/o
hardening	-sclerosis
head	cephal/o
heart	cardi/o (use with -ac, -graphy, -logy, -logist, -megaly, -pathy, -vascular) coron/o (use with -ary)
heel bone	calcane/o
hernia	-cele
hip bone	pelv/o
hold back (to)	isch/o
humerus	humer/o
ileum	ile/o
ilium	ili/o
in, into	in-, en-, endo-
incision	-section, -tomy
infection	sept/o, septic/o
inflammation	-itis
inner	en-, endo-
instrument to record	-graph
instrument to visually examine	-scope
intestines (small)	enter/o
jejunum	jejun/o
joint	arthr/o
kidney	neph/r/o (use with -algia, -ectomy, -ic, -itis, -lith, -logy, -megaly, -oma, -osis, -pathy, -ptosis, -sclerosis, -stomy, -tomy) ren/o (use with -al, -gram)
kidney (central section)	pyel/o
knowledge	gnos/o
large	macro-
larynx	laryng/o
lens of the eye	phak/o
less than normal	hypo-
life	bi/o
ligament	ligament/o
liver	hepat/o
loin	lumb/o
lung	pneum/o (use with -coccus, -coniosis, -thorax) pneumon/o (use with -ectomy, -ia, -ic, -itis, -pathy) pulmon/o (use with -ary)
lymph	lymph/o
lymph node	lymphaden/o
lymph vessel	lymphangi/o
mass	-oma
many	poly-, multi-
measure (to)	meter, metr/o, metry
mediastinum	mediastin/o
medulla oblongata	medull/o
meninges	mening/o
menstruation	men/o
metacarpals	metacarp/o
metatarsals	metatars/o
midwife	obstetr/o
mind	psych/o, phren/o
more than normal	hyper-
mouth	or/o (use with -al) stomat/o (use with -itis)
movement	-motor
much	poly-
muscle	muscul/o (use with -ar, -skeletal) myos/o (use with -itis) my/o (use with -algia, -ectomy, -oma, -gram, -neural)
nail	onych/o (use with -lysis), ungu/o (use with -al)
narrowing	-stenosis
near	para-
neck	cervic/o
nerve	neur/o
new	neo-
nipple	thel/o, theli/o

no, not	a-, an-
none	nulli-
nose	nas/o (<i>use with -al</i>) rhin/o (<i>use with -itis, -rrhea, -plasty</i>)
nourishment	troph/o, -trophy
old age	ger/o
one	uni-
opening	-stomy
order	norm/o
out, outside	ec-, ecto-, ex-, exo- extra-
ovary	oophor/o (<i>use with -itis, -ectomy, -pexy, -plasty, -tomy</i>) ovari/o (<i>use with -an</i>)
pain	-algia, -dynia
painful	dys-
pancreas	pancreat/o
paralysis	-plegia
parathyroid gland	parathyroid/o
pelvis	pelv/o
pelvis (renal)	pyel/o
penis	balan/o
peritoneum	peritone/o
pertaining to	-ac, -al, -an, -ar, -ary, -eal, -ic, -ine, -ior, -oid, -ous, -tic
pertaining to the body	-somatic
phalanges	phalang/o
pharynx	pharyng/o
pituitary gland	hypophys/o, pituitar/o
place	top/o, -stasis
pleura	pleur/o
practitioner	-ian
pressure	-tension
process	-ation, -ism, -y
process of cutting into	-cision, -tomy, -section
process of cutting out	-ectomy
process of recording	-graphy
process of viewing	-opsy
produce (to)	-gen, gen/o
produced by	-genic
producing	-genic, -genesis
prolapse	-ptosis
prostate gland	prostat/o
puncture to remove fluid	-centesis
put, place (to)	-thesis, top/o
radius (lower arm bone)	radi/o
record	-gram
recording (process)	-graphy
rectum	rect/o
red	erythr/o
removal	-ectomy
renal pelvis	pyel/o
repair	-plasty
resection	-ectomy
resembling	-oid
retina of the eye	retin/o
rib	cost/o
rule	norm/o
sacrum	sacr/o
sagging	-ptosis
scapula	scapul/o
scrotum, scrotal sac	scrot/o
secrete, secretion	-crine, crin/o
self	aut-
sensation	esthesi/o
separation	-crit, -lysis, lys/o
shin bone	tibi/o
shoulder blade	scapul/o
side	later/o
skin	cutane/o (<i>use with -ous</i>) derm/o (<i>use with -al</i>); dermat/o (<i>use with -itis, -logy, -osis</i>) epitheli/o (<i>use with -al</i>)
skull	crani/o
sliding	-lapse, -listhesis
slip (to)	-listhesis

slow	brady-
small	micro-
small artery	arteriol/o
small bronchial tube	bronchiol/o
small intestine	enter/o
smell	osm/o
smooth muscle	leiomy/o
softening	-malacia
sound	son/o
specialist	-ist
specialist in the study of	-logist
speech	-phasia
spinal cord	myel/o
spine	spin/o
spitting	-ptysis
spleen	splen/o
stand (to)	-stasis
state of	-sis
sternum	stern/o
stomach	gastr/o
stone	lith/o, -lith
stop	-stasis, -stat
straight	orth/o
stretching	-ectasia, -ectasis
striated (skeletal) muscle	rhabdomy/o
structure	-um
study of	-logy
sugar	glyc/o
surgical puncture to remove fluid	-centesis
surgical repair	-plasty
surrounding	peri-
suture	-rrhaphy
swelling	-oma
tailbone	coccyg/o
tendon	tendin/o, ten/o
testicle, testis	orch/o, orchi/o, orchid/o
thigh bone	femor/o
thirst	-dipsia
throat	pharyng/o
three	tri-
through	dia-, per-, trans-
thymus gland	thym/o
thyroid gland	thyr/o, thyroid/o, thyroaden/o
tibia	tibi/o
time	chron/o
toes	dactyl/o
together	con-, syn-, sym-
tonsil	tonsill/o
too much	hyper-
too little	hypo-
tooth	dent/i, odont/o
toward	ad-
trachea	trache/o
treatment	iatr/o, -therapy
tumor	-oma, onc/o
two	bi-
ulna	uln/o
under	hypo-, sub-
up	ana-
upon	epi-
ureter	ureter/o
urethra	urethr/o
urinary bladder	cyst/o, vesic/o
urinary tract	ur/o
urine	ur/o
urine condition	-uria
uterus	hyster/o (use with -ectomy, -graphy, -gram)
	metr/o (use with -itis, -rrhagia)
	metri/o (use with -al)
	uter/o (use with -ine)
uterus (inner lining)	endometr/o, endometri/o
vagina	colp/o (use with -pexy, -plasty, -scope, -scopy, -tomy)

	vagin/o (<i>use with -al, -itis</i>)
vas deferens	vas/o
vein	phleb/o (<i>use with -ectomy, -itis, -lith, -thrombosis, -tomy</i>) ven/o (<i>use with -ous, -gram</i>)
venule	venul/o
vertebra	spin/o (<i>use with -al</i>) spondyl/o (<i>use with -itis, -listhesis, -osis, -pathy</i>) vertebr/o (<i>use with -al</i>)
vessel	angi/o (<i>use with -ectomy, -dysplasia, -genesis, -gram, -graphy, -oma, -plasty, -spasm</i>) vas/o (<i>use with -constriction, -dilation, -motor</i>) vascul/o (<i>use with -ar, -itis</i>)
view (to)	-opsy
visual examination	-scopy
voice box	laryng/o
vomiting	-emesis
waist region	lumb/o
water	hydr/o
weight	bari/o
white	leuk/o
widening	-ectasia, -ectasis
windpipe	trache/o
with	con-, syn-, sym-
within	en-, endo-, intra-
woman	gynec/o
wrist bones	carp/o
x-ray	radi/o



GLOSSARY 3

English → Spanish Terms*

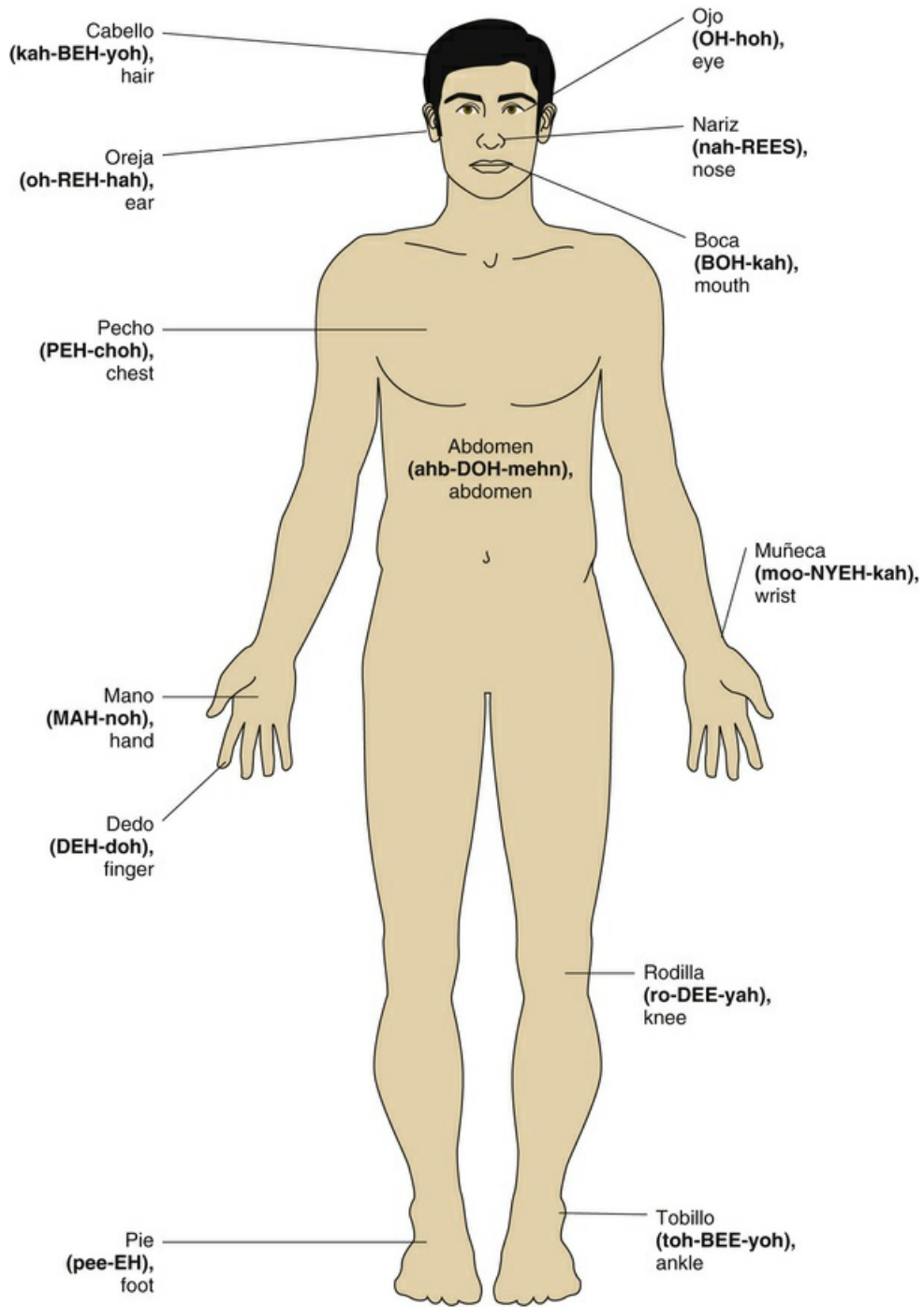
Here is a list of **English** → **Spanish terms** that will help you communicate with Spanish-speaking patients in offices, hospitals, and other medical settings. Included are parts of the body and other medical terms as well.

abdomen	abdomen (ahb-DOH-mehn)
acne	acné (ahk-NEH)
acoustic	acústico (ah-KOOS-tee-ko)
adenoid	adenoides (ah-deh-NOH-ee-deh)
amebic	améxico (ah-MEH-bee-ko)
analgesic	analgésico (ah-nahl-HEH-see-koh)
anemia	anemia (ah-NEH-mee-ah)
anesthesia	anestesia (ah-nehs-TEH-see-ah)
angina	angina (ahn-HEE-na)
angioma	angioma (ahn-hee-OH-mah)
ankle	tobillo (toh-BEE-yoh)
antacid	antiácido (ahn-tee-AH-see-doh)
antiarrhythmic	antiarrítmico (ahn-tee-ah-RREET-mee-koh)
antibiotic	antibiótico (ahn-tee-bee-OH-tee-koh)
anticonvulsant	anticonvulsivante (ahn-tee-kohn-bool-SEE-ban-teh)
antidiarrheal	antidiarrético (ahn-tee-dee-ah-RREH-tee-koh)
antiemetic	antiemético (ahn-tee-eh-MEH-tee-koh)
antiepileptic	antiepiléptico (ahn-tee-eh-pee-LEHP-tee-koh)
antihistamine	antihistamínico (ahn-tee-ees-tah-MEE-nee-koh)
antiviral	antivirus (ahn-tee-BEE-roos)
anus	ano (AH-no)
appendix	apéndice (ah-PEHN-dee-seh)
arm	brazo (BRAH-soh)
armpit	axila (ahk-SEE-lah)
arteriogram	arteriograma (ahr-teh-ree-oh-GRAH-mah)
arthritis	artritis (ahr-TREE-tees)
asthma	asma (AHS-mah)
bacteria	bacteria (bahk-TEH-ree-ah)
barbiturates	barbitúricos (bah-ree-TOO-ree-kohs)
birthmark	lunar (loo-NAHR)
bleeding	sangrado (sahn-GRAH-doh)
blood	sangre (SAHN-greh)
blood count	biometría hemática (bee-oh-meh-TREE-ah eh-MAH-tee-kah)
bradycardia	bradicardia (brah-dee-KAHR-dee-ah)
brain	cerebro (seh-REH-bro)
breast/chest	seno (SEH-noh), pecho (PEH-choh)
bronchial tube	bronquio (BROHN-kee-oh)
bronchitis	bronquitis (brohn-KEE-tees)
bruises	moretones (moh-reh-TOH-nehs)
burn	quemadura (keh-mah-DOO-rah)
buttocks	nalgas (NAHL-gahs)
calf	pantorrilla (pahn-toh-RREE-yah)
callus	callo (KAH-yoh)
calm	calma (KAHL-mah)
cardiac	cardíaco (kahr-DEE-ah-koh)
cataract	catarata (kah-tah-RAH-tah)
cervix	cuello uterino (KOO-eh-yoh) (oo-teh-REE-noh), cerviz (SERH-bees)
chancere	chancro (CHAHN-kroh)
cheek	mejilla (meh-HEE-yah)
chemotherapy	quimioterapia (kee-mee-oh-teh-RAH-pee-ah)
chin	barbilla (bar-BEE-yah)
cholesterol	colesterol (koh-lehs-teh-ROHL)
cirrhosis	cirrosis (see-RROH-sees)
claustrophobia	claustrofobia (klah-oos-troh-FOH-bee-ah)
coagulation	coagulación (koh-ah-goo-lah-see-OHN)
collar bone	clavicula (klah-VEE-kuh-la)
colon	colon (KOH-lohn)
constipation	estreñimiento (ehs-treh-nyee-mee-EHN-toh)
cortisone	cortisona (kahr-tee-SOH-nah)
cough	tos (tohs)
cyanotic	cianótico (see-ah-NOH-tee-ko)

decongestants	descongestionantes (dehs-kohn-hehs-tee-oh-NAHN-tehs)
dehydrated	deshidratado (deh-see-drah-TAH-doh)
delirious	delirio (deh-LEE-ree-oh)
depressed	deprimido (deh-pree-MEE-doh)
diabetes	diabetes (dee-ah-BEH-tehs)
diarrhea	diarrea (dee-ah-RREH-ah)
digitalis	digital (dee-hee-TAHL)
ear (inner)	oído (oh-EE-do)
ear (outer)	oreja (oh-REH-hah)
ecchymosis	equimosis (eh-kee-MOH-sees)
eczema	eccema (ehk-SEH-mah)
elbow	codo (KOH-doh)
embolism	embolia (ehm-boh-LEE-ah)
emetic	emético (eh-MEH-tee-koh)
enteritis	enteritis (ehn-teh-REE-tees)
epilepsy	epilepsia (eh-pee-LEHP-see-ah)
euphoric	eufórico (eh-oo-FOH-ree-koh)
exudate	exudado (ehk-soo-DAH-doh)
eye	ojo (OH-hoh)
eyebrow	ceja (SEH-hah)
eyelash	pestaña (pehs-TAH-nyah)
eyelids	párpados (PAHR-pah-dohs)
fibroid	-fibroma (fee-BROH-mah)
finger	dedo (DEH-doh)
fungernail	uña (OO-nyah)
fist	puño (POO-nyoh)
fistula	fístula (FEES-too-lah)
foot	pie (pee-EH)
forearm	antebrazo (an-teh-BRAH-zoh)
forehead	frente (FREN-teh)
fungus	hongo (OHN-goh)
gallbladder	vesícula biliar (beh-SEE-koo-lah bee-lee-AHR)
gangrene	gangrena (gahn-GREH-nah)
gastroenteritis	gastroenteritis (gahs-troh-ehn-teh-REE-tees)
gastroenterology	gastroenterología (gahs-troh-ehn-teh-roh-loh-HEE-ah)
genital organs	órganos genitales (ORH-gah-nohs heh-nee-TAH-lehs)
glaucoma	glaucoma (glah-oo-KOH-mah)
groin	ingle (EEN-gleh)
gums	encías (ehn-SEE-ahs)
gynecologist	ginecólogo (hee-neh-KOH-loh-goh)
hair	cabello (kah-BEH-yoh)
hand	mano (MAH-noh)
head	cabeza (kah-BEH-sah)
heart	corazón (koh-rah-SOHN)
heel	talón (tah-LOHN)
hematology	hematología (eh-mah-toh-loh-HEE-ah)
hematoma	hematoma (eh-mah-TOH-mah)
hemolysis	hemólisis (eh-MOH-lee-sees)
hemorrhage	hemorragia (eh-moh-RRAH-hee-ah)
hepatitis	hepatitis (eh-pah-TEE-tees)
hernia	hernia (EHR-nee-ah)
hip	cadere (kah-DEH-rah)
hypertension	hipertensión (ee-pehr-tehn-see-OHN)
icteric	ictérico (eek-TEH-ree-koh)
infection	infección (een-fehk-see-OHN)
inflammation	inflamación (een-flah-mah-see-OHN)
insulin	insulina (een-soo-LEE-nah)
intestine	intestino (een-tes-TEE-noh)
intramuscular	intramuscular (een-trah-moos-koo-LAHR)
intravenous	intravenoso (een-trah-beh-NOH-soh)
irradiate	irradiar (ee-rrhah-dee-AHR)
jaw	mandíbula (mahn-DEE-boo-lah)
kidney	riñón (ree-NYON)
knee	rodilla (ro-DEE-yah)
laparoscopy	laparoscopia (lah-pah-rohs-KOH-pee-ah)
laryngitis	laringitis (lah-reen-HEE-tees)
laxative	laxante (lahk-SAHN-teh)
left	izquierdo (ees-kee-EHR-doh)
leg	pierna (pee-EHR-nah)
ligament	ligamento (lee-gah-MEHN-toh)
lingual	lingual (leen-GUAHL)
lip	labio (LAH-bee-oh)

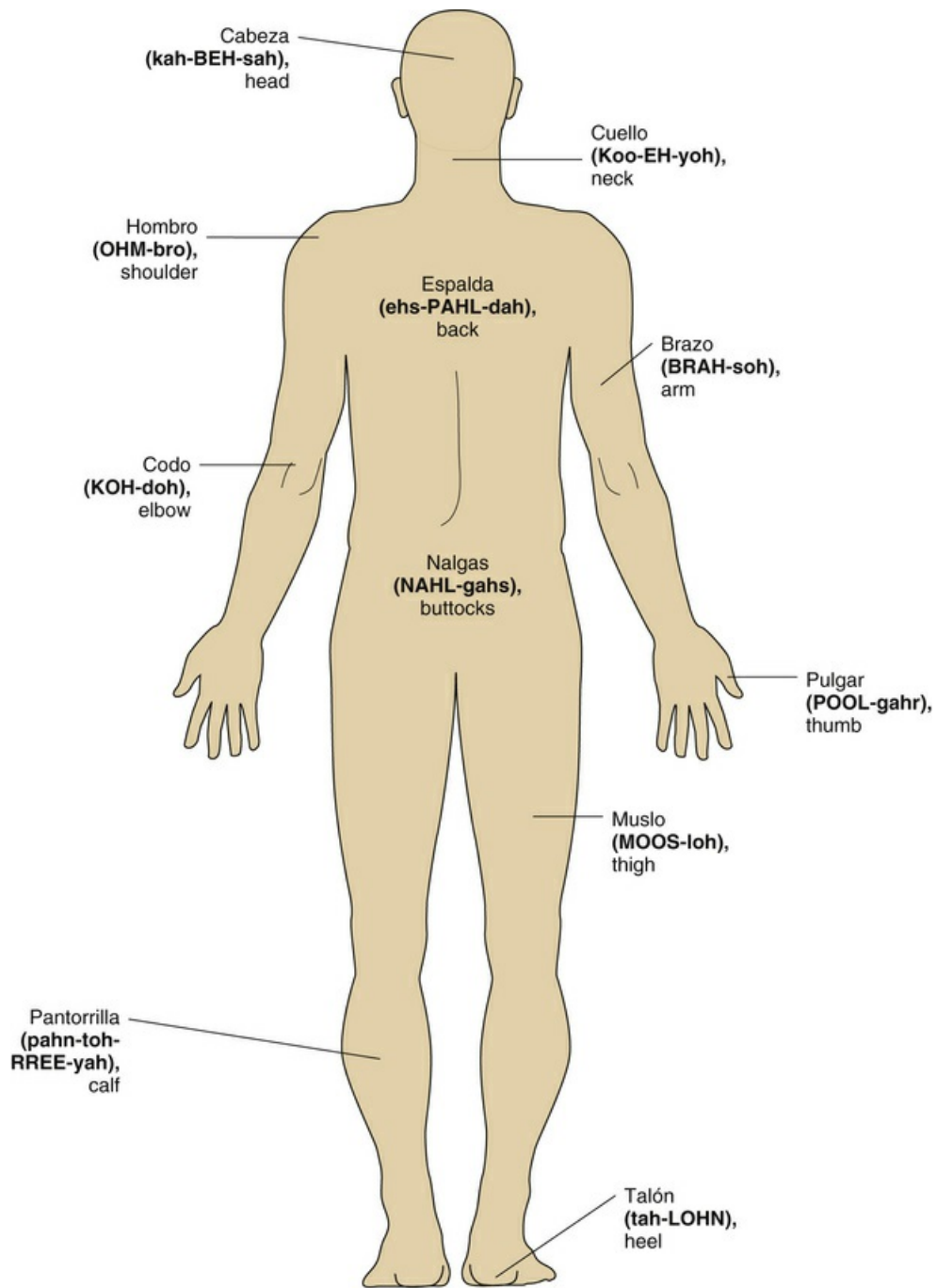
lithium	litio (LEE-tee-oh)
liver	hígado (EE-gah-doh)
low cholesterol	bajo colesterol (bah-hoh koh-lehs-teh-ROHL)
low fat	bajo grasa (bah-hoh GRAH-sah)
low sodium	bajo sodio (bah-hoh soh-dee-oh)
lung	pulmón (pool-MOHN)
meningitis	meningitis (meh-neen-HEE-tees)
morphine	morfina (mohr-FEE-nah)
mouth	boca (BOH-kah)
muscle	músculo (MOOS-koo-loh)
narcotics	narcóticos (nahr-KOH-tee-kohs)
nasal	nasal (nah-SAHL)
nausea	náusea (NAH-oo-seh-ah)
navel	ombligo (ohm-BLEE-goh)
neck	cuello (koo-EH-yoh)
neonatal	neonatal (neh-oh-nah-TAHL)
nephrologist	nefrólogo (neh-PHROH-lo-goh)
nephrology	nefrología (neh-phroh-lo-HEE-ah)
nervous	nervioso (nehr-bee-OH-soh)
neurotic	neurótico (neh-oo-ROH-tee-koh)
nipple	pezón (peh-SOHN)
nitroglycerin	nitroglicerina (nee-troh-glee-seh-REE-nah)
nose	nariz (nah-REES)
nostrils	fosas nasales (foh-SAHS na-SAH-lehs)
Novocain	novocaina (noh-boh-kah-EE-nah)
nuclear medicine	medicina nuclear (meh-dee-SEE-nah NOO-kleh-ahr)
obstetrics	obstetricia (ohbs-teh-TREE-see-ah)
oncology	oncología (ohn-koh-loh-HEE-ah)
ophthalmic	oftálmico (ohf-TAHL-mee-koh)
ophthalmology	oftalmología (ohf-tahl-moh-loh-HEE-ah)
optic	óptico (OHP-tee-koh)
orthopedics	ortopedia (ohr-toh-PEH-dee-ah)
orthopedic surgeon	cirujano ortopédico (see-roo-HAH-noh ohr-toh-PEH-dee-koh)
otic	ótico (OH-tee-koh)
ovary	ovario (oh-BAH-ree-oh)
palate	paladar (pah-lah-DAHR)
palpation	palpación (pahl-pah-see-OHN)
palpitation	palpitación (pahl-pee-tah-see-OHN)
pancreas	páncreas (PAHN-kreh-ahs)
pancreatitis	pancreatitis (pahn-kreh-ah-TEE-tees)
paralytic	paralítico (pah-rah-LEE-tee-koh)
pathogen	patógeno (pah-TOH-hen-oh)
pathologic	patológico (pah-toh-LOH-hee-koh)
pathology	patología (pah-toh-loh-HEE-ah)
pediatrics	pediatría (peh-dee-ah-TREE-ah)
pelvis	pelvis (PEHL-bees)
penis	pene (PEH-neh), miembro viril (mee-EHM-broh vee-REEL)
pneumonia	pulmonía/neumonía (pool-moh-NEE-ah/neh-oo-moh-NEE-ah)
pruritic	prurito (proo-REE-toh)
psoriasis	psoriasis (soh-ree-AH-sees)
psychiatrist	psiquiatra (see-kee-AH-trah)
psychiatry	psiquiatría (see-kee-ah- TREE-ah)
psychologist	psicólogo (see-KOH-loh-goh)
pubic	púbico (POO-bee-koh)
pyorrhea	piorrea (pee-oh-RREH-ah)
radiologist	radiólogo (rah-dee-OH-loh-goh)
radiology	radiología (rah-dee-oh-loh-HEE-ah)
rectum	recto (REHK-toh)
rheumatic	reumático (reh-oo-MAH-tee-koh)
rib	costilla (kohs-TEE-yah)
right	derecho (deh-REH-choh)
roseola	roseola (roh-seh-OH-lah)
rubella	rubéola (roo-BEH-oh-lah)
scalp	cuero cabelludo (KOO-eh-roh kah-beh-YOO-doh)
sebaceous	sebáceo (seh-BAH-seh-oh)
sedatives	sedativos/sedantes (seh-dah-TEE-bohs/seh-DAHN-tehs)
shin	espinilla (ehs-pee-NEE-yah), canilla (kah-NEE-yah)
shoulder	hombro (OHM-bro)
skin	piel (pee-EHL)
skull	cráneo (KRAH-ne-oh)
spinal column	columna vertebral (koh-LUHM-nah behr-teh-BRAHL)
spleen	bazo (BAH-soh)

stethoscope	estetoscopio (ehs-teh-tohs-KOH-pee-oh)
stomach	estómago (ehs-TOH-mah-goh)
stool sample	muestra – fecal (moo-EHS-trah -feh-KAHL)
straight	derecho (deh-REH-choh)
subaxillary	subaxilar (soob-AHK-see-lahr)
subcutaneous	subcutáneo (soob-koo-TAH-neh-oh)
sublingual	sublingual (soob-LEEN-goo-ahl)
substernal	subesternal (soob-ehs-TEHR-nahl)
surgeon	cirujano (see-roo-HAH-noh)
surgery	cirugía (see-roo-HEE-ah)
symptoms	síntomas (SEEN-toh-mahs)
syncope	síncope (SEEN-koh-peh)
systole	sístole (SEES-toh-leh)
teeth	dientes (dee-EHN-tehs)
temple	sien (see-EHN)
testicles	testículos (tehs-TEE-koo-lohs)
tetanus	tétano (TEH-tah-noh)
therapy	terapia (teh-RAH-pee-ah)
thigh	muslo (MOOS-loh)
throat	garganta (gahr-GAHN-tah)
thumb	pulgar (POOL-gahr)
thyroid	tiroide (tee-ROY-deh)
toes	dedos (DEH-dos), del pié (dehl PEE-eh)
tongue	lengua (LEHN-goo-ah)
tonsillitis	tonsilitis/amigdalitis (tohn-see-LEE-tees/ah-meeg-dah-LEE-tees)
tonsils	amígdalas (ah-MEEG-da-las)
ulcer	úlceras (OOL-seh-rah)
ulnar	ulnar (OOL-nahr)
ultrasound	ultrasonido (ool-trah-soh-NEE-doh)
uremia	uremia (oo-REH-mee-ah)
urinary bladder	vejiga (beh-HEE-gah)
urine	orina (oh-REE-nah)
urticaria	urticaria (oor-tee-KAH-ree-ah)
uterus	útero (OO-teh-roh)
uvula	úvula (OO-boo-lah)
vaginitis	vaginitis (bah-hee-NEE-tees)
vagus	vago (BAH-goh)
valve	válvula (BAHL-boo-lah)
varicocele	varicocele (bah-ree-koh-SEH-leh)
vertigo	vértigo (BEHR-tee-goh)
waist	cintura (sin-TOO-rah)
womb	vientre (bee-EHN-treh)
wrist	muñeca (moo-NYEH-kah)
x-rays	rayos equis (rah-YOHS EH-kees)
zygomatic	cigomático (see-goh-MAH-tee-koh)



Anterior View

The body/EI cuerpo (ehl KWEHR-poh).



Posterior View

The body/El cuerpo (ehl KWEHR-poh).

Diagrams of the body labeled with Spanish terms are on pages 410 and 411.

Index

Page numbers followed by “*f*” indicate figures, “*t*” indicate tables, and “*s*” indicates spotlights.

A

- abbreviations, comprehensive list of, [318–328](#)
 - cardiovascular system, [216](#)
 - digestive system, [224](#)
 - ears/hearing, [279](#)
 - endocrine system, [232](#)
 - eyes/vision, [278](#)
 - female reproductive system, [238](#)
 - male reproductive system, [248](#)
 - musculoskeletal system, [253](#)
 - urinary system, [285](#)
- abdomen, [59](#)
 - CT scan of, [226](#)
 - laparotomy and, [12](#), [12f](#), [46](#)
 - MRI of, [226](#)
 - ultrasonography for, [226](#)
- abdominal cavity, [51](#), [53](#)
- abdominal pain, [189](#)
- abdominocentesis (paracentesis), [310](#)
- ABG (arterial blood gas), [272](#)
- Achilles tendon, [255f](#), [331](#)
- acid phosphate tests, [296](#)
- acid reflux, [189](#)
- ACL (anterior cruciate ligament), [258](#)
- acquired immunodeficiency syndrome (AIDS), [147t](#), [174](#), [245–246](#)
- acromegaly, [233](#)
- acronyms, comprehensive list of, [329–330](#)
- ACS (acute coronary syndrome), [219](#)
- ACTH (adrenocorticotrophic hormone), [136t](#), [234](#)
- acute conditions, [95](#)
- acute coronary syndrome (ACS), [219](#)
- acute myocardial infarction (AMI), [219](#)
- acute myocardial ischemia, [184](#)

acute renal failure (ARF), 287

acute respiratory distress syndrome (ARDS), 272

AD (Alzheimer disease), 264–265, 331

adductor magnus, 254f–255f

adenectomy, 99t

adenitis, 5

adenocarcinoma, 46, 91, 91f

adenoidectomy, 99t

adenoids, 97f, 269f

- excision of, 99t

adenoma, 5, 91

adenopathy, 93t

adjective suffixes, 94–95

adrenal glands, 7f, 46, 232f, 285f

- diseases of, 93t
- hormones of, 136t
- location of, 133f

adrenaline (epinephrine), 136t

adrenocorticotrophic hormone (ACTH), 136t, 234

adrenopathy, 93t

AED (automated external defibrillator), 219

AFP (alpha-fetoprotein) tests, 297

AIDS (acquired immunodeficiency syndrome), 147t, 174, 245–246

air sacs (alveoli), 269f

alanine transaminase (ALT), 227, 296

albumin tests, 296

albuminuria, 286

alkaline phosphatase tests, 227, 296

allergists, 177t

allergy tests, 281, 296

allied health careers, 340–348

alopecia, 280

alpha-fetoprotein (AFP) tests, 296

ALT (alanine transaminase), 227, 296

alveoli (air sacs), 269f

Alzheimer disease (AD), 264–265, 331

ambulatory electrocardiography, Holter monitoring

amenorrhea, 132, 239

AMI (acute myocardial infarction), 219

amniocentesis, 97f, 240, 296

amnion sac, 240

ANA (antinuclear antibody) tests, 257–258, 296

analysis of urine, 133

anastomoses, 103, 104*f*, 128, 227

anemias, 18, 46, 132, 132*t*, 186, 189

anesthesiologists, 177*t*

anesthesiology, 176

aneurysm, 217

angina, 184, 217

angiography, 100, 218

- cerebral, 265, 297
- coronary, 184, 184*f*, 297
- digital subtraction, 303
- fluorescein, 281, 305
- magnetic resonance, 308
- pulmonary, 271, 311

angioplasty, 102, 102*f*, 219

ankylosing spondylitis, 257

anterior, definition of, 56–57, 59, 60*t*

anterior cruciate ligament (ACL), 258

antiarrhythmic drugs, 184

antibiotics, 134, 174

antibody, 62, 133, 174, 183*s*

anticoagulant drugs, 184

antigens, 133, 174

antihypertensive medications, 193

antinuclear antibody (ANA) tests, 257–258, 297

anuria, 286

anus, 52*f*, 182*f*, 224*f*

aorta, 84, 95*f*, 148*f*, 190, 216*f*

apex/apices, 10*t*

Apgar score, 331

aphasia, 132

aplastic anemia, 132*t*

apnea, 132

appendectomy, 99*t*, 227

appendicitis, 90*t*

appendix, 224*f*

- excision of, 99*t*

ARDS (acute respiratory distress syndrome), 272

areola, 238*f*

ARF (acute renal failure), 287

armpit (axillary) lymph nodes, 180, 244f

arrhythmias, 217–218

- ventricular, 184

arterial blood gas (ABG), 272

arteries, 216f

arteriography, 297

arterioles, 216f

arteriosclerosis, 94, 95f

arteriovenous fistula, 193, 193f

arthralgia, 15

arthritis, 5

- ankylosing spondylitis, 257
- gouty, 257
- osteoarthritis, 13, 13f, 183s
- rheumatoid, 183s, 183f, 257

arthrocentesis, 96, 257, 297

arthrography/arthrogram, 15, 257, 297

arthroplasty, 258

arthroscopy, 17, 136t, 257

- of knee, 18f

ascites, 52s, 62, 63f

aspartate transaminase (AST) tests, 227, 297

Asperger syndrome, 331

asphyxia, 271

aspiration, 240, 297

AST (aspartate transaminase) tests, 227, 297

asthma, 271

atelectasis, 271

atheroma, 94

atherosclerosis, 94, 95f, 217

atrophy, 132, 138, 139f, 183f

- of bone, 183f

audiologists, 340

audiometry, 297

auditory canal, 279

auditory nerve, 279

auras, with migraines, 194

auscultation, 297

autoimmune diseases

- antibodies and, 183s
- Sjögren syndrome, 334

automated external defibrillator (AED), 219
autopsies, 18
axial (transverse) plane, 57, 57f, 84
 MRIs of, 58f
axilla (underarm), 238f
axillary (armpit) lymph nodes, 180, 244f

B

back, structures of, 54, 54f–55f
backbone, 54
bacteremia, 88s
bacteria, 10t
bacterial tests, 281, 297
baldness, 280
balloon angioplasty, 102, 102f, 219
barium, 189
barium enema (BE), 226–227, 297, 308
barium swallow, 226, 297
barium tests, 226, 298
Barlow syndrome, 331
Barrett esophagus, 331
basophil, 9f
BE (barium enema), 226–227, 298, 308
Bell palsy, 331
Bence Jones protein tests, 298
benign prostatic hyperplasia (BPH), 138, 147, 249
benign tumors, 91, 92f, 128, 140s, cancer/malignant tumors
biceps brachii, 254f–255f
biceps femoris, 255f
bilateral oophorectomy, 128
bile emulsification, 106
bilirubin, 226–227
bilirubin tests, 298
biology, 5
biopsies, 5, 16, 240
 bone marrow, 298
 muscle, 257, 309
 skin, 281, 312
 stereotactic breast, 308
 types of, 298
bladder, urinary, 7, 52f, 133f, 182f, 248f, 285f

- blood, 11
 - circulation of, 216*f*
 - infections of, 88
 - travel, 148*f*
 - urea in, 94*s*
 - in urine, 94*s*
 - withdrawing, 105*f*
- blood bank technologists, 340
- blood cells, 9, 9*f*
- blood chemistry profile, 298
- blood cultures, 298
- blood differential tests, 298
- blood pressure (BP), 219
- blood sugar, 19*s*, 21–22
- blood urea nitrogen (BUN), 286–287, 298
- blood vessels, 277
 - dilation of, 194
- body cavities, 50*f*–52*f*, 51–53
- body planes, 56–64, 56*f*
- body systems
 - definition of, 48
 - groups of cells, tissues, organs, and, 48*f*
 - overview of, 48–49
- bolus, food, 63*f*
- bone density tests, 257, 299
- bone marrow
 - biopsies, 299
 - malignant tumor of, 92*t*
 - multiple myeloma, 91, 92*t*
- bone scans, 257, 299
- bones, musculoskeletal system
 - cancer of, 92*t*
 - carpal, 140, 141*f*, 253*f*
 - diseases of, 93*t*
 - finger, 141*f*, 253*f*
 - fractures of, 192, 192*f*, 331
 - metacarpal, 140, 141*f*, 253*f*
 - of middle ear, 279
 - Paget disease and, 333
 - of spinal column, 54, 84
- BP (blood pressure), 219

BPH (benign prostatic hyperplasia), 138, 147, 249
brachialis, 254f–255f
brachioradialis, 255f
brain, 6, 9
 Alzheimer disease and, 264–265, 331
 anatomy of, 263f
 concussion and, 264
 epilepsy and, 264
 glioblastoma and, 264
 Reye syndrome and, 333
 surrounding anatomy and structures of, 90f
 syncope and, 264
brain scans, 299
breast bone, 50f
breast cancer, 100f, 140f, 174
breasts
 anatomy of, 238f
 aspiration of, 240
 mammography of, 100, 100f, 240, 308
 stereotactic biopsies of, 308
bronchial tubes, 51f, 84, 269f
bronchioles, 269f
bronchitis, 89, 271
bronchoscopy, 59, 136t, 271, 299
bronchus, 10t
buccinator, 255f
BUN (blood urea nitrogen), 286–287, 299
Burkitt lymphoma, 331
bursa(e), 10t
bursitis, 90t

C

CA-125 tests, 299
CABG (coronary artery bypass grafting), 218–219
CAD (coronary artery disease), 219
calcium (Ca), 258
calcium levels, 257
calcium tests, 299
calculus/calculi, 10t
 renal, 188, 188f
callus formation, 192, 192f

cancer/malignant tumors

- adenocarcinoma, 46, 91, 91*f*
- adenoma, 5, 91
- benign tumors compared to, 140*s*
- of bones, 92*t*
- breast, 100*f*, 140*f*, 174
- Burkitt lymphoma, 331
- carcinoma, 5, 15, 46, 91, 100*f*, 190, 226
- chemotherapy for, 187, 246
- chondroma, 60
- chondrosarcoma, 60, 92*t*
- diagnosis of lung cancer, case study, 77
- Ewing sarcoma, 332
- fibrosarcoma, 92*t*
- glioblastoma, 264
- hepatoma, 92*t*
- Hodgkin lymphoma, 187, 245–246
- Kaposi sarcoma, 333
- leiomyomas, 92*f*
- leiomyosarcoma, 92*t*
- leukemia, 15, 38, 46, 88, 93*s*
- liposarcoma, 92*t*
- lung, 190
- lymphoma, 92*t*, 245
- melanoma, 92*t*, 281
- mesothelioma, 92*t*
- metastasis of, 140, 140*f*, 174
- multiple myeloma, 91, 92*t*, 246
- myosarcoma, 91, 128
- names without carcin/o and sarc/o, 92*t*
- non-Hodgkin lymphoma, 246
- osteogenic sarcoma, 92*t*
- osteosarcomas, 46
- primary, 174
- prostatic carcinoma, 249
- radiotherapy for, 103*s*, 182, 182*f*, 187, 246
- rhabdomyosarcoma, 92*t*
- sarcoma, 14, 46, 64*s*, 92*t*
- seminoma, 249
- testicular carcinoma, 249
- thymoma, 92*t*

- Wilms tumor, [334](#)
- CAPD (continuous ambulatory peritoneal dialysis), [287](#)
- carbon dioxide (CO₂), [272](#)
- carbon dioxide tests, [299](#)
- carcinoembryonic antigen (CEA) tests, [300](#)
- carcinomas, [5](#), [46](#), [91](#), [100f](#), [190](#)
 - hepatocellular, [15](#), [226](#)
 - prostatic, [249](#)
 - testicular, [249](#)
- cardiac care unit (CCU), [184](#), [219](#)
- cardiac catheter ablation, [218–219](#)
- cardiac catheterization, [218](#), [300](#)
- cardiac enzyme tests, [218](#), [300](#)
- cardiologists, [177t](#), [214](#)
- cardiology, [5](#), [16t](#)
 - case report for, [184s–185s](#)
- cardiomyopathy, [93s](#)
- cardiopulmonary resuscitation (CPR), [219](#), [272](#)
- cardiovascular surgeons, [177t](#), [214](#)
- cardiovascular system
 - abbreviations for, [219](#)
 - anatomy of, [216](#), [216f](#)
 - diagnostic procedures and laboratory tests for, [218](#)
 - pathology of, [217](#)
 - terminology of, [217](#)
 - treatment procedures for, [218–219](#)
- cardiovascular technicians, [342](#)
- cardioversion, [218](#)
- carpal bones, [140](#), [141f](#), [253f](#)
- carpal tunnel syndrome, [147t](#), [174](#), [257](#)
- cartilage, [54](#), [60](#)
 - cancer of, [92t](#)
 - tracheal and laryngeal, [64f](#)
- cataracts, [280](#)
- catheterization, [218](#), [300](#)
- catheters
 - Foley, [300](#), [332](#)
 - intra-abdominal, [287](#)
- cauda equina, [263f](#)
- cauterization, [240](#)

cavities, [body cavities](#)

CBC (complete blood count), [301](#)

CCU (cardiac care unit), [184](#), [219](#)

CEA (carcinoembryonic antigen) tests, [300](#)

cells, [48](#), [48f](#)

cellulitis, [90t](#)

central nervous system (CNS), [263f](#), [265](#)

cephalgia, unilateral frontal, [194](#)

cephalic, definition of, [6](#)

cerebellum, [263f](#)

cerebral, definition of, [6](#)

cerebral angiography, [265](#), [297](#)

cerebrospinal fluid (CSF) analysis, [265](#), [300](#)

cerebrovascular accident (CVA), [6](#), [6s](#), [95](#), [128](#), [264](#)

cerebrum, [6f](#), [263f](#)

cervical, definition of, [60](#)

cervical (neck) lymph nodes, [180](#), [244f](#)

cervical nerves, [263f](#)

cervical spine, [54](#), [84](#)

cervical vertebra, [253f](#), [258](#)

cervix, [60](#), [61f](#), [238f](#)

- cauterization of, [240](#)
- conization of, [240](#)

Cesarean section (CS), [241](#)

chemotherapy, [187](#), [246](#)

chest x-rays, [57](#), [57f](#), [190](#), [190f](#), [271](#), [300](#)

Cheyne-Stokes respiration, [331](#)

CHF (congestive heart failure), [217](#), [219](#)

chiropractors, [340](#)

chlamydial infection, [249](#)

cholangiography, [226](#), [300](#), [endoscopic retrograde cholangiography](#)

cholecystectomy, laparoscopic, [98](#), [99f](#), [106](#), [128](#), [227](#)

cholelithiasis, [226](#)

cholesterol tests, [300](#)

chondroma, [60](#)

chondrosarcoma, [60](#), [92t](#)

chorionic villus sampling, [301](#)

chronic bronchitis, [271](#)

chronic conditions, [95](#)

chronic kidney disease (CKD), [287](#)

chronic obstructive pulmonary disease (COPD), [271–272](#)

chronic renal failure, 193
circulatory system, 48, 216f
cirrhosis, 226
CK (creatine kinase) tests, 302
CKD (chronic kidney disease), 287
clavicle (collarbone), 146f, 253f
clinical laboratory technologists (CLTs), 340
clinical skills, 176
CLTs (clinical laboratory technologists), 340
CNS (central nervous system), 263f, 265
CO₂ (carbon dioxide), 272
coccygeal, definition of, 60
coccygeal nerves, 263f
coccygeal spine, 54, 84
cochlea, 279
colectomy, 99t
colitis, ulcerative, 179s, 226
collarbone (clavicle), 146f, 253f
Colles fracture, 331
colocolostomy, 103
colon, 8f, 224f
 excision of, 99t
 polyposis of, 226
 stomas of, 104f
colonography, CT, 227
colonoscopy, 136t, 226, 301
 polyps removed in, 143
 virtual, 227
colorectal surgeons, 177t
colostomy, 103, 104f, 227
colposcopy, 240, 301
combining forms, 3–4
 definition of, 3
 exceptions and unusual forms of, 11s
 list of common, 5–14
 for medical specialists, 179–184
 for planes of body, 59–64
 prefixes and, 130–131
 suffixes and, 86–87
combining vowels, 2–3

common bile duct, [99f](#), [106](#)
competency examinations, [176](#)
complete blood count (CBC), [301](#)
computed tomography (CT), [57f](#), [190f](#)
 abdominal, [226](#)
 colonography, [227](#)
 definition of, [301](#)
 description of procedure, [65](#)
 for endocrine system, [234](#)
 for lymphatic system, [245](#)
 of nervous system, [265](#)
 for respiratory system, [271](#)
concussion, [264](#)
congenital, definition of, [134](#)
congestive heart failure (CHF), [217](#), [219](#)
conization, [240](#), [301](#)
conjunctiva, [278](#), [280](#)
conjunctivitis, [280](#)
continuous ambulatory peritoneal dialysis (CAPD), [287](#)
continuous positive airway pressure (CPAP), [272](#)
COPD (chronic obstructive pulmonary disease), [271–272](#)
core biopsies, [298](#)
cornea, [278](#)
coronal (frontal) plane, [56–57](#), [57f](#), [84](#)
 MRIs of, [58f](#)
coronary angiography, [184](#), [184f](#), [297](#)
coronary arteriography, [297](#)
coronary artery bypass grafting (CABG), [218–219](#)
coronary artery disease (CAD), [219](#)
coronary artery spasm, [184](#), [184f](#)
coroners, [14s](#)
cortex/cortices, [10f](#)
cortisol, [233](#)
CPAP (continuous positive airway pressure), [272](#)
CPR (cardiopulmonary resuscitation), [219](#), [272](#)
cranial cavity, [51](#), [53](#)
cranium, [253f](#)
creatinine kinase (CK) tests, [301](#)
creatinine clearance tests, [302](#)
creatinine tests, [287](#), [302](#)
Crohn disease, [179s](#), [195–196](#), [226](#), [331](#)

cross sections, 57
cryosurgery, 240
cryotherapy, 103
cryptorchism, 249
CS (Cesarean section), 241
CSF (cerebrospinal fluid) analysis, 265, 300
CSTs (surgical technologists), 348
CT, [computed tomography](#)
culdocentesis, 302
culture, 302
Cushing syndrome, 233, 332
cuticle, 277
CVA (cerebrovascular accident), 264
CyberKnife, 265
cystography, 302, 315
cystoscope, 7, 7f
cystoscopy, 7, 136t, 286, 302
cytology, 8

D

D&C (dilation and curettage), 240–241, 303
deep, definition of, 60t
defibrillation, 218
degenerative disorders
 Huntington disease, 332
 of joints, 13, 13f
 Parkinson disease, 333
 Tay-Sachs disease, 334
degenerative joint disease (DJD), 258
delayed-onset muscle soreness (DOMS), 258
deltoid, 254f–255f
delusions, 14
dementia, irreversible, 264
dental assistants, 341
dental hygienists, 341
dental laboratory technicians, 341
dental specialists, 181s
dermal, 8
dermatitis, 8, 90t
dermatologists, 177t
dermatology, 16t, 176

dermis, 277

DEXA (dual-energy x-ray absorptiometry), 257–258, 299

diabetes mellitus (DM), 138, 234

- definition of, 233
- glucose test for, 234
- living with, 21–22
- type 1, 19s, 21–22, 191, 233
- type 2, 19s, 233

diagnosis

- definition of, 10, 10t, 19, 46
- of leukemia case study, 38
- of lung cancer case study, 77

diagnostic medical sonographers, 341

diagnostic suffixes, 87–95

dialysis, 101, 101f, 128, 287

diameter, 19

diaphragm, 8f, 50f, 51, 53, 269f

diarrhea, 134

dietitians, 342

digestive system

- abbreviations for, 227
- anatomy of, 224, 224f
- definition and role of, 49
- diagnostic procedures and laboratory tests for, 226–227
- pathology of, 226
- terminology of, 225
- treatment procedures for, 227

digital rectal examination (DRE), 249, 302

digital subtraction angiography, 302

dilation, of blood vessels, 194

dilation and curettage (D&C), 240–241, 302

dissectomy, microscopic, 258

disease conditions (-pathies), 93t

disks (discs), 54, 54f

distal, definition of, 60t

diuretics, 143s, 184

diverticula, 226

diverticulitis, 226

diverticulosis, 226

DJD (degenerative joint disease), 258

DM, diabetes mellitus

DOMS (delayed-onset muscle soreness), 258
Doppler ultrasound, 218, 303
double membranes, 52s
Down syndrome, 147t
DRE (digital rectal examination), 249, 303
drug-eluting stents, 102f
drugs, reference guide for top 50 prescribed, 336t–337t
dual-energy x-ray absorptiometry (DEXA), 257–258, 299
DUB (dysfunctional uterine bleeding), 241
Duchenne muscular dystrophy, 332
duodenum, 8f, 224f
dura mater, 137f
dysentery, 19
dysfunctional uterine bleeding (DUB), 241
dysmenorrhea, 186, 239
dyspepsia, 189
dysuria, 135, 188, 286

E

eardrum, 279
ears, nose, throat (ENT), 281
ears/hearing
 anatomy of, 279
 audiologists for, 340
 Ménière disease and, 333
 Rinne tests for, 333
 tinnitus of, 281
 tuning fork tests and, 281, 314, 333–334
ECG, electrocardiogram
ECG technicians, 342
echocardiography, 218–219, 303
ectopic pregnancy, 135f, 239
EEG, electroencephalogram
EGD (esophagogastroduodenoscopy), 305
ejaculation, 7
electrocardiogram (ECG), 8, 184, 218–219, 303
electroencephalogram (EEG), 9, 265, 303
electrolyte panel, 303
electrolytes, 234
electromyography (EMG), 257–258, 303
electrophoresis (serum protein electrophoresis), 312

ELISA (enzyme-linked immunosorbent assay), 245–246, 304

embryos, 238*f*

emergency medical technicians (EMTs), 342

emergency medicine, 176

emergency practitioners, 177*t*

EMG (electromyography), 257–258, 303

emphysema, 271

EMTs (emergency medical technicians), 342

endarterectomy, 219

endocarditis, 90*t*

endocardium, 19

endocrine glands, 19, 46

- major types of, 136*t*

endocrine system

- abbreviations for, 234
- anatomy of, 232, 232*f*
- definition and role of, 49
- diagnostic procedures and laboratory tests for, 234
- pathology of, 233–234
- terminology of, 233

endocrinologists, 177*t*

endocrinology, 16*t*

- case report for, 191*s*

endodontists, 181*s*

endometriosis, 239

endometrium, 239

endoscopic retrograde cholangiography (ERCP), 226–227, 304

endoscopic ultrasonography (E-US), 226, 304

endoscopy, 304

- gastrointestinal, 226
- types of, 136*t*

endotracheal intubation, 272

endotracheal tubes, 142*f*

ENT (ears, nose, throat), 281

enteritis, 9

enzyme-linked immunosorbent assay (ELISA), 245–246, 304

eosinophil, 9

epidermis, 137, 277

epidural hematomas, 137*f*

epiglottis, 63*s*, 63*f*, 269*f*

epiglottitis, 90*t*

epilepsy, 264

epinephrine (adrenaline), 136*t*

epithelial, definition of, 61

eponyms, comprehensive list of, 331–334

Epstein-Barr virus, 332

ERCP (endoscopic retrograde cholangiography), 226–227, 304

erythrocyte sedimentation rate (ESR), 257–258, 304

erythrocytes (red blood cells), 9, 9*f*, 46

erythrocytosis, 93

erythromycin, 134

esophagogastroduodenoscopy (EGD), 304

esophagogastrosocopy, 136*t*

esophagography, 304

esophagoscopy, 226, 304

esophagus, 8*f*, 51*f*, 63*f*, 143*f*, 224*f*

- abnormal changes in lining of, 331
- adenocarcinoma of, 91*f*
- definition of, 84

ESR (erythrocyte sedimentation rate), 257–258, 304

estradiol assays, 304

estrogen, 136*t*

estrogen receptor assays, 304

ESWL (extracorporeal shock wave lithotripsy), 287

ETTs (exercise tolerance tests), 313

E-US (endoscopic ultrasonography), 226, 304

eustachian tube, 279, 332

Ewing sarcoma, 332

exacerbation, definition of, 145

excision procedures, 99*t*

excisional biopsies, 298

exercise tolerance tests (ETTs), 313

exocrine glands, 19, 46

exophthalmic goiter, 234

exophthalmometry, 234, 305

exophthalmos, 234

exploratory laparotomy, 12, 12*f*

external oblique, 254*f*–255*f*

extracorporeal shock wave lithotripsy (ESWL), 287

eye doctors

- ophthalmologists, 13, 13*f*
- opticians, 181

optometrists, 181

eyes/vision

anatomy of, 278

cataracts and, 280

conjunctivitis and, 280

exophthalmic goiter and, 234

exophthalmometry and, 234, 305

fluorescein angiography and, 281, 305

glaucoma and, 280

ophthalmic professionals for, 345

ophthalmologists for, 13, 13f, 177t

ophthalmology for, 16t, 176

ophthalmoscopes and, 13, 13f

ophthalmoscopy for, 281, 309

retinopathies of, 93t

scotomas and, 194, 194f

slit-lamp microscopy and, 281, 313

stye of, 281

visual acuity, 281

F

facial nerve paralysis, 331

fainting, 264

fallopian tubes, 17f, 238f, 239, 332

salpingitis and, 239

family practitioners, 177t

fasting blood sugar (glucose) tests, 234, 306

fatty tissue, cancer of, 92t

feces, 227

fellowship training, 176

female reproductive system

abbreviations for, 241

anatomy of, 238, 238f

definition and role of, 49

diagnostic procedures and laboratory tests for, 240

pathology of, 239

terminology of, 239

treatment procedures for, 240

femur, 192, 253f

fetuses, 238f

fibrillation, 217

fibroids, uterine, 91, 92*f*, 119, 186, 186*f*, 239–240
fibrosarcomas, 92*t*
fibrous tissue, cancer of, 92*t*
fibula, 192, 192*f*, 253*f*
finger bones (phalanges), 141*f*, 253*f*
fingers
 RA and, 183*f*
 webbed, 134*f*
fixation, of fractures, 192
fluids, collection of, 52*s*
fluorescein angiography, 281, 305
fluoroscopy, 305
flutter, 217
Foley catheters, 300, 332
follicle-stimulating hormone (FSH), 136*t*
food bolus, 63*f*
food tube, esophagus
forceps, 17*f*
fractures
 Colles, 331
 of fibula, 192, 192*f*
 fixation of, 192
frontal (coronal) plane, 56–57, 57*f*, 84
 MRIs of, 58*f*
frozen section technique, 305
FSH (follicle-stimulating hormone), 136*t*
fungal tests, 281, 298

G

gallbladder (GB), 8*f*, 224*f*, 227
 location of, 99*f*
 stones, treatment of, 106
 ultrasound, 305
gallium scans, 305
ganglion, 10*t*
gangrene, 93
gastrectomy, 15, 99*t*, 189
 subtotal, 146
gastric, definition of, 15
gastric (peptic) ulcers, 189, 189*f*
gastritis, 90*t*

gastrocnemius, 254f–255f

gastroenteritis, 15

gastroenterologists, 177t

gastroenterology, 16t

- case report for, 189s

gastroesophageal reflux disease (GERD), 226–227

gastrointestinal (GI), 227

gastrointestinal endoscopy, 226

gastrosopes, 17

gastroscopy, 10, 189, 226, 305

GB, gallbladder

GERD (gastroesophageal reflux disease), 226–227

geriatricians, 177t

GFR (glomerular filtration rate), 287

GH (growth hormone), 136t, 234

GI (gastrointestinal), 227

Giardia, 332

glands, excision of, 99t

glaucoma, 280

glial cells, 264

glioblastoma, 264

glomerular filtration rate (GFR), 287

glucometer, 21–22

glucose (fasting blood sugar) tests, 234, 305

glucose tolerance tests (GTTs), 234, 306

gluteus maximus, 255f

gluteus medius, 254f

glycosuria, 286

goiter, 234

gonorrhea, 249, 333

gouty arthritis (gout), 257

gracilis, 254f–255f

Graves disease (hyperthyroidism), 15, 16f, 138f, 234

GreenLight PVP (photoselective vaporization of prostate), 250

groin (inguinal) lymph nodes, 180

growth hormone (GH), 136t, 234

GTTs (glucose tolerance tests), 234, 306

gynecologists, 177t, 214

gynecology (GYN), 11, 11s, 16t, 241

- case report for, 186s

H

HAART (highly active antiretroviral therapy), 246

hair

alopecia and, 280

fibers, 277

follicles, 277

roots, 277

hallucinations, 14

halves of body, 57

hands

RA and, 183*f*

x-ray of, 141*f*

HbA1c (hemoglobin A1c), 234

HCG (human chorionic gonadotropin), 240, 307

Hct (hematocrit), 306

HD, hemodialysis

HDL (high-density lipoprotein), 218–219, 301

head, 6, 137*f*

head, eyes, ears, nose, throat (HEENT), 281

headaches, migraine, 194

health information administrators (HIAs), 342

health information technicians (HITs), 342

heart, 51*f*, 84, 216*f*, 269*f*

cardiomyopathy compared to myocardial infarction of, 93*s*

congestive heart failure, 217, 219

ischemia of, 88, 88*f*

occlusions of, 88*f*

transplantation, 219

tricuspid and mitral valves of, 147, 148*f*

heart attack (myocardial infarction), 88*f*, 93*s*, 94, 128, 217, 219

prevention of, 184

HEENT (head, eyes, ears, nose, throat), 281

hematemesis, 189

hematocrit (Hct), 306

hematologists, 177*t*, 214

hematology, 16*t*

hematomas, 11

epidural and subdural, 137*f*

hematuria, 94, 188, 286

hemigastrectomy, 137

hemiplegia, 137, 174, 264

Hemocult tests, 227, 306

hemodialysis (HD), 101, 128, 287
arteriovenous fistula for, 193, 193*f*

hemoglobin, 11, 15

hemoglobin A1c (HbA1c), 234

hemoglobin assays, 306

hemolytic anemia, 132*t*

hemoptysis, 271

hemothorax, 271

hepatitis, 11, 90*t*, 226

hepatocellular carcinoma, 15, 226

hepatomas, 15, 92*t*

hepatopathy, 93*t*

herniated intervertebral disc, 258

herpes genitalis, 249

HIAs (health information administrators), 342

high blood pressure, [hypertension](#)

high-density lipoprotein (HDL), 218–219, 301

highly active antiretroviral therapy (HAART), 246

hilum, 190

hip bone, 182*f*

HIT (health information technician), 342

HIV (human immunodeficiency virus), 245–246
viral load test for, 316

Hodgkin lymphoma, 187, 245–246, 332

Holter monitoring, 218, 306

home health aides, 343

hordeolum, 281

hormone replacement therapy (HRT), 241

hormones, 234
secretion of, 46, 232*f*
types of, 136*t*

Horner syndrome, 332

hospitalists, 177*t*

HRT (hormone replacement therapy), 241

human chorionic gonadotropin (HCG), 240, 306

human immunodeficiency virus (HIV), 245–246
viral load test for, 316

humerus, 253*f*

Huntington disease, 332

hydrocele, 249

hyperbilirubinemia, 226
hyperglycemia, 19, 138, 233
hyperplasia, 138, 139f
hypertension (high blood pressure), 138, 184, 193, 217, 219
hyperthyroidism (Graves disease), 15, 16f, 138f, 234
hypertrophy, 138, 139f
hypoglycemia, 19, 21, 139
hypothalamus, 234
hysterectomy, 96, 98f, 186, 240
hysterosalpingography, 240, 306
hysteroscopy, 136t, 306

I

iatrogenic, definition of, 180
IBD (inflammatory bowel disease), 179s, 226–227
IBS (irritable bowel syndrome), 226–227
ICD (implantable cardioverter-defibrillator), 219
ileostomy, 227
ileum, 8f, 224f
 stomas of, 104f
ilium, 253f
IM (intramuscular), 258
immunoassays, 306
immunoglobulin tests, 307
immunoglobulins, 246
immunohistochemistry, 307
implantable cardioverter-defibrillator (ICD), 219
in vitro fertilization (IVF), 241
incisional biopsies, 298
infarct, 217
infarction, 94, myocardial infarction
infections
 blood, 88
 chlamydial, 249
 nosocomial, 181
 sexually transmitted, 241, 249
 urinary tract, 135
infectious disease specialists, 177t
inferior, definition of, 60t
inflammation/inflammatory conditions, 89, 90t
 Crohn disease, 179s, 195–196, 226, 331

gouty arthritis, 257
inflammatory bowel disease, 179s, 226–227
of meninges, 264
PID, 239, 241
RA, 183s, 183f, 257
sarcoidosis, 245
inflammatory bowel disease (IBD), 179s, 226–227
inguinal lymph nodes, 244f
inguinal (groin) lymph nodes, 180
insulin, 19s, 21–22, 136t, 138–139, 233
insulin pump, 21, 191, 191f
intensive care units, 141s
internal medicine, 176
internists, 176, 177t
intervenous urography, 315
intervertebral disks, 139
intra-abdominal catheter, 287
intra-abdominal injuries, 192
intracoronary artery stents, 102f
intramural masses, 92f
intramuscular (IM), 258
intrauterine, 139
intravenous (IV), 139, 139f
intravenous pyelography (IVP), 315
intravenous urography, 315
iris, 278
iron deficiency anemia, 132t
irreversible dementia, 264
irritable bowel syndrome (IBS), 226–227
ischemia, 88, 88f, 93–94
 acute myocardial, 184
 definition of, 128
 Raynaud phenomenon and, 333
ischium, 253f
IV (intravenous), 139, 139f
IVF (in vitro fertilization), 241
IVP (intravenous pyelography), 315

J

jaundice, 226–227
jejunum, 8f, 224f

joints

- arthroplasty of, [258](#)
- degenerative disorders of, [13](#), [13f](#)
- hip, [145f](#)
- knee, [13](#), [13f](#), [18f](#), [145f](#), [149](#)
- RA and, [183s](#), [183f](#)
- subluxation of, [183f](#)

K

- K⁺ (potassium), [234](#)
- Kaposi sarcoma, [333](#)
- keyhole surgery, [227](#)
- kidneys, [14](#), [52f](#)
 - anatomy of, [285f](#)
 - dialysis procedures for, [101](#), [101f](#), [128](#), [287](#)
 - failure of, [286](#)
 - nephrostomy and, [180](#), [180f](#)
 - transplantation of, [287](#)
 - Wilms tumor of, [334](#)
- kidneys, ureters, bladder (KUB) x-rays, [286–287](#), [307](#)
- knee joint
 - arthroscopy of, [18f](#)
 - osteoarthritis of, [13](#), [13f](#)
 - total replacement of, [145f](#), [149](#)
- KUB (kidneys, ureters, bladder) x-rays, [286–287](#), [307](#)

L

- laminectomy, [99t](#), [258](#)
- laparoscopic appendectomy, [227](#)
- laparoscopic cholecystectomy, [98](#), [99f](#), [106](#), [128](#), [227](#)
- laparoscopic oophorectomy, [98f](#), [128](#)
- laparoscopic surgery, [227](#)
- laparoscopy, [12](#), [12f](#), [17](#), [102](#), [136t](#), [307](#)
 - definition of, [46](#), [227](#)
 - for tubal ligation, [17f](#)
- laparotomy, [12](#), [12f](#), [46](#)
- large intestine, [8f](#), [9](#), [52f](#)
- laryngectomy, [105f](#)
- laryngoscopy, [103f](#), [136t](#), [271](#), [307](#)
- larynx, [51f](#), [269f](#)
 - cartilage of, [64f](#)

- definition of, 84
- location of, 61
- lateral, definition of, 60*t*
- lateral (sagittal) plane, 57, 57*f*, 84
 - MRIs of, 58*f*
- latissimus dorsi, 254*f*–255*f*
- LDL (low-density lipoprotein), 218–219, 301
- left atrium, 216*f*
- left ventricle, 216*f*
- leg prosthesis, 144, 144*f*
- leiomyomas, 92*f*, 186, 186*f*, 239
- leiomyosarcoma, 92*t*
- lens, 278
- leukemia, 15, 46, 88
 - diagnosis case study for, 38
 - leukocytosis compared to, 93*s*
- leukocytes, 9*f*, 12, 15
- leukocytosis, 16, 46
 - leukemia compared to, 93*s*
- levator scapulae, 254*f*
- LFTs (liver function tests), 227, alanine transaminase, alkaline phosphatase tests, aspartate transaminase tests, bilirubin
- licensed practical nurses (LPNs), 343
- lipid tests, 218, 307
- lipoprotein tests, 218, cholesterol tests
- liposarcoma, 92*t*
- lithotripsy, 188, 188*f*, 287
- liver, 8*f*, 11, 52*f*, 224*f*
 - bile production of, 99*f*, 106
 - cirrhosis of, 226
 - diseases of, 93*t*
 - hepatitis of, 11, 90*t*, 226
 - malignant tumor of, 92*t*
- liver function tests (LFTs), 227, alanine transaminase, alkaline phosphatase tests, aspartate transaminase tests, bilirubin
- lobectomy, 272
- low-density lipoprotein (LDL), 218–219, 301
- lower gastrointestinal examination, 307
- LPN (licensed practical nurse), 343
- lumbar nerves, 263*f*
- lumbar puncture (spinal tap), 62, 62*f*, 265, 307

- lumbar spine, 54, 84
- lumbar vertebra, 253f, 258
- lung capillaries, 216f
- lungs, 8f, 51f, 269f
 - blood travel to, 148f
 - cancer of, 190
 - collapsed, 271
 - diagnosis of cancer in, case study, 77
 - removal of, 272
 - x-ray of pneumonia compared to normal, 89f
- lunula, 277
- lymph, 48
- lymph nodes, 84, 180, 238f
 - anatomy of, 244f
 - diseases of, 93t
 - malignant tumor of, 92t, 331
- lymph vessels, 244f
- lymphadenopathy, 93t, 180, 187
- lymphatic system
 - abbreviations for, 246
 - anatomy of, 244, 244f
 - definition and role of, 48
 - diagnostic procedures and laboratory tests for, 245
 - pathology of, 245
 - terminology of, 245
 - treatment procedures for, 246
- lymphocytes, 9f, 48, 62, 245
- lymphoma, 92t
 - Burkitt, 331
 - definition of, 245
 - Hodgkin, 187, 245–246
 - non-Hodgkin, 246

M

- MAC (*Mycobacterium avium* complex), 246
- magnetic resonance angiography (MRA), 308
- magnetic resonance imaging (MRI), 58, 58f–59f, 218
 - abdominal, 226
 - definition of, 308
 - description of procedure, 65–66
 - for endocrine system, 234

- for nervous system, 265
- for respiratory system, 271
- of upper body, 187*f*
- male reproductive system
 - abbreviations for, 250
 - anatomy of, 248, 248*f*
 - definition and role of, 49
 - diagnostic procedures and laboratory tests for, 249
 - pathology of, 249
 - terminology of, 249
 - treatment procedures for, 250
- malignant tumors, benign compared to, 140*s*, cancer/malignant tumors
- mammary papilla, 238*f*
- mammography, 100, 100*f*, 240, 308
- Marfan syndrome, 333
- masseter, 255*f*
- MDI (metered-dose inhaler), 272
- M.E, [medical examiner](#)
- medial, definition of, 60*t*
- medial malleolus, 253*f*
- mediastinal lymph nodes, 180, 244*f*
- mediastinal structures, 190
- mediastinoscopy, 136*t*, 308
- mediastinum, 51, 51*f*, 53, 84
- medical assistants, 343
- medical examiner (M.E.), 14*s*
- medical intensive care unit (MICU), 141*s*
- medical laboratory technologists, 343
- medical specialists, 176–179
 - areas of practice for, 177*t*
 - case reports for, 184
 - combining forms and vocabulary for, 179–184
 - residency training for, 176
- medical/surgical intensive care unit (MSICU), 141*s*
- medications, reference guide for top 50 prescribed, 336*t*–337*t*
- medulla oblongata, 263*f*
- melanocytes, 277
- melanoma, 92*t*, 281
- Ménière disease, 333
- meninges, 84, 90*f*, 137*f*
 - inflammation of, 264

meningitis, 89, 264
menorrhagia, 94, 94s, 186, 239
menorrhea, 94s
menstruation, 94, 239
mesothelioma, 92t
metacarpal bones, 140, 141f, 253f
metastasis, 140, 140f, 174
metatarsals, 253f
metered-dose inhaler (MDI), 272
MI, [myocardial infarction](#)
microscopic discectomy, 258
MICU (medical intensive care unit), 141s
middle ear, bones of, 279
midsagittal plane, 57
migraines, 194
milk glands, 238f
minimally invasive surgery, 227
mitral valve, 147, 148f
mitral valve prolapse syndrome, 147t, 174
molds, 134
mole, 281
monocytes, 9f, 245
mononucleosis, 245
mouth, 224f
MRA (magnetic resonance angiography), 308
MS (multiple sclerosis), 264–265
MSICU (medical/surgical intensive care unit), 141s
mucus, hypersecretion of, 89
MUGA (multiple-gated acquisition) scans, 218, 308
multiple myeloma, 91, 92t, 246
multiple myomas, 92f
multiple sclerosis (MS), 264–265
multiple-gated acquisition (MUGA) scans, 218, 309
muscle biopsies, 257, 308
muscles
 anterior superficial, 254f
 atrophy of, 132, 138, 139f, 183f
 biopsy of, 257
 diseases of, 93t
 posterior superficial, 255f
muscular dystrophy, 257, 332

musculoskeletal system

- abbreviations for, 258
- anatomy of, 253–254, 253f–255f
- anterior superficial muscles of, 254f
- definition and role of, 49
- diagnostic procedures and laboratory tests for, 257
- pathology of, 257
- posterior superficial muscles of, 255f
- terminology of, 256
- treatment procedures for, 258

Mycobacterium avium complex (MAC), 246

myelin sheath, 264

myelography/myelograms, 99, 128, 265, 308

myeloma

- definition of, 128
- multiple, 91, 92t, 246

myocardial infarction (heart attack), 88f, 93s, 94, 128, 217, 219

- prevention of, 184

myomas, 91, 92f, 128, 240

myomectomy, 99t, 240

myopathy, 93t

myosarcomas, 91, 128

myositis, 90t

N

Na⁺ (sodium), 234

nail plates, 277

nails, 277

nasogastric intubation, 308

nausea, 194

neck (cervical) lymph nodes, 180, 244f

necrosis, 93

necrotic tissue, 217

needle biopsies, 187, 298

Neisseria gonorrhoeae, 333

neonatal intensive care unit (NICU), 141, 142f

neonates, 141, 142f

- Apgar score and, 331
- PKU tests and, 310

nephrectomy, 12

nephritis, 90t

nephrolithiasis, 286
nephrologists, 177*t*, 214
nephrology, 15
 case report for, 193*s*
nephrosis, 16
nephrostomy, 180, 180*f*
nerve endings, 277
nerves
 diseases of, 93*t*
 Horner syndrome of, 332
 spinal, 84
nervous system
 abbreviations for, 265
 anatomy of, 263, 263*f*
 central, 263*f*, 265
 definition and role of, 49
 diagnostic procedures and laboratory tests for, 265
 pathology of, 264
 peripheral, 263*f*
 terminology of, 264
 treatment procedures for, 265
neural, 15
neurologists, 15, 177*t*, 214
neurology, 12, 16*t*
 case report for, 194*s*
neuropathy, 93*t*
neurosurgeons, 177*t*, 214
neurotomy, 17
neutrophil, 9*f*
nevus, 281
NICU (neonatal intensive care unit), 141, 142*f*
nitroglycerin, 184
non-Hodgkin lymphoma, 246
nonsteroidal anti-inflammatory drugs (NSAIDs), 258
nose, 269*f*
nosocomial infections, 181
nothing by mouth (NPO), 227
NSAIDs (nonsteroidal anti-inflammatory drugs), 258
nuclear medicine technologists, 344
nurse anesthetists, 344
nursing aides, 344

nutritionists, [342](#)

O

O₂ (oxygen), [272](#)

obstetricians, [177t](#), [214](#)

obstetrics (OB), [11s](#), [241](#)

occlusions (blockages), heart muscle, [88f](#)

occult blood tests, [Hemocult tests](#)

occupational therapist assistants (OTAs), [345](#)

occupational therapists (OTs), [345](#)

oncogenic viruses, [181](#)

oncologists, [12](#), [177t](#), [214](#)

oncology, [16t](#)

 case report for, [187s](#)

oophorectomy, laparoscopic, [98f](#), [128](#)

ophthalmic professionals, [345](#)

ophthalmologists, [13](#), [13f](#), [177t](#)

ophthalmology, [16t](#), [176](#)

ophthalmoscopes, [13](#), [13f](#)

ophthalmoscopy, [281](#), [308](#)

optic nerve, [278](#)

opticians, [181](#)

optometrists, [181](#)

orbicularis oculi, [254f–255f](#)

orbicularis oris, [254f](#)

orchiopexy, [250](#)

organs, [48](#), [48f](#)

orthodontists, [181](#)

orthopedics, case report for, [192s](#)

orthopedists, [177t](#), [181](#), [214](#)

osteoarthritis, [13](#), [13f](#), [183s](#)

osteogenic sarcoma, [92t](#)

osteomyelitis, [90t](#)

osteopathy, [93t](#)

osteoporosis, [233](#), [257](#)

osteosarcomas, [46](#)

OTAs (occupational therapist assistants), [345](#)

otitis, [90t](#)

otolaryngologists, [177t](#), [214](#)

otoscopy, [281](#), [309](#)

OTs (occupational therapists), [345](#)

ovaries, 232f, 238f, 239

hormones of, 136t

ovum, 10t, 238f

oxygen (O₂), 272

P

PA (pulmonary artery), 190

PACU (post anesthesia care unit), 141s

Paget disease, 333

palpation, 309

pancreas, 8f, 19s, 224f, 232f

hormones of, 136t

location of, 99f

Whipple procedure for, 334

pap smear, 240, 309

pap tests, 333

paracentesis (abdominocentesis), 309

paralysis

definition of, 142, 174

facial nerve, 331

hemiplegia, 137, 174, 264

paraplegia, 142, 174, 264

quadriplegia, 145, 174

paraplegia, 142, 174, 264

parathyroid glands, 136t, 142, 143f, 232f

parathyroid hormone (PTH), 136t

Parkinson disease, 333

paronychium, 277

PAs (physician assistants), 346

patella, 253f

pathologists, 14, 14s, 177t, 214

pathology, 16t, 176

PCI (percutaneous coronary intervention), 219

PCP (*Pneumocystis pneumonia*), 246

PCR (polymerase chain reaction) tests, 309

PE (pulmonary embolism), 272

pectoralis major, 254f

pediatric or psychiatric care unit (PICU), 141s

pediatricians, 177t

pediatrics, 176

pedodontists, 181s

pedunculated growths, [92f](#)

PEEP (positive end-expiratory pressure), [272](#)

pelvic cavity, [52–53](#)

pelvic exams, [309](#)

pelvic inflammatory disease (PID), [239](#), [241](#)

pelvic ultrasonography, [240](#)

pelvis, [52–53](#), [253f](#)

- injuries to, [192](#)

penicillin, [134](#)

penis, [248f](#)

peptic (gastric) ulcers, [189](#), [189f](#)

percussion, [309](#)

percutaneous coronary intervention (PCI), [219](#)

percutaneous transhepatic cholangiography, [226](#)

pericardium, [19](#), [84](#)

periodontists, [181s](#)

peripheral nervous system, [263f](#)

peritoneal cavity, [52f](#)

peritoneal dialysis, [101](#), [101f](#), [128](#)

peritoneal fluid, [62](#), [63f](#)

peritoneum, [52–53](#), [52f](#), [84](#), [239](#)

peritonitis, [90t](#)

pernicious anemia, [132t](#)

peroneus longus, [254f](#)

PERRLA (pupils equal, round, reactive to light and accommodation), [281](#)

PET (positron emission tomography) scans, [218](#), [311](#)

PFTs (pulmonary function tests), [271–272](#), [312](#)

phalanges (finger bones), [141f](#), [253f](#)

pharmacy technicians, [345](#)

pharyngeal, definition of, [63](#)

pharyngitis, [90t](#)

pharynx (throat), [143f](#), [224f](#), [269f](#)

- anatomy and physiology of, [63f](#)
- definition of, [84](#)

phenylalanine, [310](#)

phenylketonuria (PKU) tests, [310](#)

phlebotomists, [346](#)

phlebotomy, [105f](#), [309](#)

photoselective vaporization of prostate (GreenLight PVP), [250](#)

physiatrists, [177t](#), [214](#)

physical therapists (PTs), [346](#)

physical therapy (PT), 258

physical therapy assistants (PTAs), 346

physician assistant (PA), 346

PICU (pediatric or psychiatric care unit), 141s

PID (pelvic inflammatory disease), 239, 241

pigmented cells in skin, malignant tumor of, 92t

pineal gland, 232f

pituitary gland, 46, 50f, 232f, 234

- hormones of, 136t

PKU (phenylketonuria) tests, 310

planes of body, 56–58, 56f

- combining forms for, 59–64

platelet count, 310

platelets, 9f, 14

platysma, 254f

pleura, 51, 51f, 53, 62, 84, 269f

pleural cavity, 51, 51f

pleural cells, malignant tumor of, 92t

pleural effusion, 52s, 272, 314

- drainage of, 96f

pleural membranes, 271

pleural space, 269f

plural formations, 10t

pneumoconiosis, 271

Pneumocystis pneumonia (PCP), 246

pneumonectomy, 99t, 272

pneumonia, 89, 89f, 271

polydipsia, 143, 191

polymerase chain reaction (PCR) tests, 310

polyps, 143, 226

polyuria, 143s, 191

pons, 263f

positive end-expiratory pressure (PEEP), 272

positron emission tomography (PET) scans, 218, 310

- for nervous system, 265

post anesthesia care unit (PACU), 141s

posterior, definition of, 56–57, 60t

posteroanterior chest x-rays, 190, 190f

potassium (K⁺), 234

potassium tests, 310

precancerous lesions, 143

prefixes

- combining forms and, 130–131
- definition of, 4–5
- list of common, 18–20
- suffixes and, 130–131
- terminology and, 132–147

pregnancy

- amniocentesis and, 97*f*, 240, 297
- ectopic, 135*f*, 239
- tests, 240, 310

prescribed medications, reference guide for top 50, 336*t*–337*t*

primary malignant tumors, 174

procedural suffixes, 96–105

proctosigmoidoscopy, 310

progesterone, 136*t*

progesterone receptor assays, 310

prognosis, definition of, 10, 17, 46

prolapse, uterine, 144, 144*f*

prone, definition of, 60*t*

prostate gland, 7*f*, 248*f*

- excision of, 99*t*
- photoselective vaporization of, 250
- transurethral resection of, 20*s*, 20*f*, 147

prostatectomy, 99*t*

prostate-specific antigen (PSA), 249, 310

prostatic carcinoma, 249

prosthesis, 144, 144*f*, 258

prosthodontists, 181*s*

protein electrophoresis, serum protein electrophoresis

prothrombin time, 311

proximal, definition of, 60*t*

PSA (prostate-specific antigen), 249, 311

psychiatrists, 177*t*, 214

psychiatry, 176

psychology, 16*t*

psychosis, 10*t*

PT (physical therapy), 258

PTAs (physical therapy assistants), 346

PTH, parathyroid hormone

PTs (physical therapists), 346

pubis, 253*f*

pulmonary angiography, 271, 311
pulmonary artery (PA), 190
pulmonary circulation, 216f
pulmonary edema, 217
pulmonary embolism (PE), 272
pulmonary function tests (PFTs), 271–272, 311
pulmonary perfusion scans, 311
pulmonary ventilation scans, 311
pulmonologists, 177t, 214
pupils, 278
pupils equal, round, reactive to light and accommodation (PERRLA), 281
pyelography, urography

Q

quadriceps femoris, 254f
quadriplegia, 145, 174

R

RA (rheumatoid arthritis), 183s, 183f
radiation iodine uptake (RAIU), 234, 314
radiation oncologists, 177t, 214
radiation therapists, 347
radiation therapy (radiotherapy), 103s, 182, 182f, 187, 246
radioactive iodine uptake, 234
radiographers, 347
radiography, x-ray films
 definition of, 64
radiologic technologists, 347
radiologists, 177t, 214
radiology, 103s, 176
 case report for, 190s–191s
radiotherapy (radiation therapy), 103s, 182, 182f, 187, 246
radius, 253f
RAIU (radiation iodine uptake), 234, 314
range of motion (ROM), 258
Raynaud phenomenon, 333
rectocele, 182, 182f
rectum, 7f, 52f, 182f, 224f, 248f
rectus abdominis, 254f
red blood cell count, 311
red blood cells (erythrocytes), 9, 9f, 46

registered nurses (RNs), 347

relapse, 145, 174

remission, 145, 174

renal, definition of, 14

renal calculi, 188, 188*f*

renal failure, 286

renal pelvis, 285*f*

renal transplantation, 287

research skills, 176

resections, 20, 99*t*

residency training, for medical specialists, 176

respiratory system

- abbreviations for, 272
- anatomy of, 269, 269*f*
- definition and role of, 49
- diagnostic procedures and laboratory tests for, 271
- pathology of, 271
- terminology of, 270
- treatment procedures for, 272

respiratory therapists, 348

retina, 13*f*, 93*t*, 278

retinopathy, 93*t*

retrogastric, 20

retrograde pyelogram (RP), 286–287, 315

retroperitoneal area, 52*f*, 146

Reye syndrome, 333

rhabdomyosarcoma, 92*t*

rheumatoid arthritis (RA), 183*s*, 183*f*, 257

rheumatoid factor assays, 311

rheumatologists, 177*t*, 214

rheumatology, 16*t*, 183

rhinitis, 14

rhomboideus major, 255*f*

ribs, 253*f*

right atrium, 216*f*

right ventricle, 216*f*

Rinne tests, 333

RNs (registered nurses), 347

ROM (range of motion), 258

roots of words, 2–4

- definition of, 2

suffixes containing, 18s

Rorschach test, 334

RP (retrograde pyelogram), 286–287, 315

S

sacral nerves, 263f

sacral spine, 54, 84

sacrum, 253f

sagittal (lateral) plane, 57, 57f, 84

MRIs of, 58f

salivary glands, 46

Salmonella, 334

salpingectomy, 98f

salpingitis, 239

sarcoidosis, 245

sarcomas, 14, 46, 64s, 92t

Ewing, 332

Kaposi, 333

sartorius, 254f

scalenes, 254f

scapula (shoulder bone), 146f, 253f

sclera, 278

scotomas, 194, 194f

scrotum, 248f

sebaceous glands, 277

seizures, 264

semen, 7

semen analysis, 249, 311

seminomas, 249

sense organ system, 49

abbreviations for, 281

anatomy of, 277–279

diagnostic procedures and laboratory tests for, 281

pathology of, 280–281

terminology of, 280

sensitivity tests, 302

septicemia (sepsis), 88, 88s

sequential multiple analysis (SMA), 299

serum enzyme tests, *cardiac enzyme tests*

serum protein electrophoresis (electrophoresis), 311

serum tests, 234

Sestamibi scans, 311

sexually transmitted diseases (STDs), 241

sexually transmitted infections (STIs), 241, 249

Shigella, 334

shock, 217

shortness of breath (SOB), 272

shoulder bone (scapula), 146f, 253f

sickle cell anemia, 132t

SICU (surgical intensive care unit), 141s

sigmoid colon, 224f

sigmoidoscopy, 136t, 226, proctosigmoidoscopy

Sjögren syndrome, 334

skeletal muscles, cancer of, 92t

skin, 49

- abbreviations for, 281
- anatomy of, 277–279
- biopsies, 281, 312
- dermis, 277
- diagnostic procedures and laboratory tests for, 281
- epidermis, 137, 277
- melanoma and, 281
- nevus of, 281
- pathology of, 280–281
- pigmented cells in, malignant tumor of, 92t
- terminology of, 280

skin lesions, removal of, 103

skin tests, 312

skull, cranial cavity, 51

sleep apnea, 132

slit-lamp microscopy, 281, 312

SMA (sequential multiple analysis), 299

small bowel follow-through, barium tests; upper gastrointestinal examination

small intestine, 8f, 9, 52f

Snellen test, 334

SOB (shortness of breath), 272

sodium (Na⁺), 234

sodium level tests, 312

soft tissue, swelling of, 183f

soleus, 254f–255f

sonography, ultrasonography

spasm, coronary artery, 184, 184f

speculum, vaginal, 17f

speech-language pathologists, 348

sperm, 7, 248f

spinal cavity, 52–53, 54f

spinal column, 52, 54

- divisions of, 54, 55f, 84

spinal cord, 52, 84

- anatomy of, 263f
- myelograms for, 99, 128
- surrounding anatomy and structures of, 90f

spinal nerves, 263f

spinal tap (lumbar puncture), 62, 62f, 265, 308

spirometers, 271

spleen, 8f, 99f, 244f

- excision of, 99t

splenectomy, 99t, 128

sputum tests, 271, 312

Staphylococcus aureus, 164

STDs (sexually transmitted diseases), 241

stents, arterial, 102, 102f, 184, 219

stereotactic breast biopsies, 308

stereotactic radiosurgery, 265

sternocleidomastoid, 254f–255f

sternum, 253f

STIs (sexually transmitted infections), 241, 249

stomach, 8f, 10, 52f, 224f

- excision of, 99t
- subtotal gastrectomy of, 146

stomas, 103, 104f

stool culture, 227, 312

stool guaiac tests, Hemoccult tests

stress tests, 218, 312

stroke (cerebrovascular accident), 6, 6s, 95, 128, 264

stye, 281

subcutaneous tissue, 277

subdural hematomas, 137f

subhepatic, 20

subluxation, of joints, 183f

subserosal masses, 92f

subtotal gastrectomy, 146

subtotal hysterectomy, 96

suffixes, [2–4](#)
 adjective, [94–95](#)
 combining forms and, [86–87](#)
 commonly confused, [135s](#)
 definition of, [2](#)
 diagnostic, [87–95](#)
 forming plural, [10t](#)
 list of common, [15–17](#)
 prefixes and, [130–131](#)
 procedural, [96–105](#)
 roots of words in, [18s](#)
 terminology and, [87–105](#)
superficial, definition of, [60t](#)
superior, definition of, [60t](#)
supine, definition of, [60t](#)
surfactant, [142f](#)
surgery, [176](#)
surgical intensive care unit (SICU), [141s](#)
surgical technologists (CSTs), [348](#)
swallowing process, [63f](#)
sweat glands, [46](#), [277](#)
symbols, comprehensive list of, [330](#)
symptoms, remission and relapse of, [145](#), [174](#)
syncope, [264](#)
syndromes, [146](#), [147t](#), [174](#)
syphilis, [249](#)
systemic circulation, [216f](#)
systems, [body systems](#)

T

T3 (triiodothyronine), [234](#), [314](#)
T4 (thyroxine), [136t](#), [234](#), [314](#)
T&A, [tonsillectomy and adenoidectomy](#)
TAH, [total abdominal hysterectomy](#)
TAH-BSO (total abdominal hysterectomy with bilateral salpingo-oophorectomy), [241](#)
tarsals, [253f](#)
Tay-Sachs disease, [334](#)
tear glands, [46](#)
technetium Tc 99m sestamibi scans, [218](#), [312](#)
teeth, dental specialists for, [181s](#)
tenaculum, [17f](#)

tendons, atrophy of, [183f](#)

TENS (transcutaneous electrical nerve stimulation), [265](#)

testes, [232f](#), [248f](#)

- cryptorchism of, [249](#)
- hormones of, [136t](#)
- orchiopexy and, [250](#)

testicular carcinoma, [249](#)

testosterone, [136t](#)

thallium-201 scans, [218](#), [312](#)

thoracentesis, [96](#), [96f](#), [272](#), [313](#)

thoracic cavity, [51](#), [51f](#), [53](#)

thoracic nerves, [263f](#)

thoracic spine, [54](#), [84](#)

thoracic surgeons, [177t](#), [214](#)

thoracic vertebra, [253f](#), [258](#)

thoracoscopy, [313](#)

thoracotomy, [272](#)

throat, [pharynx](#)

thrombocytes, [9f](#), [14](#)

thrombolytic therapy, [219](#)

thrombophlebitis, [90t](#)

thrombosis, [14](#)

thrombus, [14](#)

thymoma, [92t](#)

thymus gland, [244f](#)

- malignant tumor of, [92t](#)

thyroid function tests, [234](#), [313](#)

thyroid gland, [46](#), [143f](#), [232f](#)

- hormones of, [136t](#)
- location of, [138f](#)

thyroid scans, [234](#), [313](#)

thyroid-stimulating hormone (TSH), [136t](#), [234](#), [314](#)

thyroxine (T4), [136t](#), [234](#), [314](#)

TIA (transient ischemic attack), [265](#)

tibia, [253f](#)

tibialis anterior, [254f](#)

tinnitus, [281](#)

tissue capillaries, [216f](#)

tissue plasminogen activator (tPA), [219](#)

tissues, [48](#), [48f](#)

TKR (total knee joint replacement), [145f](#), [149](#)

toes, webbed, [134f](#)

tomography/tomograms, [313](#)

tomosynthesis, [100](#), [100f](#)

tonsillectomy, [96](#), [97f](#)

tonsillectomy and adenoidectomy (T&A), [97f](#)

tonsils, [97f](#), [269f](#)

total abdominal hysterectomy (TAH), [98f](#)

total abdominal hysterectomy with bilateral salpingo-oophorectomy (TAH-BSO), [241](#)

total hip joint replacement, [145f](#)

total hysterectomy, [96](#), [98f](#)

total knee joint replacement (TKR), [145f](#), [149](#)

total parenteral nutrition (TPN), [227](#)

Tourette syndrome, [334](#)

toxic shock syndrome (TSS), [147t](#), [164](#)

tPA (tissue plasminogen activator), [219](#)

TPN (total parenteral nutrition), [227](#)

trachea, [8f](#), [51f](#), [63f](#), [143f](#), [269f](#)

- cartilage of, [64f](#)
- definition of, [84](#)

tracheostomy, [105f](#), [272](#)

tracheotomy, [64f](#)

transcutaneous electrical nerve stimulation (TENS), [265](#)

transdermal, [20](#)

transient ischemic attack (TIA), [265](#)

transurethral, [20](#)

transurethral resection of prostate gland (TURP), [20s](#), [20f](#), [147](#), [250](#)

transverse (axial) plane, [57](#), [57f](#), [84](#)

- MRIs of, [58f](#)

trapezius, [254f–255f](#)

triceps brachii, [254f–255f](#)

tricuspid valve, [147](#), [148f](#)

triglycerides tests, [313](#)

triiodothyronine (T3), [234](#), [314](#)

troponin tests, [313](#)

TSH (thyroid-stimulating hormone), [136t](#), [234](#), [314](#)

TSS, [toxic shock syndrome](#)

tubal ligation, [17f](#), [240](#)

tuberculin tests, [271](#), [314](#)

tuberculosis, [271](#)

tumors, benign, [91](#), [92f](#), [128](#), [140s](#), [cancer/malignant tumors](#)

tuning fork tests, [281](#), [313](#), [333–334](#)

TURP, [transurethral resection of prostate gland](#)

U

UA (urinalysis), [133s](#), [287](#), [315](#)

ulcerative colitis, [179s](#), [226](#)

ulcers, peptic, [189](#), [189f](#)

ulna, [253f](#)

ultrasonography, [186](#), [186f](#)

 abdominal, [226](#)

 definition of, [314](#)

 Doppler, [218](#), [303](#)

 endoscopic, [226](#), [304](#)

 fetal, [148f](#)

 gallbladder, [306](#)

 pelvic, [240](#)

underarm (axilla), [238f](#)

unilateral frontal cephalgia, [194](#)

upper gastrointestinal examination, [314](#)

upper respiratory infection (URI), [272](#)

urea, [94s](#), [287](#)

uremia, [94s](#), [128](#), [286](#)

ureters, [7f](#), [188](#), [285f](#)

urethra, [7f](#), [52f](#), [248f](#), [285f](#)

URI (upper respiratory infection), [272](#)

uric acid, [287](#)

uric acid tests, [257](#), [314](#)

urinalysis (UA), [133s](#), [287](#), [314](#)

urinary bladder, [7](#), [7f](#), [52f](#), [133f](#), [182f](#), [248f](#), [285f](#)

urinary catheterization, [287](#)

urinary system

 abbreviations for, [287](#)

 anatomy of female, [285](#), [285f](#)

 definition and role of, [49](#)

 diagnostic procedures and laboratory tests for, [286–287](#)

 pathology of, [286](#)

 terminology of, [286](#)

 treatment procedures for, [287](#)

urinary tract, female, [7](#), [7f](#)

urinary tract, male, [7](#), [7f](#)

urinary tract infection (UTI), [135](#), [287](#)

urine

- blood in, [94s](#)
- diuretics and, [143s](#)
- polyuria and, [143s](#)
- urine tests, [234](#)
- urography, [287](#), [314](#)
- urologists, [177t](#), [214](#)
- urology, [16t](#)
 - case report for, [188s](#)
- uterine artery embolization, [240](#)
- uterine prolapse, [144](#), [144f](#)
- uterus, [7f](#), [52f](#), [60](#), [61f](#), [238f](#)
 - fibroids in, [91](#), [92f](#), [119](#), [186](#), [186f](#), [239–240](#)
 - hysterectomy and, [96](#), [98f](#), [186](#), [240](#)
- UTI (urinary tract infection), [135](#), [287](#)

V

- VA (visual acuity), [281](#)
- vagina, [7f](#), [52f](#), [182f](#), [238f](#)
- vaginal speculum, [17f](#)
- varicocele, [249](#)
- varix/varices, [10t](#)
- vas deferens, [248f](#)
- vasectomy, [250](#)
- vasoconstrictors, [194](#)
- VATS (video-assisted thoracic surgery), [272](#), [314](#)
- VCUG (voiding cystourethrogram), [287](#), [302](#), [316](#)
- veins, [216f](#)
- venae cavae, [84](#)
- venography, [297](#), [315](#)
- ventilation-perfusion scans (VQs), [271–272](#), [315](#)
- ventricular arrhythmias, [184](#)
- venules, [216f](#)
- vertebra(e), [10t](#), [54](#), [54f](#)
- vertebroplasty, [258](#)
- VF (visual field), [281](#)
- video-assisted thoracic surgery (VATS), [272](#), [314](#)
- viral load test, for HIV, [315](#)
- virtual colonoscopy, [227](#)
- visceral muscle, cancer of, [92t](#)
- vision, [eyes/vision](#)
- visual acuity (VA), [281](#)

visual field (VF), 281
vitreous humour, 278
vocabulary, for medical specialists, 179–184
voice box, larynx
voiding cystourethrogram (VCUG), 287, 302, 315
von Willebrand disease, 334
VQs (ventilation-perfusion scans), 271–272, 316

W

WBC count, white blood cell count
webbed fingers and toes, 134f
Weber tuning fork test, 334
Western blot tests, 245, 315
Whipple procedure, 334
white blood cell (WBC) count, 93s, 315
Wilms tumor, 334
windpipe, trachea
word analysis, 2–5

X

xiphoid process, 253f
x-ray films (radiography), 64
 angiography, 100
 cerebral angiography, 265
 chest, 57, 57f, 190, 190f, 271, 301
 coronary angiography, 184, 184f
 of hand, 141f
 hysterosalpingography, 240
 KUB, 286–287, 307
 mammography, 100, 100f, 240
 myelograms, 99, 128, 265, 309
 of normal lungs and pneumonia, 89f
 posteroanterior chest, 190, 190f
 of renal calculi, 188, 188f
 for urinary system, 286–287